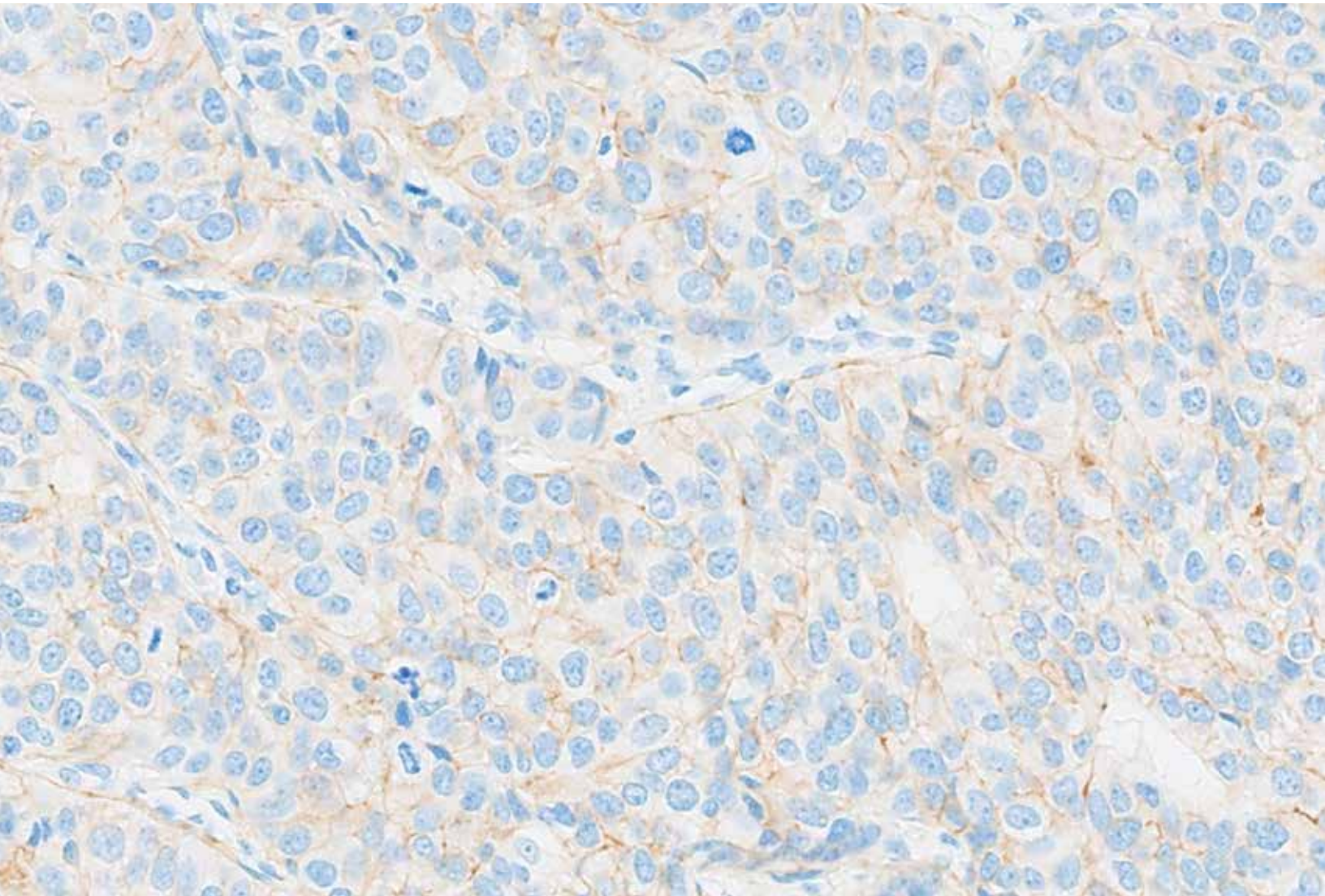


# **PATHWAY anti-HER-2/neu (4B5) Rabbit Monoclonal Primary Antibody Interpretation Guide for Breast Cancer**





# Table of Contents

|   |           |
|---|-----------|
| <b>Introduction</b>   | <b>1</b>  |
| <hr/>   |           |
| <b>Intended Use</b>   | <b>3</b>  |
| <hr/>   |           |
| Intended Use of product   | 3         |
| Purpose of Interpretation Guide   | 3         |
| <hr/>   |           |
| <b>Clinical Evaluation</b>  | <b>4</b>  |
| <hr/>   |           |
| Staining Characteristics  | 4         |
| Scoring Algorithm   | 5         |
| Quality Controls  | 6         |
| Specimen Workflow   | 10        |
| <hr/>   |           |
| <b>Reference Images</b>   | <b>12</b> |
| <hr/>   |           |
| PATHWAY anti-HER-2/neu Rabbit Monoclonal Antibody Staining in Breast Cancer: IHC Score 0  | 12        |
| PATHWAY anti-HER-2/neu Rabbit Monoclonal Antibody Staining in Breast Cancer: IHC Score 1+ | 24        |
| PATHWAY anti-HER-2/neu Rabbit Monoclonal Antibody Staining in Breast Cancer: IHC Score 2+ | 34        |
| PATHWAY anti-HER-2/neu Rabbit Monoclonal Antibody Staining in Breast Cancer: IHC Score 3+ | 46        |
| Artifacts and Challenging Cases   | 58        |
| <hr/>   |           |
| <b>Impact of Pre-analytical Conditions on PATHWAY anti-HER-2/neu (4B5) Antibody</b>       | <b>79</b> |
| <hr/>   |           |
| <b>References</b>   | <b>80</b> |
| <hr/>   |           |



## Introduction

---

PATHWAY anti-HER-2/*neu* (4B5) Rabbit Monoclonal (the “HER2 (4B5) assay”) is directed against the internal domain of the c-erbB-2 oncoprotein (HER2). HER2 oncoprotein was cloned and characterized by Akiyama et al in 1986. It is an approximately 185-kDa transmembrane glycoprotein that is structurally similar to epidermal growth factor receptor (EGFR).<sup>1</sup>

Clone 4B5 has been shown to react with a 185 kDa protein from SK-BR-3 cell lysates via Western blotting. SK-BR-3 is a breast carcinoma cell line which has a 128-fold over expression of HER2 mRNA. The size of the band identified correlates well with that reported by Akiyama et al for HER2 protein (185 kDa).<sup>1</sup>



## Intended Use

---

### Intended Use of product

Refer to the corresponding PATHWAY anti-HER-2/*neu* Rabbit Monoclonal Primary Antibody method sheets for the intended use of this product including associated indications.

### Purpose of Interpretation Guide

This guide is intended to:

Provide pathologists with a tool to facilitate the clinical evaluation of formalin-fixed, paraffin-embedded (FFPE) breast cancer tissue sections stained with PATHWAY anti-HER-2/*neu* (4B5) Rabbit Monoclonal Antibody in accordance with the proposed product labeling.

Provide photographic images that illustrate the staining patterns that may result from staining of breast cancer tissues with the PATHWAY anti-HER-2/*neu* (4B5) Rabbit Monoclonal Antibody.

Provide example images of challenging cases to provide guidance in their evaluation.

Provide guidance in selecting and using a known weak HER2 positive breast cancer case to serve as a tissue control when stained with the PATHWAY anti-HER-2/*neu* (4B5) Rabbit Monoclonal Antibody.

## Clinical Evaluation

---

### Staining Characteristics

PATHWAY anti-HER-2/*neu* Rabbit Monoclonal Antibody staining in breast carcinoma can be membranous and/or cytoplasmic. The VENTANA automated immunostaining procedure causes a brown reaction product (DAB (3,3'-Diaminobenzidine) to precipitate at the antigen sites localized by PATHWAY anti-HER-2/*neu* Rabbit Monoclonal Antibody.

HER2 protein is expressed in the cell membrane of both normal and neoplastic human tissues. Using frozen tissue sections, and a labeled, HER2-directed antibody, Press et al. reported weak staining of normal epithelial cells in the gastrointestinal, respiratory, reproductive, and urinary tracts as well as in the skin, breast, and placenta.<sup>10</sup> Intense staining of the cell membrane was found only in the tumor cells of invasive breast carcinoma. They did not observe cytoplasmic staining in the absence of membrane staining.<sup>10</sup> Using a different HER2-directed antibody, Taylor et al. did observe cytoplasmic staining for HER2 protein but concluded that it was not associated with the presence of detectable HER2 mRNA in breast cancer.<sup>11</sup> If present, cytoplasmic only staining is not known to be clinically relevant.<sup>11</sup>

The HER2 protein is expressed at a level sufficient to produce strongly positive immunohistochemistry (IHC) staining in 15 to 30 percent of invasive ductal breast cancers; approximately 40% of invasive ductal breast cancers are negative for expression by IHC, and the remainder are HER2-low expression tumors.<sup>10</sup>

#### Staining pattern and intensity

The breast tissue section should be examined for the pattern and intensity of cell membrane staining with PATHWAY anti-HER-2/

*neu* Rabbit Monoclonal Antibody, including the completeness of this staining. If staining is completely absent, the case should be scored as IHC 0. Partial, incomplete membrane staining should be scored as IHC 0 or IHC 1+, depending on the percentage of tumor cells exhibiting this staining. Staining that completely encircles the cell membrane should be scored as IHC 2+ or IHC 3+. Examination of cases at 40x or higher magnification may be necessary to discriminate between scores of IHC 0 and IHC 1+. Cytoplasmic or nuclear staining should not be considered in the determination of percentage of tumor cells stained.

The HER2 signal may be distributed homogeneously, having a pattern and intensity throughout the tumor, or may be distributed heterogeneously, having more than one intensity level. In the event of heterogeneous staining, estimates of the relative percentages of cells exhibiting staining at the various signal intensities and pattern are visually estimated and used to generate a HER2 IHC score. CONFIRM Negative Control Rabbit Ig, an isotype-matched negative control, is used to evaluate the presence of background staining in test samples and establish a staining intensity baseline.

Non-specific background staining, if present, will have a diffuse appearance. Sporadic light staining of connective tissue may also be observed in tissue sections that are excessively formalin fixed. Intact cells should be used for interpretation of staining results, as necrotic or degenerated cells often stain non-specifically.



## Scoring Algorithm

### Evaluating PATHWAY anti-HER-2/neu (4B5) Rabbit Monoclonal Antibody staining in breast carcinoma tissue:

For PATHWAY anti-HER-2/neu Rabbit Monoclonal Antibody, each case is stained with the PATHWAY anti-HER-2/neu Rabbit Monoclonal Antibody and with CONFIRM Negative Control Rabbit Ig, a matched negative reagent control (NRC). Invasive breast cancer cells labeled with PATHWAY anti-HER-2/neu

Rabbit Monoclonal Antibody are evaluated for presence or absence of the DAB signal. The matched NRC-stained slide is used to assess non-specific background staining and the degree of background staining known to occur due to specific tissue elements (refer to case images below). Please note: *ultraView* Universal DAB Detection Kit is the only detection reagent kit that is recommended for use with PATHWAY anti-HER-2/neu Rabbit Monoclonal Antibody.

**Table 1: PATHWAY anti-HER-2/neu Rabbit Monoclonal Antibody Scoring Algorithm for Breast Cancer**

| HER2 (4B5) Score (Report to treating physician) | Staining Pattern  |
|---|---|
| 0 <sup>1</sup>                                  | No membrane staining is observed<br>Or,<br>Faint, partial staining of the membrane in 10% or less of the cancer cells |
| 1+ <sup>1</sup>                                 | Faint, partial staining of the membrane in greater than 10% of the cancer cells                                       |
| 2+ <sup>2</sup>                                 | Weak to moderate complete staining of the membrane in greater than 10% of the cancer cells                            |
| 3+  | Intense complete staining of the membrane in greater than 10% of the cancer cells                                     |

<sup>1</sup> Review at 40X to discern faint, partial staining is recommended

<sup>2</sup> Recommend reflex test to assess gene amplification per ASCO/CAP guidance

The scoring algorithm for PATHWAY anti-HER-2/neu Rabbit Monoclonal Antibody is provided in [Table 1](#).

Staining is scored only if it is localized to the cellular membrane. Even if cytoplasmic staining is present, it is not included in the determination of positivity. Staining that completely encircles the tumor cell membrane should be scored as IHC 2+ or IHC 3+. Partial staining of the membrane should be scored as IHC 0 or IHC 1+, depending on the percentage of tumor cells with

HER2 staining. It may be necessary to examine borderline cases at higher magnification to discriminate between scores of IHC 0, IHC 1+ and IHC 2+. In contrast to cases scored as IHC 3+, staining scored as IHC 2+ has a crisper and more clearly delineated ring, while cases scored as IHC 3+ exhibit a very thick outline.

Representative cases are discussed in the [Reference Images](#) section.

## Quality Controls

### Positive Tissue Control

A positive control tissue fixed and processed in the same manner as the patient specimens must be run for each set of test conditions and with every PATHWAY anti-HER2 (4B5) antibody staining procedure performed. This tissue could contain both positive staining cell/tissue components and negative cell/tissue components and serve as both the positive and negative control tissue. Control tissue should be fresh autopsy/biopsy/surgical specimens prepared and fixed as soon as possible in a manner identical to test sections. Such tissue may monitor all steps of the analysis, from tissue preparation through staining. Use of a tissue section fixed or processed differently from the test specimen provides control for all reagents and method steps except fixation and tissue preparation. A tissue with weak positive staining (IHC 2+) is more suitable than strong positive staining (IHC 3+) for optimal quality control and to detect minor levels of reagent degradation. Ideally a tissue which is known to have weak but positive staining should be chosen to ensure that the system is sensitive to small amounts of reagent degradation or problems with the IHC methodology. Generally, however, neoplastic tissue that is positive for HER2 is strongly positive due to the nature of the pathology (overexpression).

An example of a positive control for PATHWAY anti-HER2 (4B5) antibody is a known weak HER2 positive invasive breast

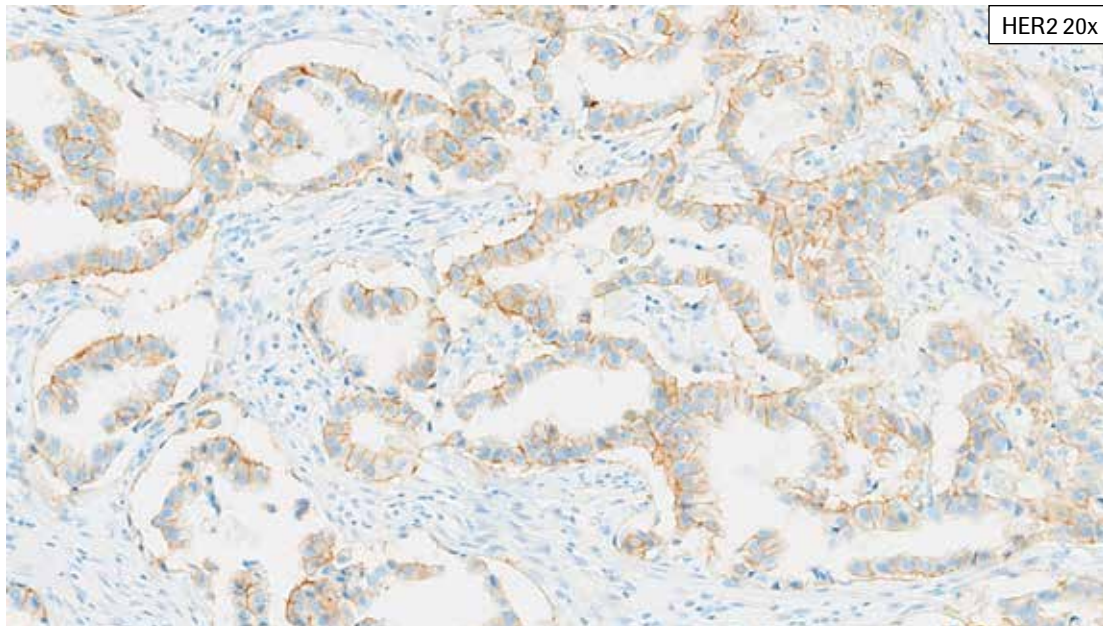
carcinoma (for example ductal or lobular). The positive staining tissue components (membrane of neoplastic cells) are used to confirm that the antibody was applied and the instrument functioned properly.

Known positive tissue controls should be utilized only for monitoring the correct performance of processed tissues and test reagents, and not as an aid in determining a specific diagnosis of patient samples.

### Negative Tissue Control

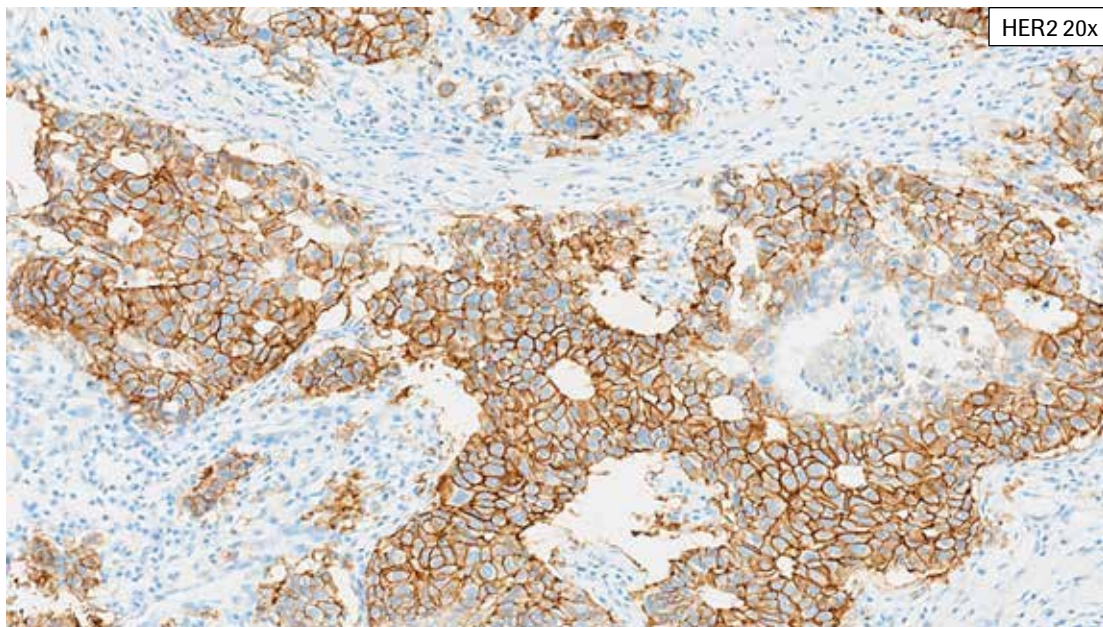
The same tissue used for the positive tissue control (ductal or lobular invasive breast carcinoma) may be used as the negative tissue control. The non-staining components (surrounding stroma, lymphoid cells and blood vessels) should demonstrate absence of specific staining and provide an indication of specific background staining with the primary antibody. Use a tissue known to be fixed, processed and embedded in a manner identical to the patient sample(s) with each staining run to verify the specificity of PATHWAY anti-HER2 (4B5) antibody for demonstration of HER2, and to provide an indication of specific background staining (false positive staining).

## Acceptable Staining of Control Breast Carcinoma



Acceptable positive tissue control: Invasive breast cancer with weak to moderate complete membrane staining (HER2 IHC Score 2+, weak positive). A qualified invasive breast cancer tissue with weak to moderate staining can detect issues that may occur on the staining run that may impact HER2 staining.

## Unacceptable Staining of Control Breast Carcinoma



Unacceptable positive tissue control: Invasive breast cancer with moderate to intense complete membrane staining (HER2 IHC Score 3+, positive). This case stains too strongly overall to detect any issues on the staining run that may impact HER2 staining.

## Quality Controls

### Cell Line Controls

PATHWAY HER-2 4 in 1 (“HER2 4 in 1 slide”) Control Slides consist of formalin-fixed, paraffin-embedded (FFPE) cultured human breast cancer cell lines.

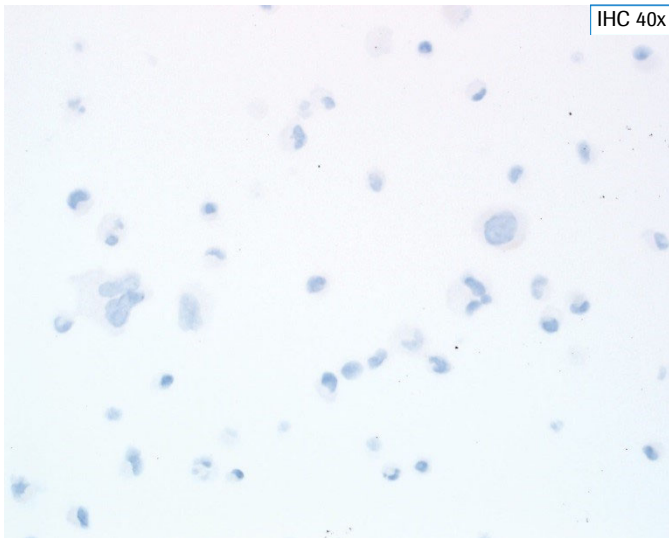
PATHWAY HER-2 4 in 1 Control Slides may be useful for a preliminary validation of the instrument used for staining slides with PATHWAY anti-HER2 (4B5) antibody. When processed and stained appropriately, the cell lines should stain as described in **Table 3**. If the indicated staining is not evident in the appropriate cores, especially the 1+ and 2+ controls, the staining of the tissues should be repeated.

**Table 3: Acceptance Criteria for Marker Staining in Control Tissue**

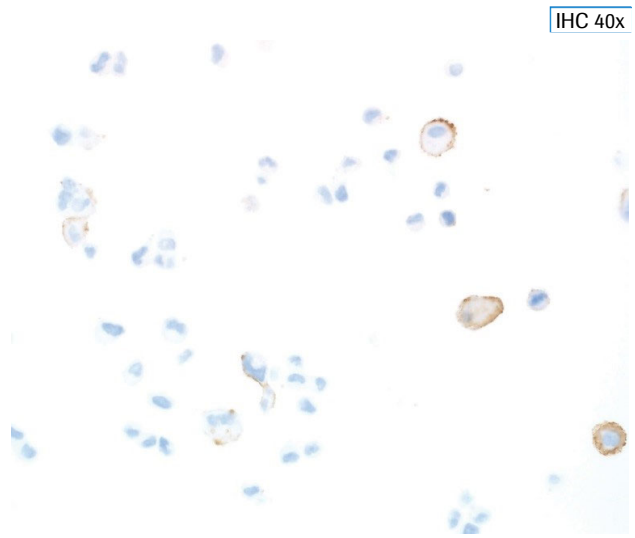
| HER2 IHC Score | Cell Line  | HER2/Chr17 Ratio* |
|----------------|------------|-------------------|
| 0              | MDA-MB-231 | 1.11              |
| 1+             | T-47D      | 1.12              |
| 2+             | MDA-MB-453 | 2.66              |
| 3+             | BT-474     | 5.53              |

\*HER2/Chr17 ratio is an average of three lots of PATHWAY HER-2 4 in 1 Control Slides determined using fluorescence in situ hybridization (FISH).

## Acceptable Staining of Control – HER2 4-in-1 Slides



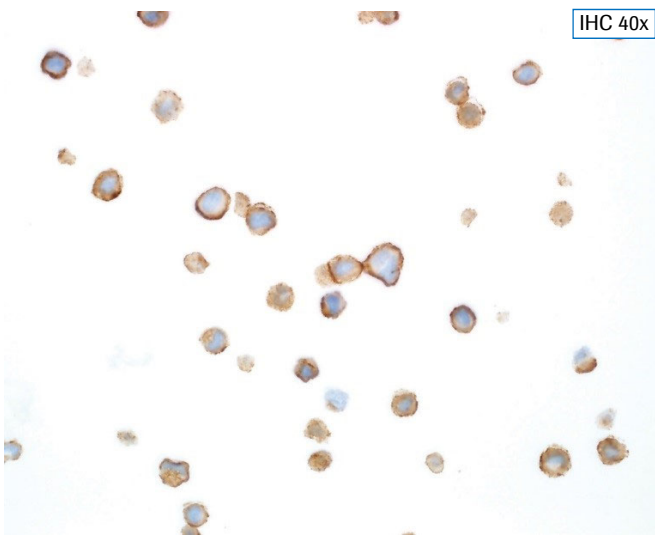
The level 0 cell line control (MDA-MB-231) is scored at an intensity level of 0 when processed appropriately. Scant membrane staining may be observed.



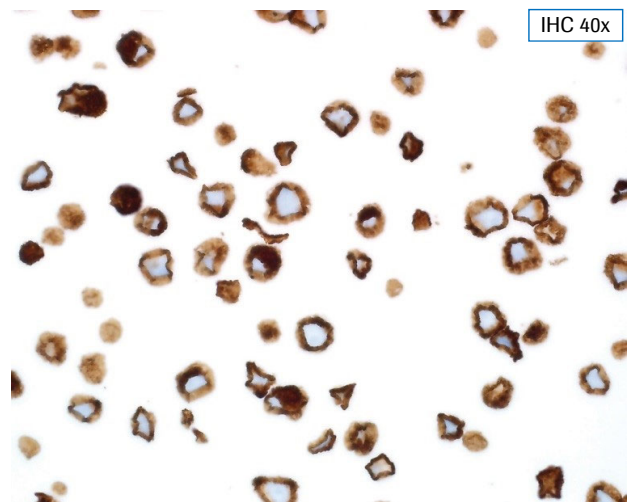
The level 1+ cell line control (T-47D) stains at an intensity level of 1+ with partial membrane pattern in > 10% of cells.

Note: because HER2 antigen is not uniformly present on the surface of these cells, not all cross sections will stain identically. When first evaluating this cell line, scan the entire cell field. It may also be necessary to examine it at higher magnification (40X) to pick up the 1+ staining in the scattered cells. When processed appropriately, > 10% of the cells will stain with 1+ intensity.

If the Level 1+ control does not stain appropriately, the staining run should be repeated.



The level 2+ cell line control (MDA-MB-453) stains at an intensity level of 2+ with complete “ring” pattern in > 10% of the cells. In contrast to 3+ cases, the staining scored as 2+ has a crisper and more clearly delineated ring, while cases scored as 3+ exhibit a very thick outline (compare to level 3+ cell line control).



The level 3+ cell line control (BT-474) is a high expression cell line that stains at an intensity level of 3+ with complete “ring” pattern in > 10% of the cells.

## Specimen Workflow

PATHWAY anti-HER-2/*neu* Rabbit Monoclonal Antibody requires three serial sections from each case: one section for hematoxylin and eosin (H&E) staining, a second section for CONFIRM Negative Control Rabbit Ig staining, and a third section for PATHWAY anti-HER-2/*neu* Rabbit Monoclonal Antibody staining. If the H&E slide evaluation indicates that the patient specimen is inadequate, then a new specimen should be obtained and stained with PATHWAY anti-HER-2/*neu* Rabbit Monoclonal Antibody.

**Positive Tissue Control:** The positive tissue control must demonstrate appropriate staining for the staining run to validated. A known weak HER-2/*neu* positive invasive breast carcinoma tissue (>10% weak to moderate complete staining, HER2 IHC Score 2+) will serve as a positive tissue system-level control for each staining run to validate all samples for the respective run. When processed and stained appropriately, the positive tissue control should stain commensurately with its known HER2 expression.

### Negative Reagent Control Slides

A matched NRC slide must be run for every specimen to evaluate non-specific staining and to aid in the interpretation of results. Before evaluating a slide stained with PATHWAY anti-HER-2/*neu* Rabbit Monoclonal Antibody (HER2 (4B5) slide), the pathologist must assess the case-matched NRC slide for the presence or absence of specific staining. The NRC slide must exhibit acceptable staining (i.e., must be negative for specific staining) in order for the corresponding HER2 (4B5) slide to be considered evaluable.

Non-specific staining, if present, will have a diffuse appearance. Sporadic light staining of connective tissue may also be observed in tissue sections that are excessively formalin fixed. Intact cells should be used for interpretation of staining results, as necrotic or degenerated cells often stain non-specifically.

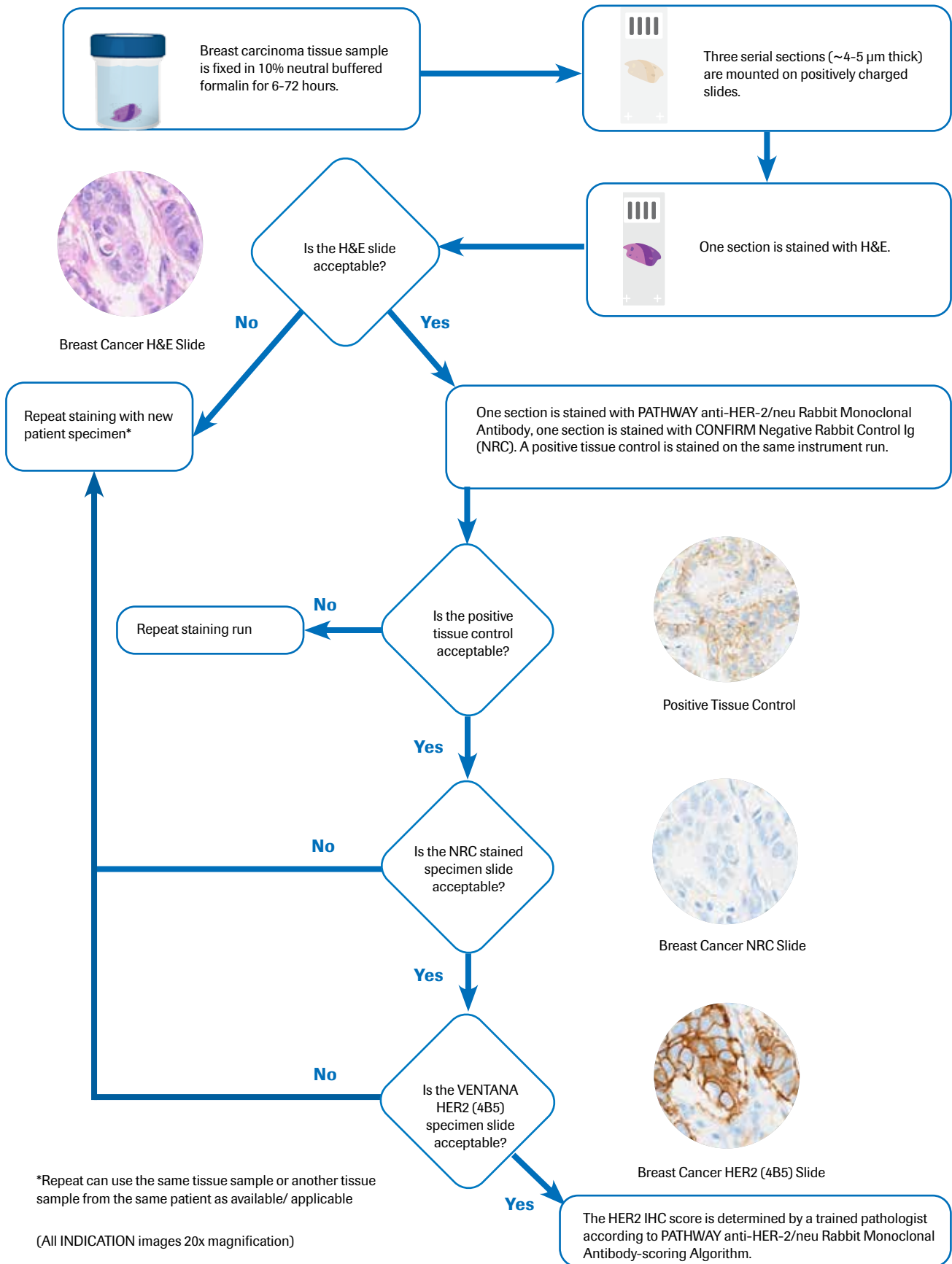
### HER2 (4B5)-Stained Slides

The tissue morphology and levels of background staining on each HER2 (4B5) slide should be judged as acceptable or unacceptable by a qualified pathologist. Background staining is defined as non-specific staining of the FFPE tissue (as opposed to specific staining of lesional cells in the FFPE tissue).

The pathologist should also review the HER2 (4B5) slide for the overall acceptability of staining. Possible reasons for unacceptable staining include staining artifacts, poor tissue quality, and tissue wash off. Slides with unacceptable staining performance should not be scored. Repeat testing should be done with back up slides or another patient specimen as available.

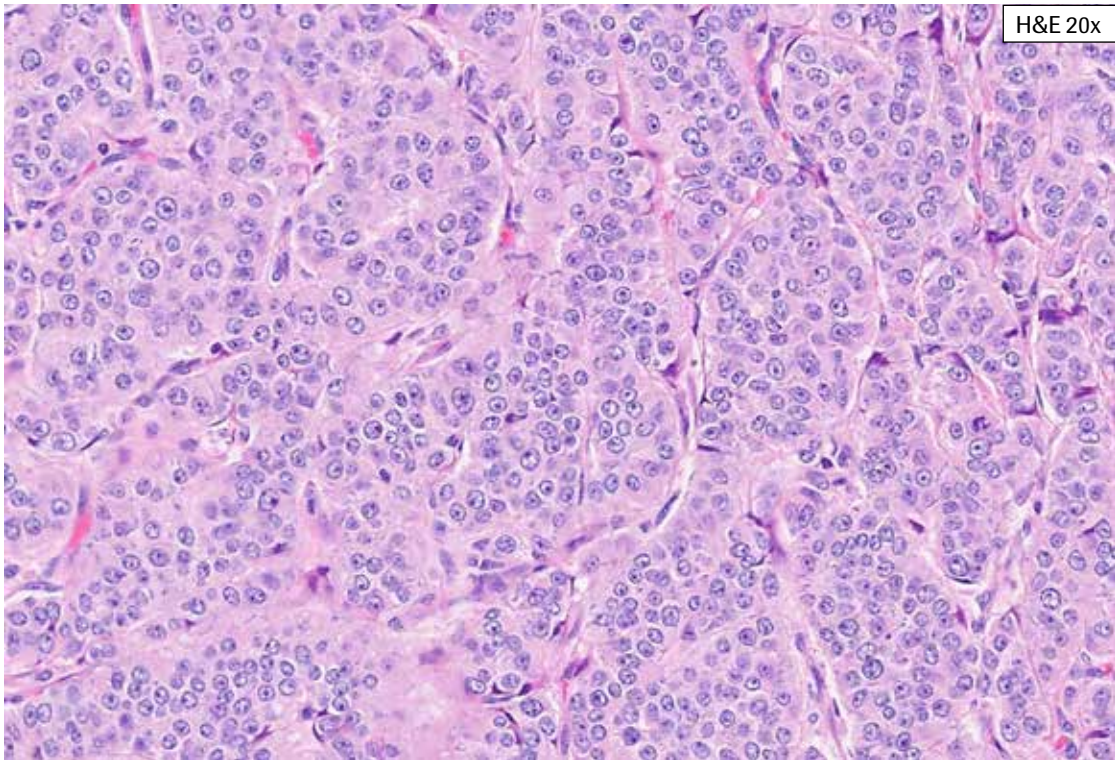
Each evaluable HER2 (4B5) slide should be assigned a HER2 IHC score (0, 1+, 2+, or 3+) according to the scoring algorithm defined in [Table 1](#). Intact cells should be used for interpretation of staining results, as necrotic or degenerated cells often stain non-specifically.

## Specimen Flow



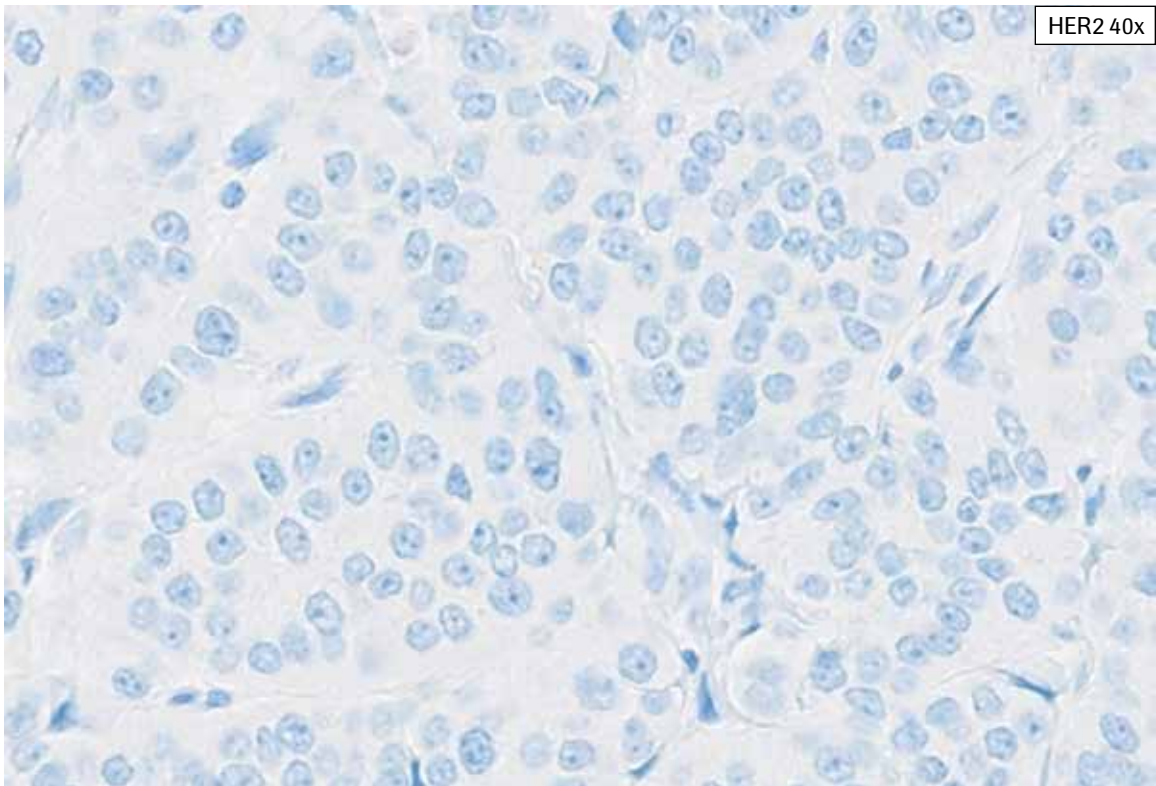
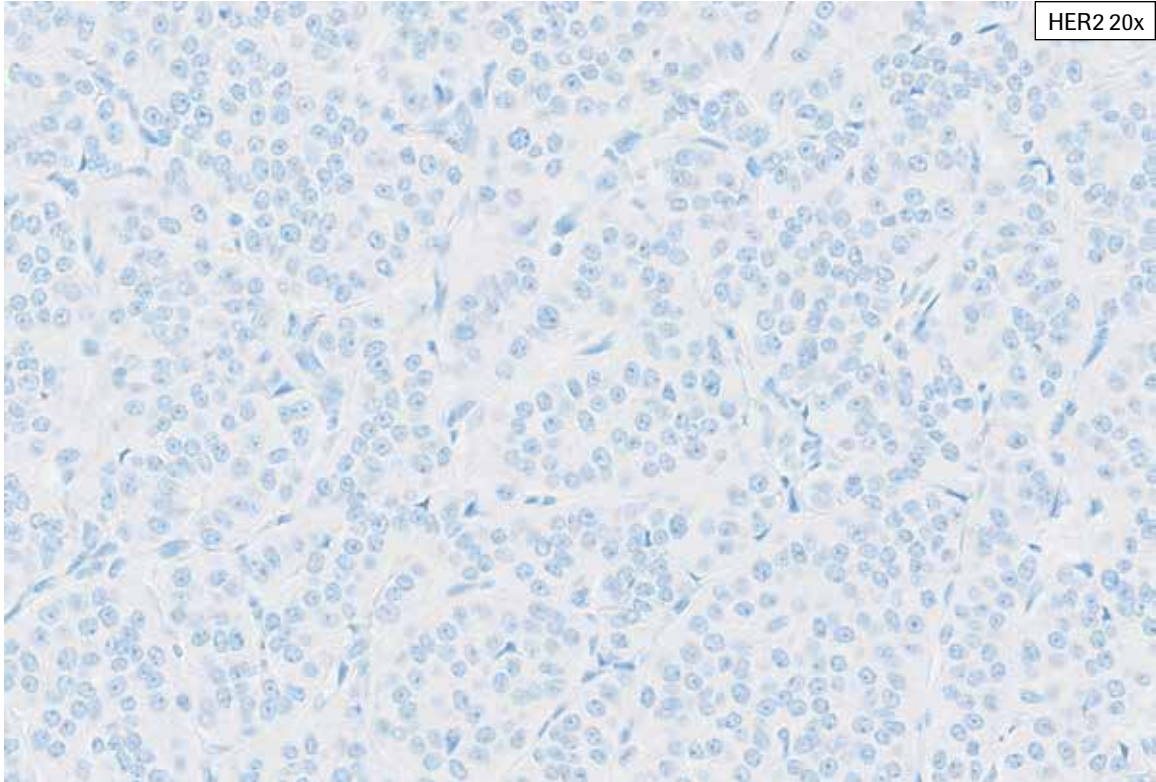
## Reference Images

PATHWAY anti-HER-2/neu Rabbit Monoclonal Antibody Staining in Breast Cancer:  
IHC Score 0

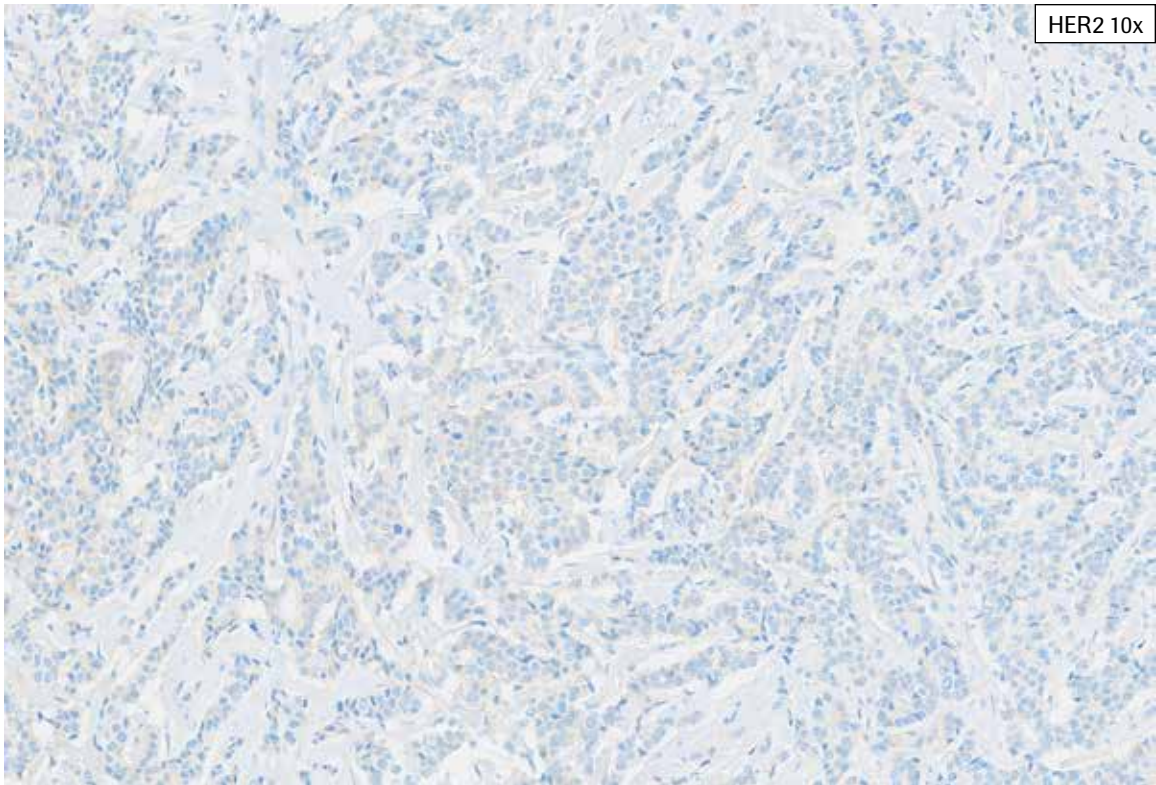
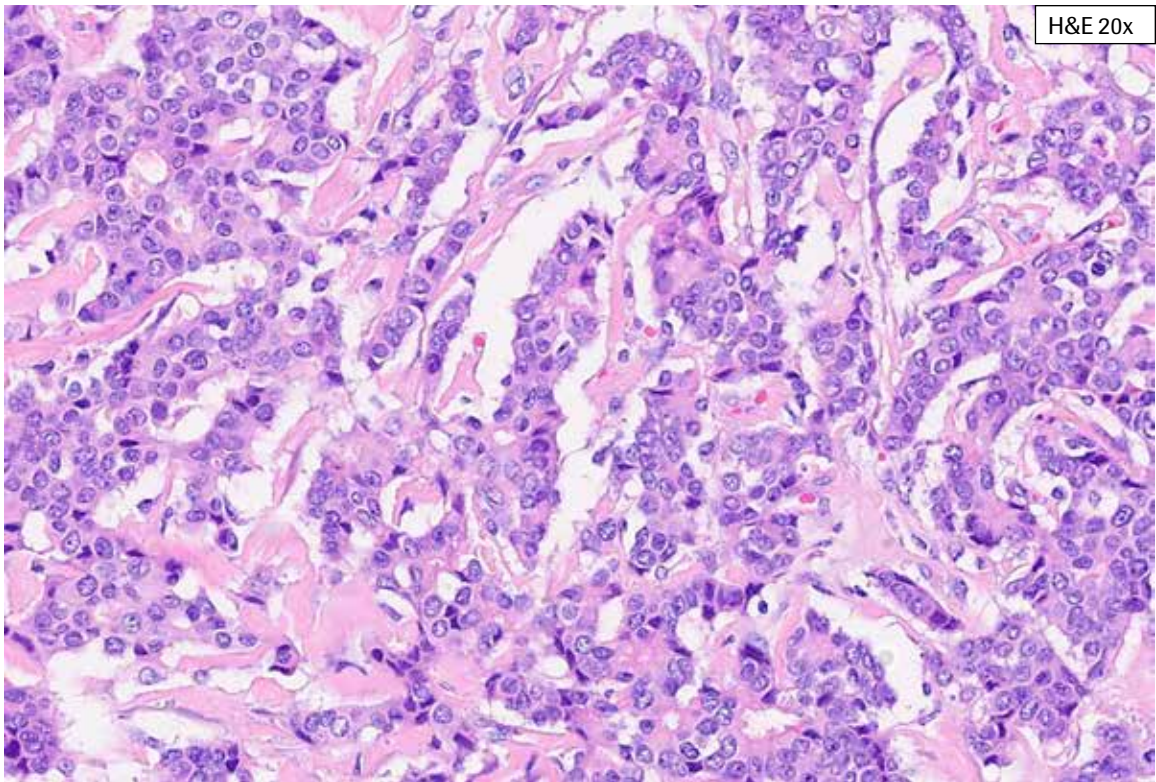


**HER2 IHC Score 0, Case 1:** This case shows abundant tumor exhibiting no membrane staining (HER2 IHC Score 0).

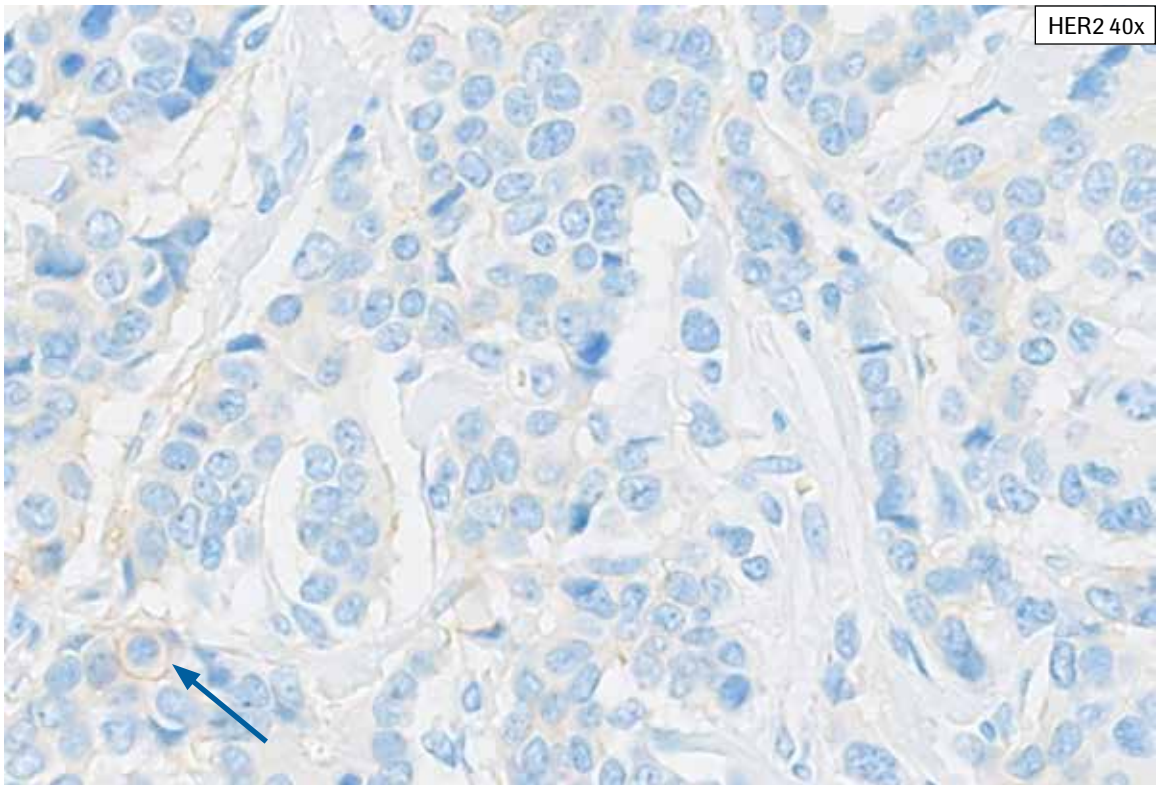
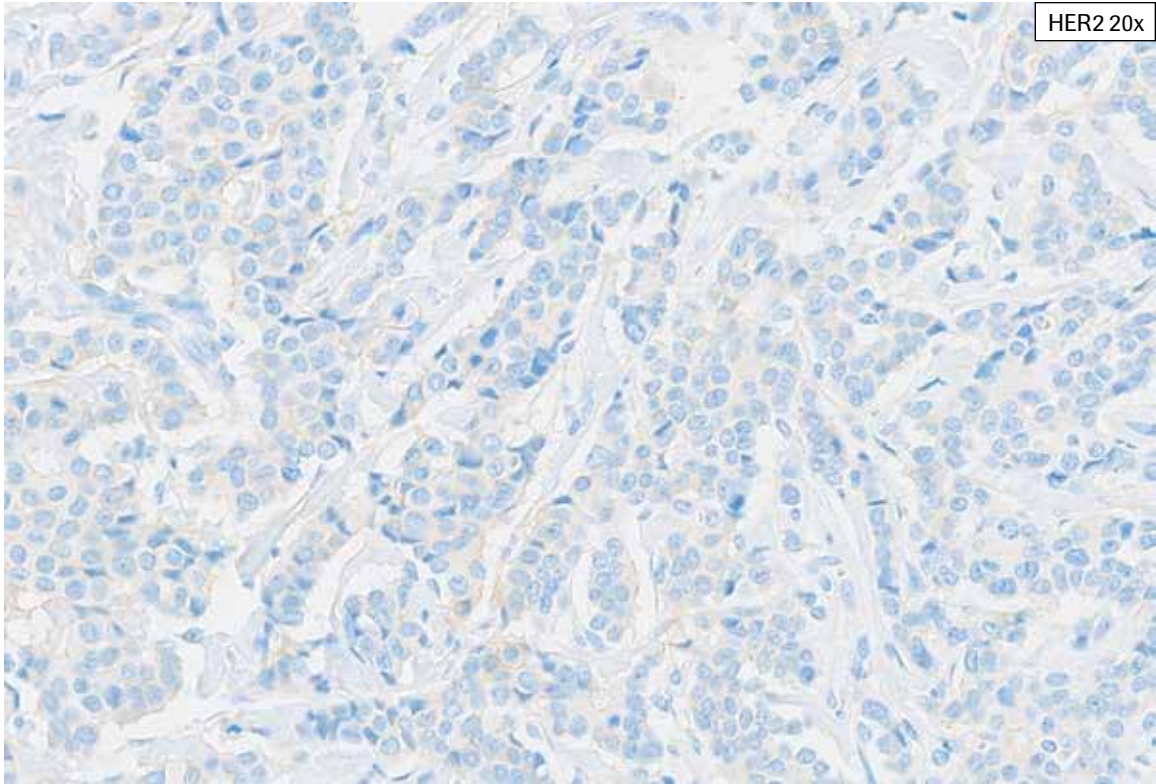




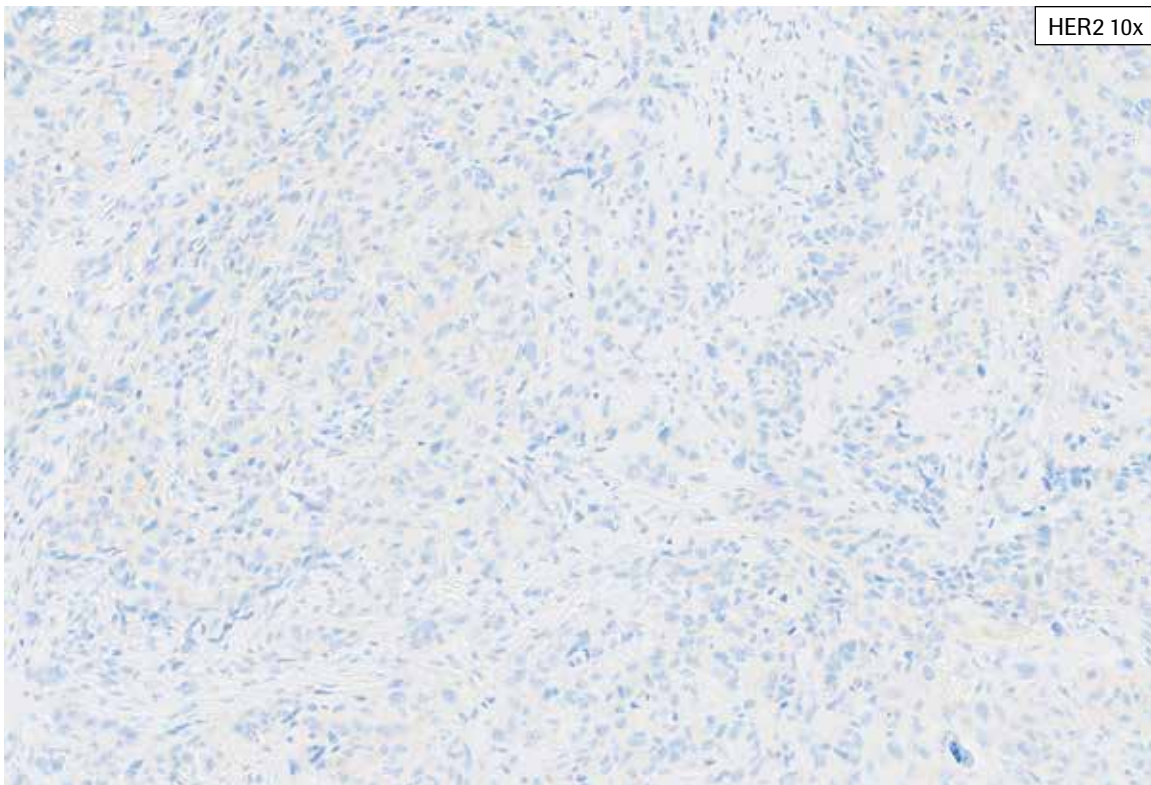
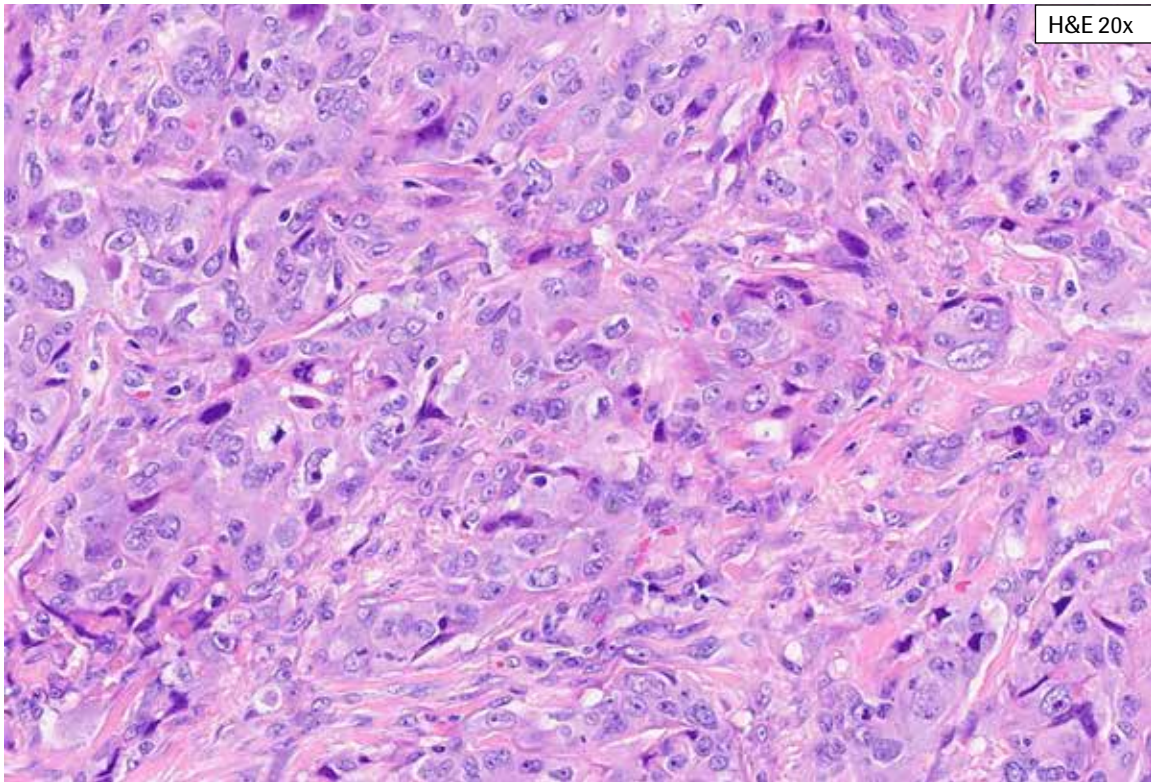
**HER2 IHC Score 0, Case 1:** This case shows abundant tumor exhibiting no membrane staining (HER2 IHC Score 0).



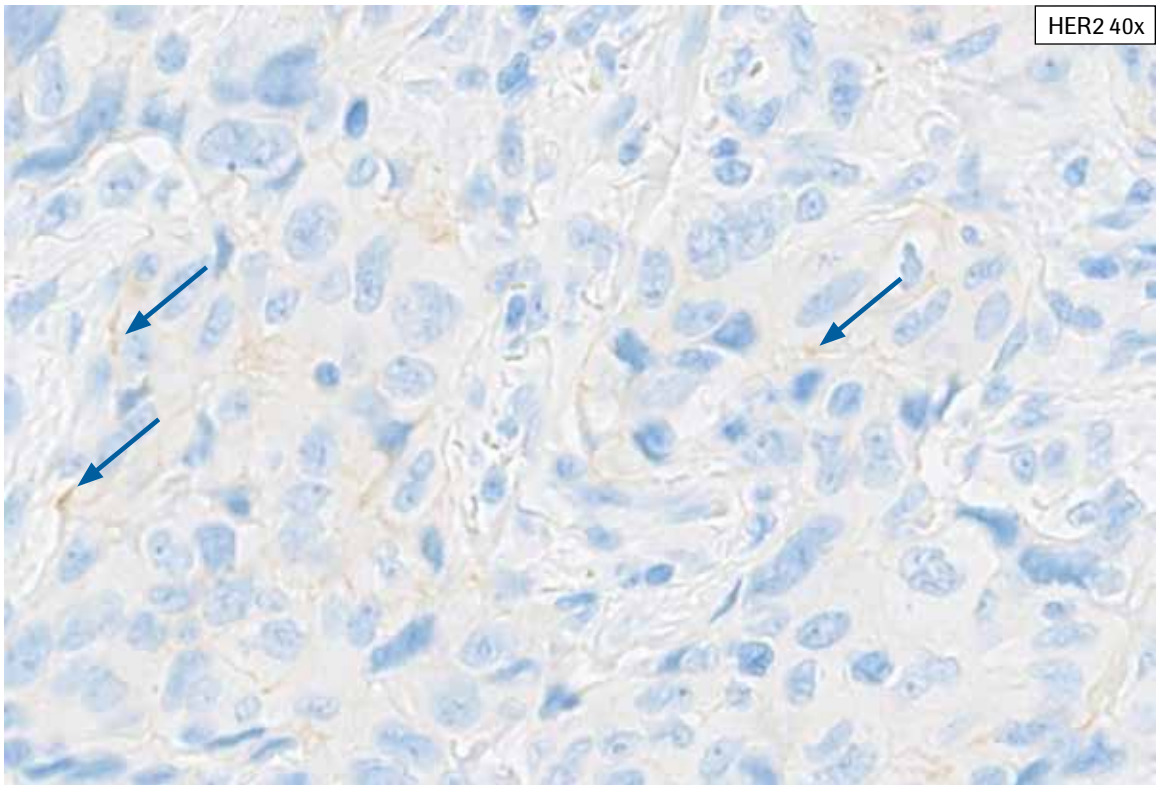
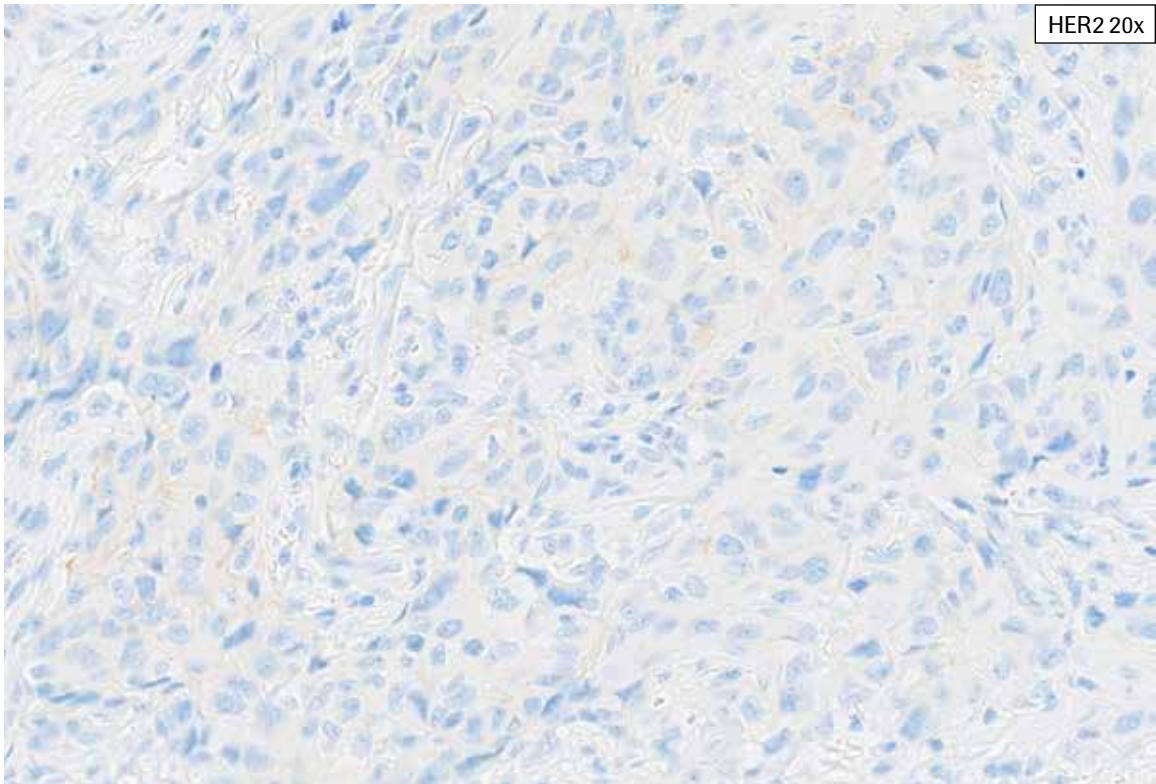
**HER2 IHC Score 0, Case 2:** This case shows tumor with cytoplasmic bluish tinge, making discernment of true faint to weak membrane staining difficult and requiring examination at 40x magnification. Tumor cells show staining along open spaces due to retraction. This case showed 1% partial, faint to weak membrane staining and was scored as HER2 IHC Score 0.



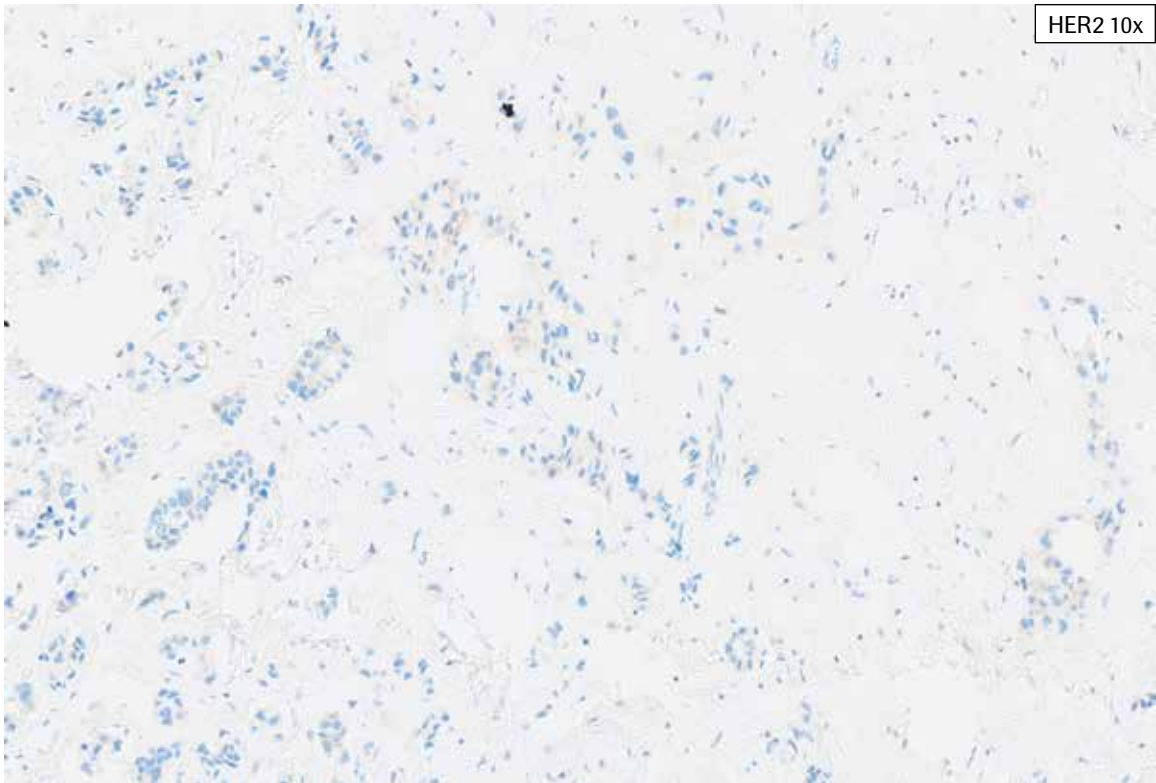
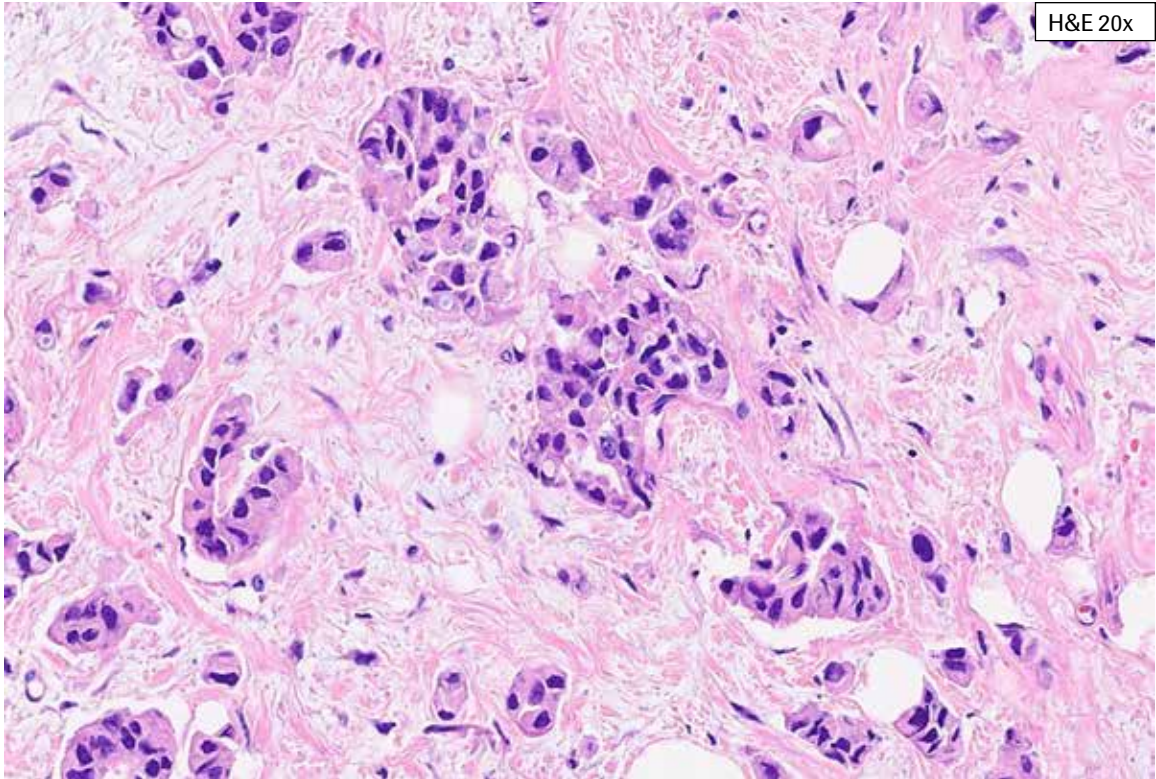
**HER2 IHC Score 0, Case 2:** This case shows tumor with cytoplasmic blush, making discernment of true faint to weak membrane staining difficult and requiring examination at 40x magnification. Tumor cells show staining along open spaces due to retraction (not included in HER2 scoring, indicated by arrows). This case showed 1% partial, faint to weak membrane staining and was scored as HER2 IHC Score 0.



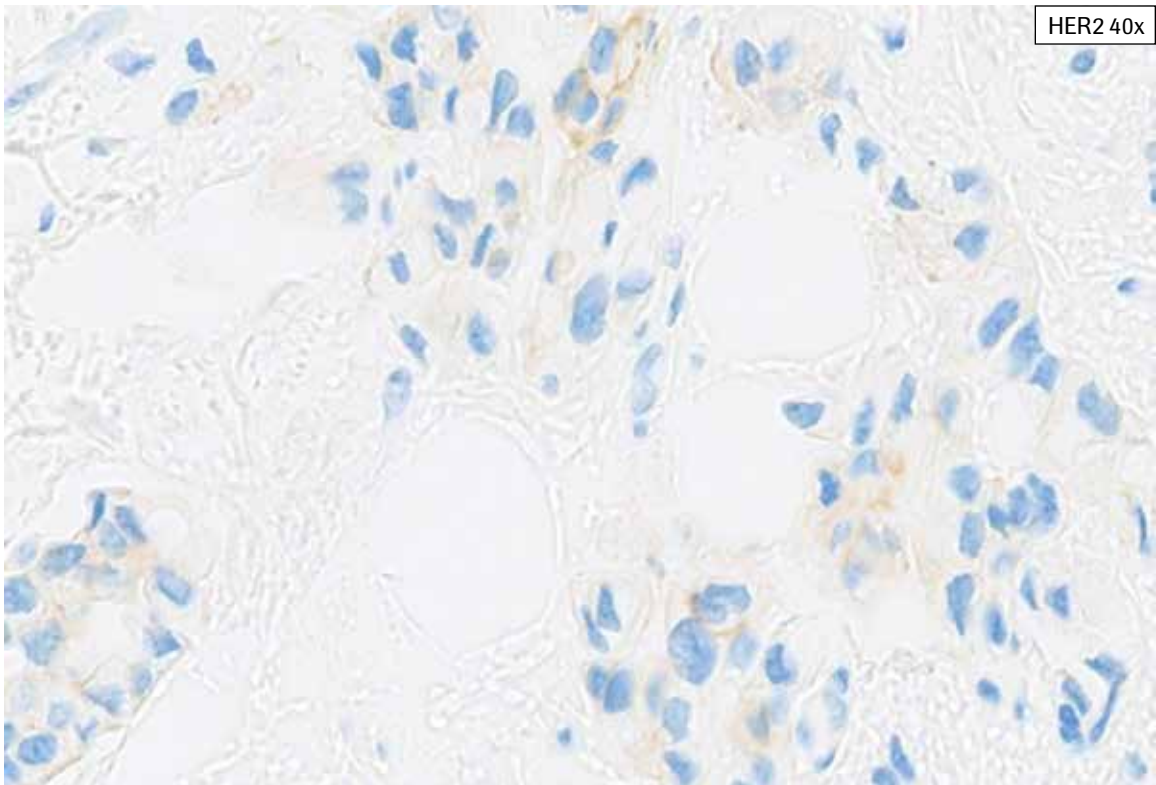
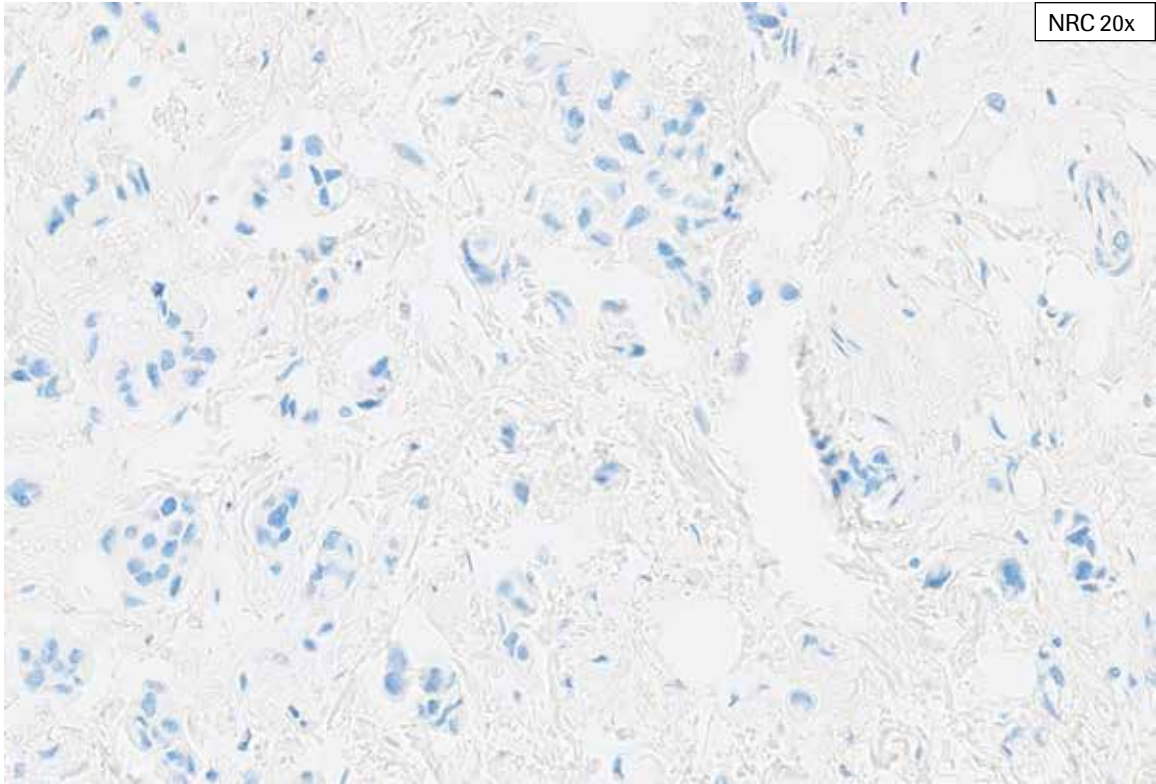
**HER2 IHC Score 0, Case 3:** This case shows tumor with patchy necrosis. Tumor cells show cytoplasmic bluish, making discernment of true faint to weak membrane staining difficult. Any staining in tumor cells associated with necrosis is not included in HER2 scoring. Occasional tumor cells show true faint to weak membrane staining. This case showed 3% partial, faint to weak membrane staining and was scored as HER2 IHC Score 0.



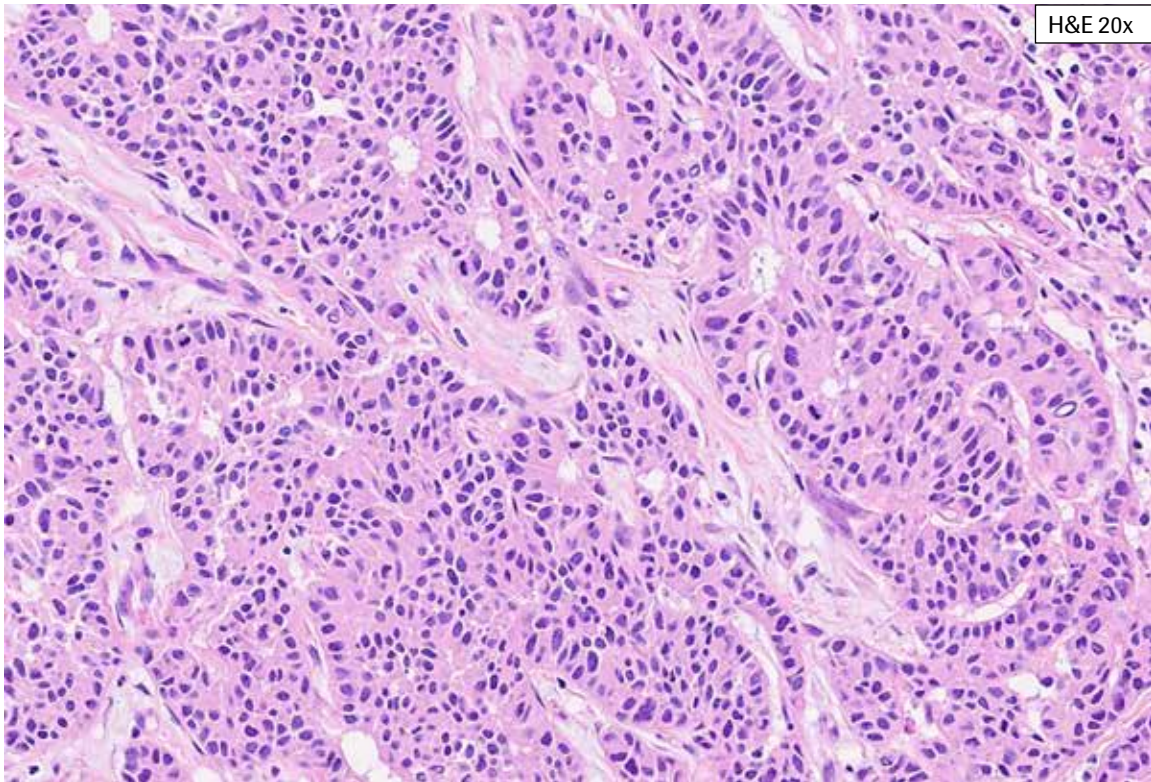
**HER2 IHC Score 0, Case 3:** This case shows tumor with patchy necrosis. Tumor cells show cytoplasmic bluish, making discernment of true faint to weak membrane staining difficult. Any staining in tumor cells associated with necrosis is not included in HER2 scoring. Occasional tumor cells show true faint to weak membrane staining (indicated by arrows). This case showed 3% partial, faint to weak membrane staining and was scored as HER2 IHC Score 0.



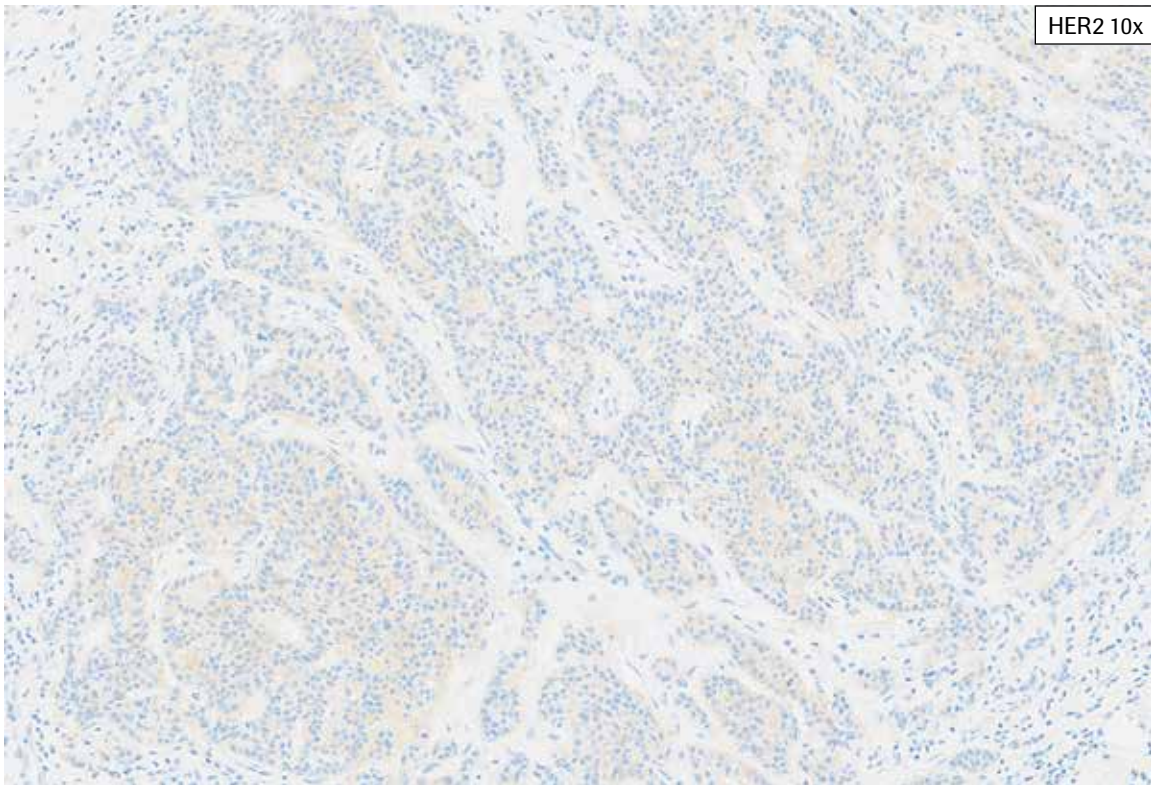
**HER2 IHC Score 0, Case 4:** Abundant invasive tumor with retraction artifact is seen in this case. Scattered tumor cells show partial, faint to weak membrane staining and patchy cytoplasmic bluish. The NRC is shown at 20x, and it does not contain the cytoplasmic bluish. HER2 staining present only along the basal aspect (retracted edge) of tumor cells is not included in scoring. HER2 staining must also extend along the lateral aspects of the tumor cell to be included in scoring. This case showed 4% partial, faint to weak membrane staining overall and was scored as HER2 IHC Score 0.



**HER2 IHC Score 0, Case 4:** Abundant invasive tumor with retraction artifact is seen in this case. Scattered tumor cells show partial, faint to weak membrane staining and patchy cytoplasmic blush. The NRC is shown at 20x, and it does not contain the cytoplasmic blush. HER2 staining present only along the basal aspect (retracted edge) of tumor cells is not included in scoring. HER2 staining must also extend along the lateral aspects of the tumor cell to be included in scoring. This case showed 4% partial, faint to weak membrane staining overall and was scored as HER2 IHC Score 0.



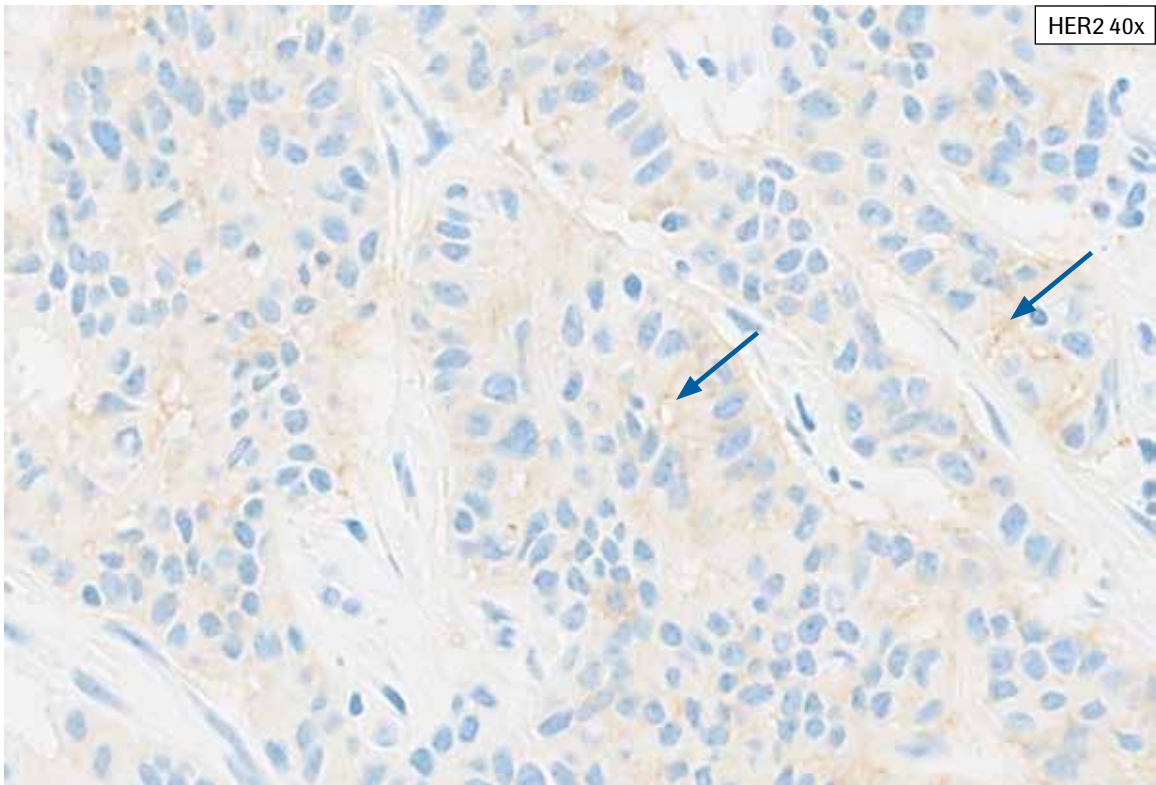
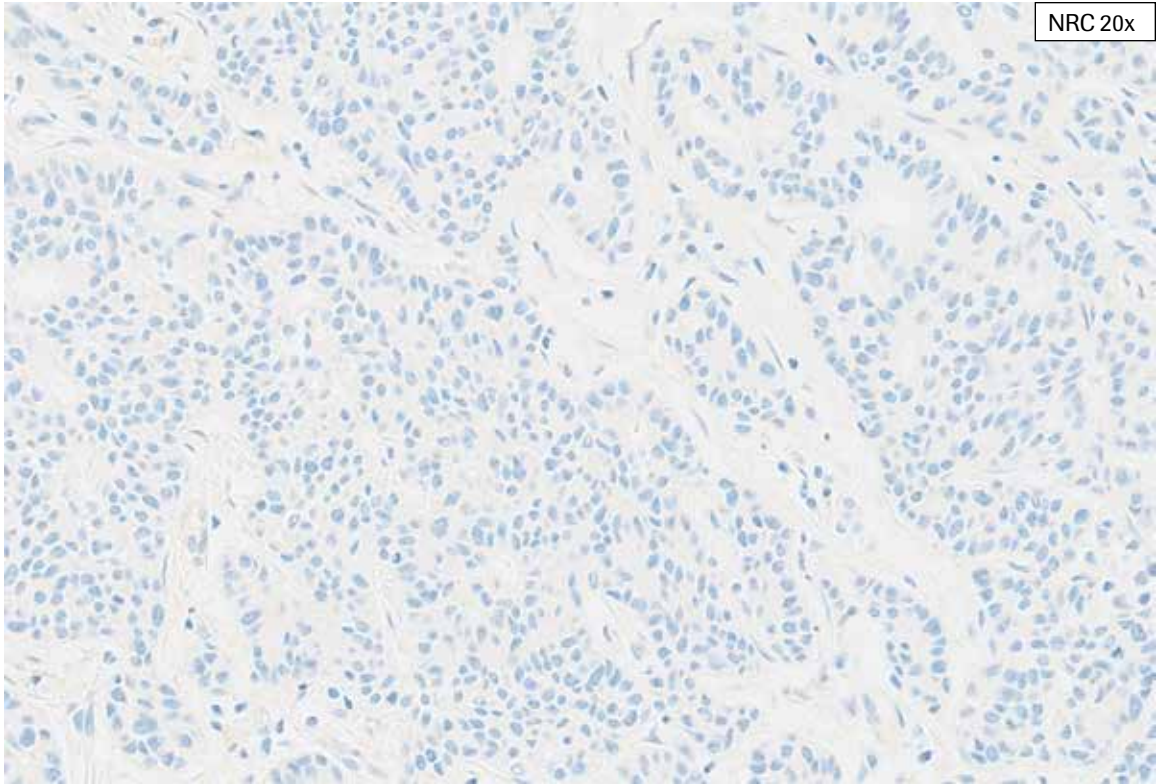
H&E 20x



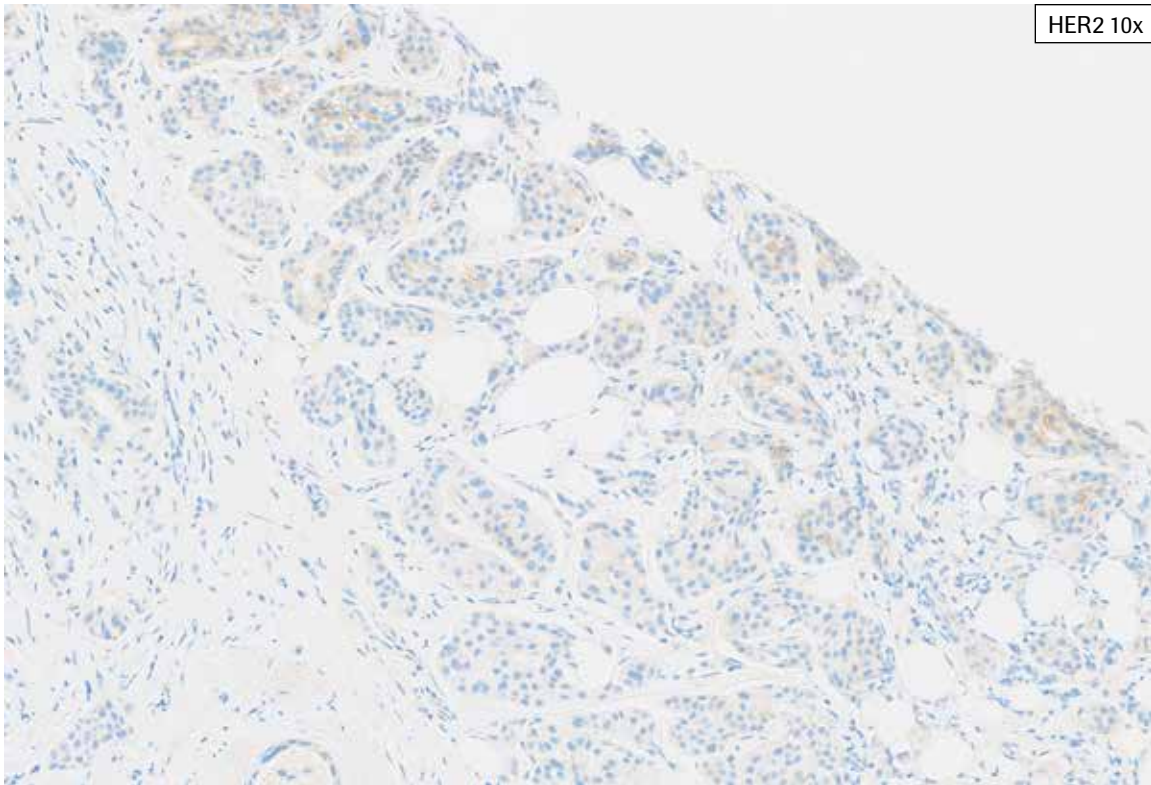
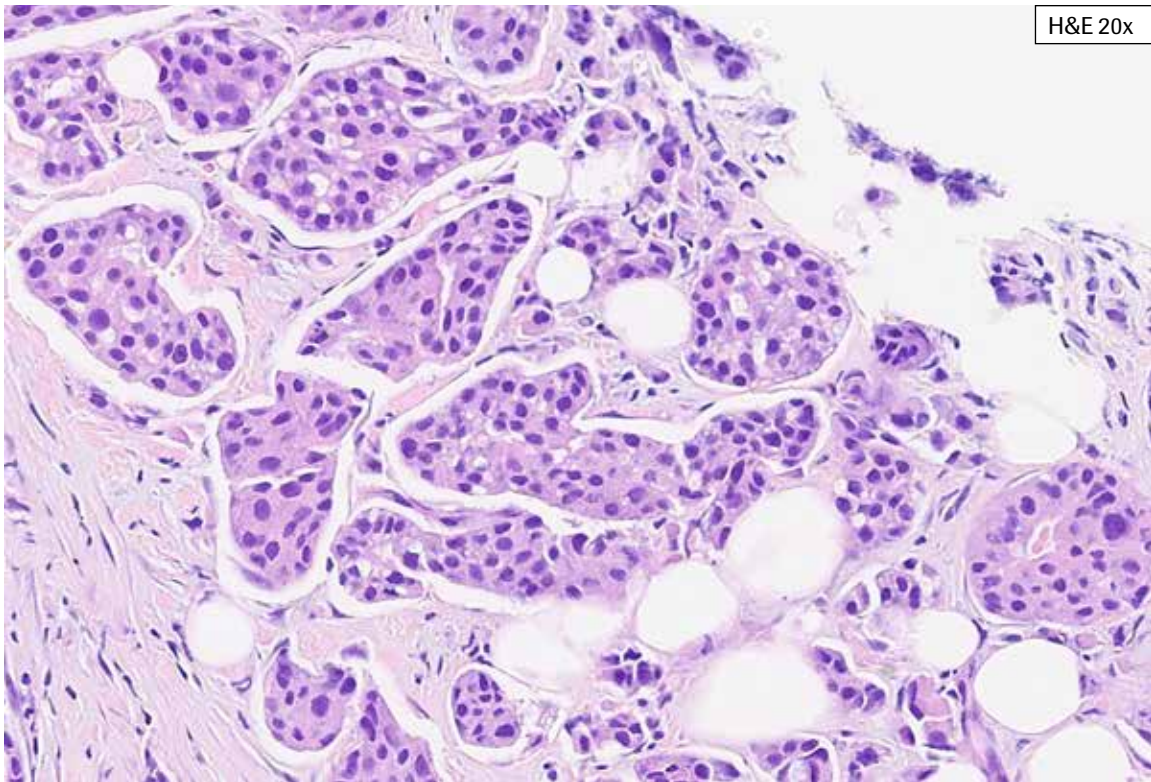
HER2 10x

**HER2 IHC Score 0, Case 5:** This large tissue section shows abundant invasive tumor. Scattered partial, faint to weak tumor cell membrane staining. The NRC is shown at 20x, and it does not contain the cytoplasmic blush. Staining is seen along open spaces and is included in HER2 scoring only if HER2 staining extends along the lateral tumor cell membrane. This case showed 8% partial, faint to weak membrane staining and was scored as HER2 IHC Score 0. The patchy nature of the HER2 staining in this large tissue section makes it difficult to estimate the percent HER2 staining. This case is also challenging in that the percent HER2 staining is close to the cutoff for HER2 IHC Score 1+.

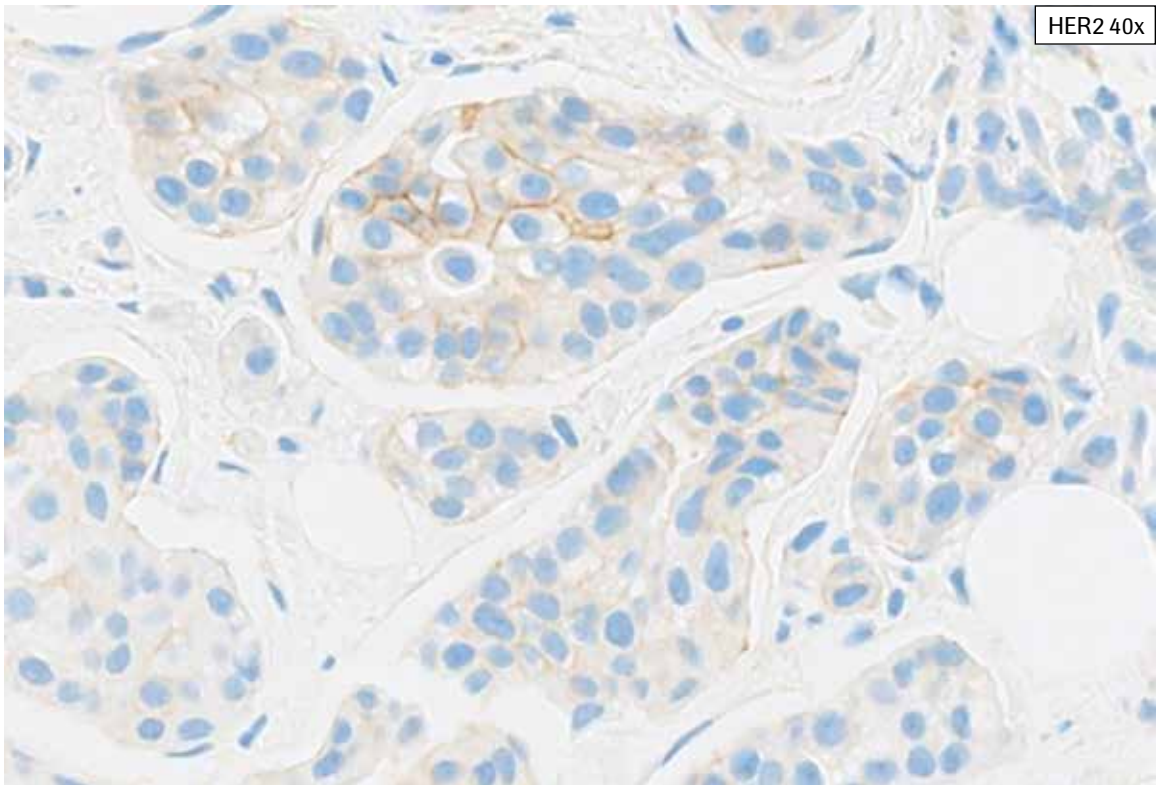
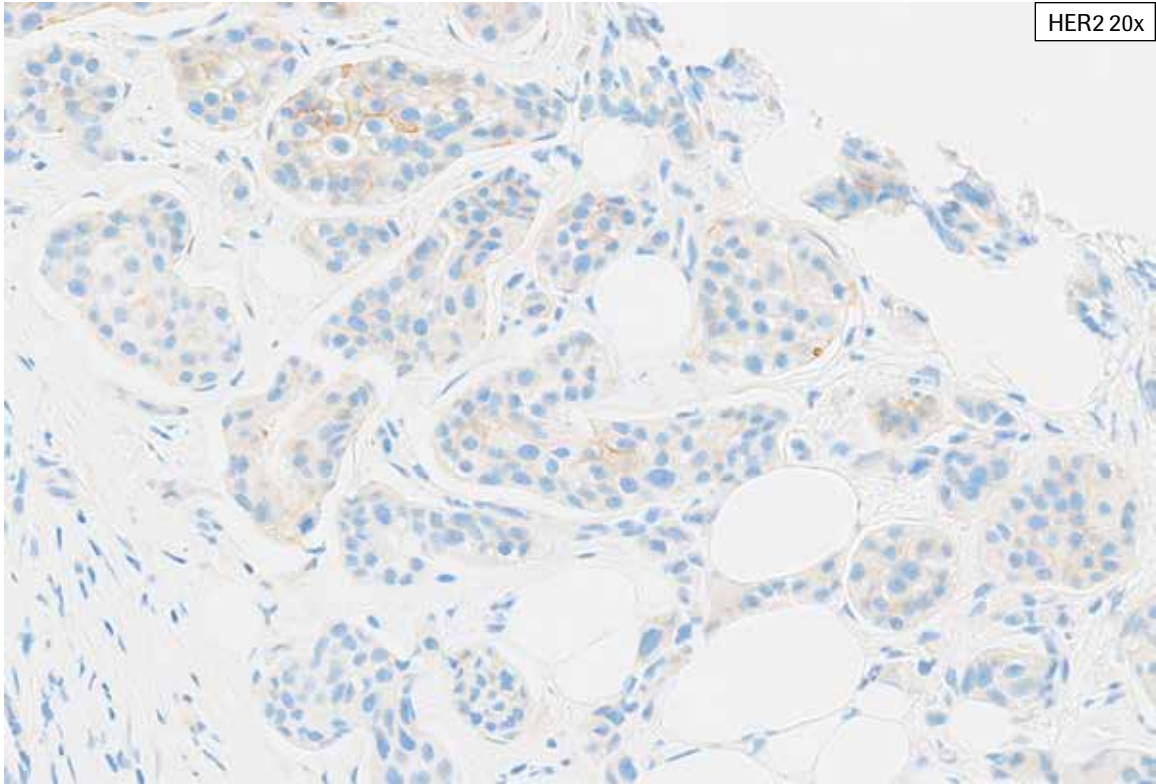




**HER2 IHC Score 0, Case 5:** This large tissue section shows abundant invasive tumor. Scattered partial, faint to weak tumor cell membrane staining. The NRC is shown at 20x, and it does not contain the cytoplasmic blush. Staining is seen along open spaces and is included in HER2 scoring only if HER2 staining extends along the lateral tumor cell membrane (arrows). This case showed 8% partial, faint to weak membrane staining and was scored as HER2 IHC Score 0. The patchy nature of the HER2 staining in this large tissue section makes it difficult to estimate the percent HER2 staining. This case is also challenging in that the percent HER2 staining is close to the cutoff for HER2 IHC Score 1+.

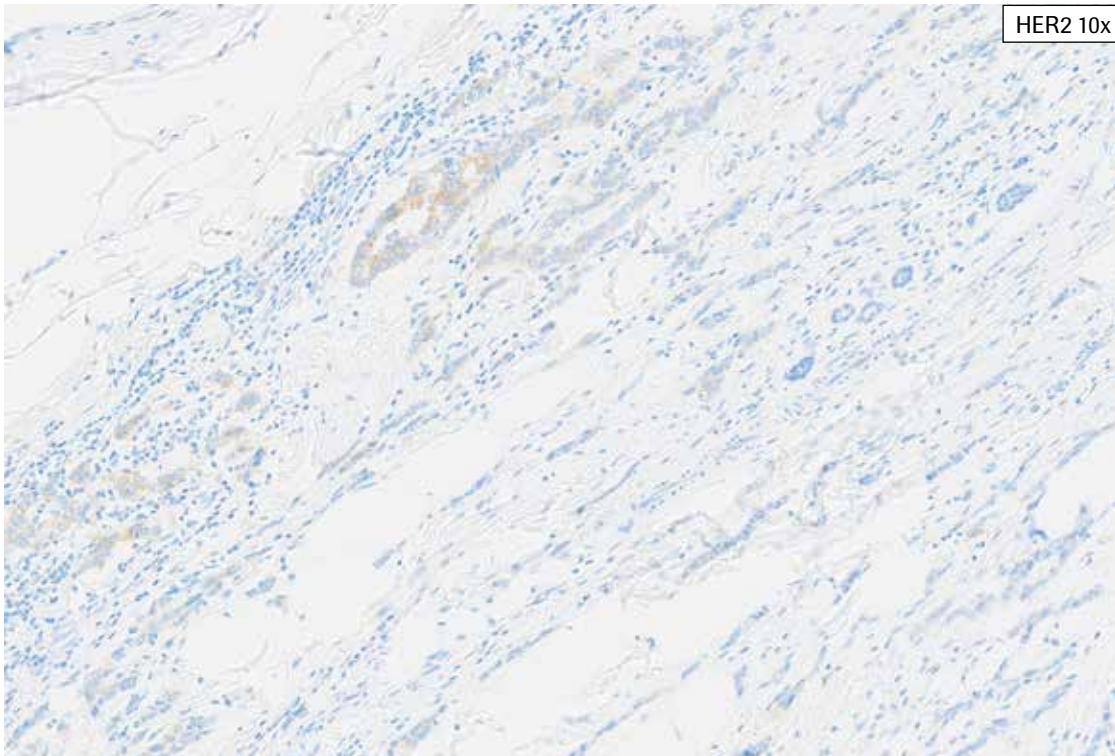
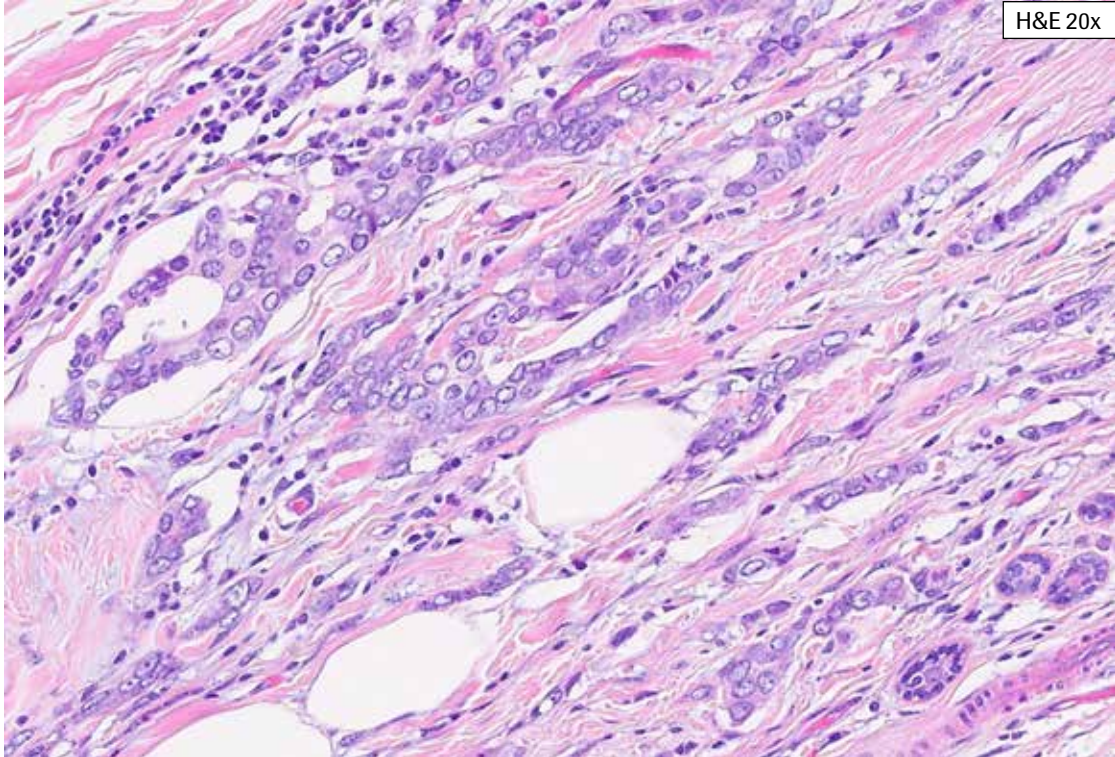


**HER2 IHC Score 0, Case 6:** This is a challenging biopsy case with tumor showing cytoplasmic blush. While some membrane staining is apparent at 10x, as the tissue is examined at 20x and then 40x, more faint to weak partial membrane staining becomes apparent. This case is challenging due to the cytoplasmic blush present and the overall percent of partial faint to weak staining is 9%, extremely close to the HER2 IHC Score 1+ cutoff.





**HER2 IHC Score 0, Case 6:** This is a challenging biopsy case with tumor showing cytoplasmic bluish. While some membrane staining is apparent at 10x, as the tissue is examined at 20x and then 40x, more faint to weak partial membrane staining becomes apparent. This case is challenging due to the cytoplasmic bluish present and the overall percent of partial faint to weak staining is 9%, extremely close to the HER2 IHC Score 1+ cutoff.

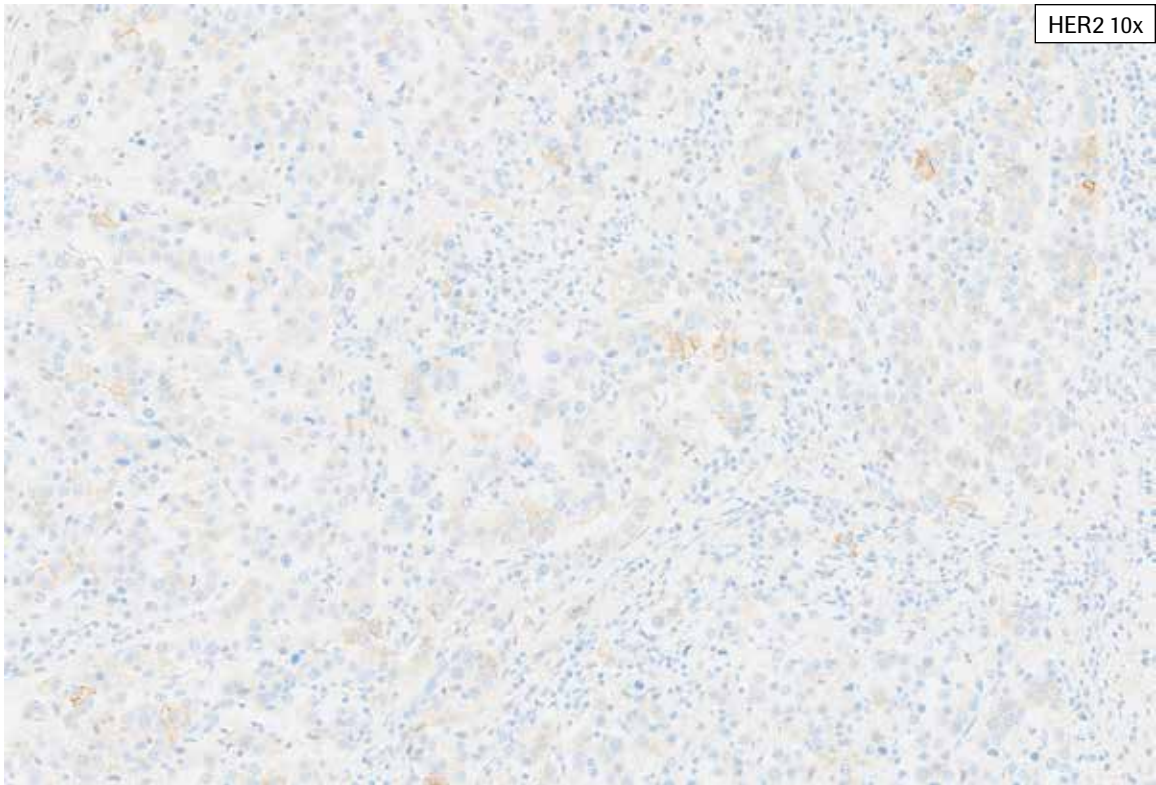
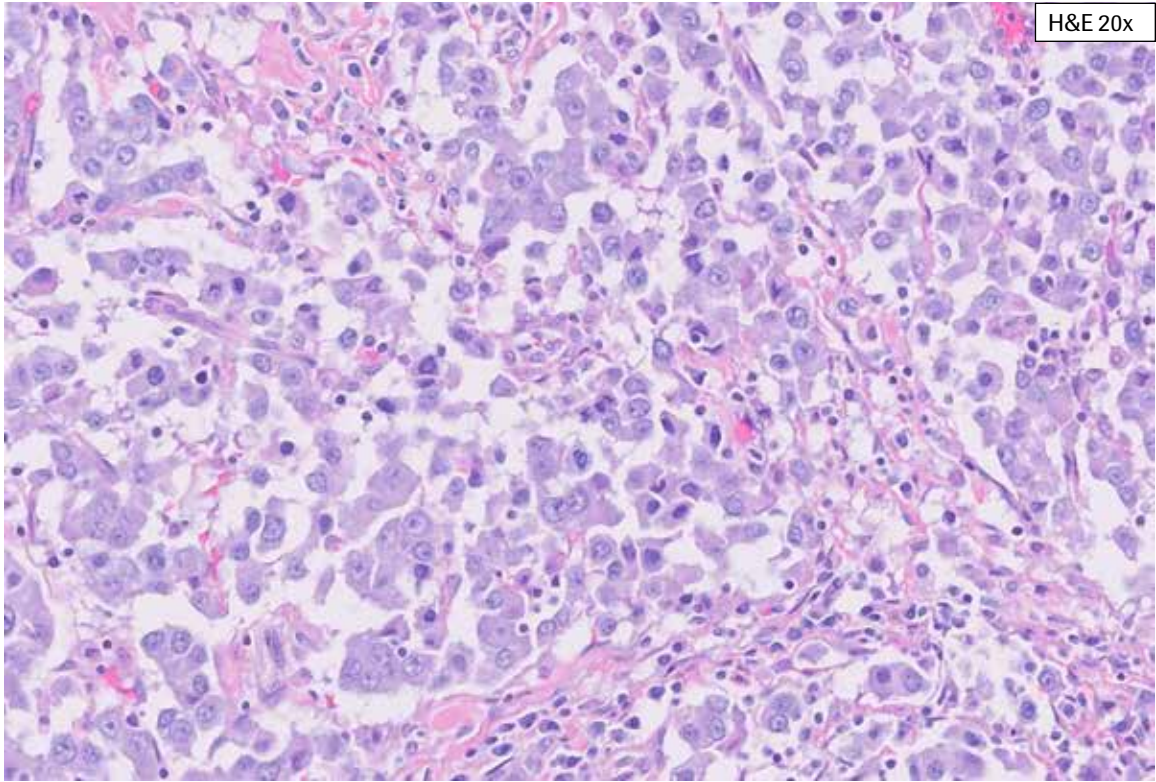
## PATHWAY anti-HER-2/neu Rabbit Monoclonal Antibody Staining in Breast Cancer: IHC Score 1+



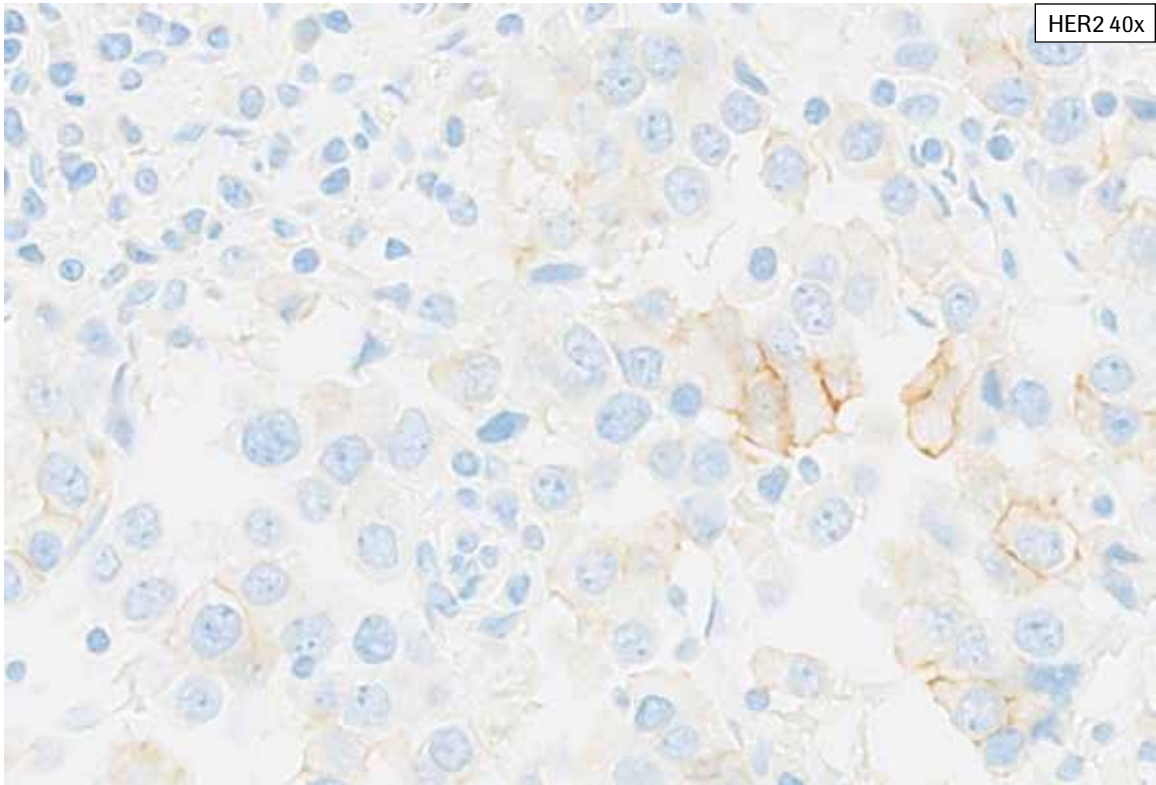
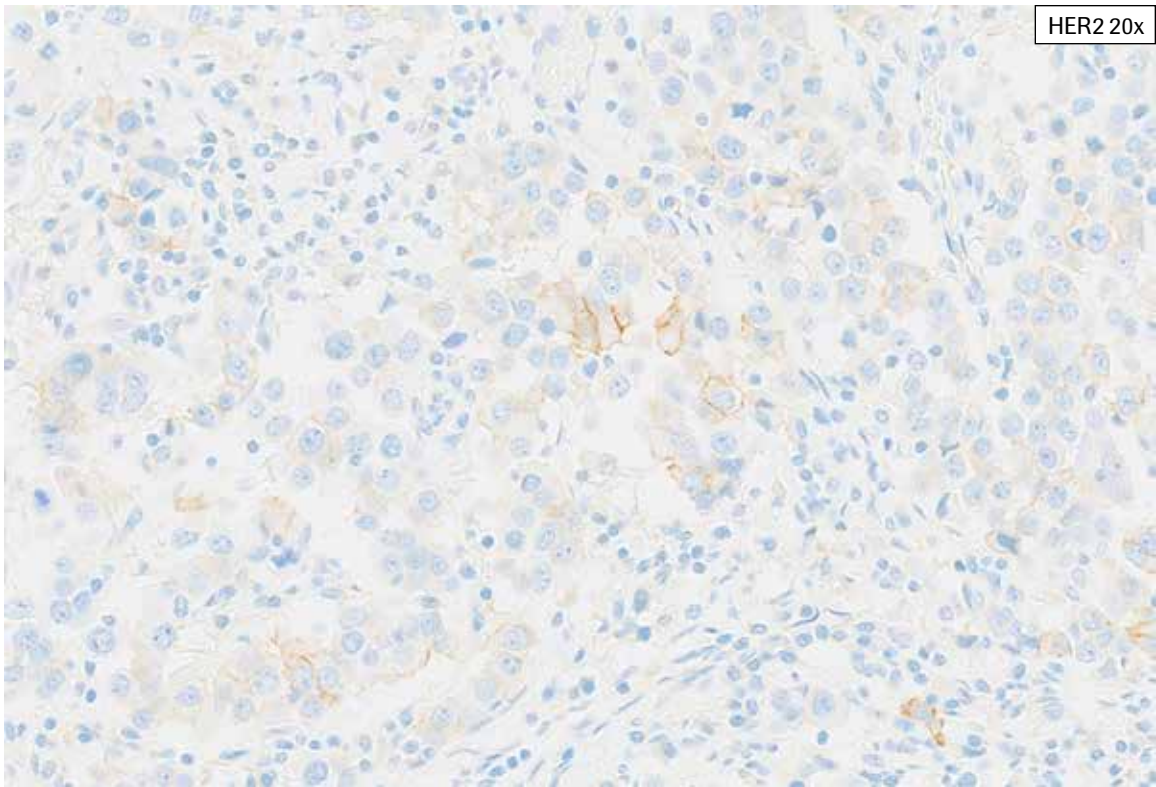
**HER2 IHC Score 1+, Case 1:** This case shows tumor with cytoplasmic blush, making discernment of true faint to weak membrane staining difficult. While some HER2 staining is apparent at 10x, examination at higher magnifications (up to 40x) is necessary to see the faint membrane staining. This is a challenging case showing 12% partial, faint to weak membrane staining and was scored as HER2 IHC Score 1+.



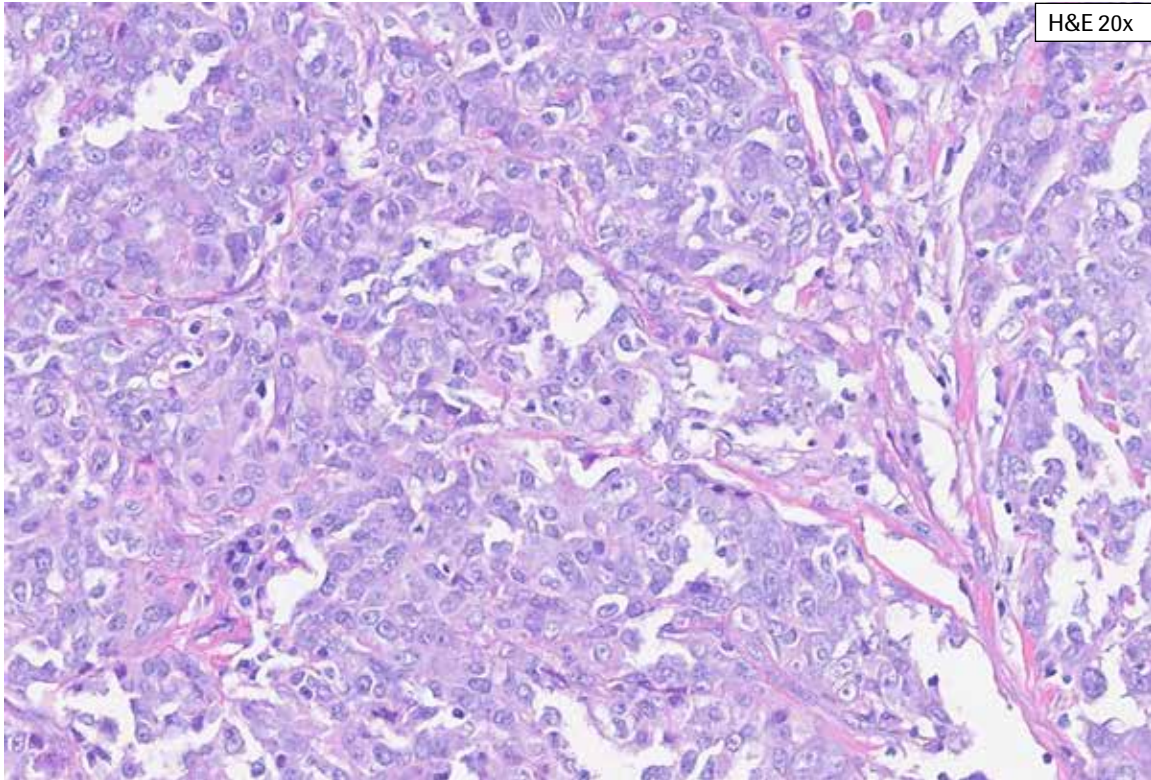
**HER2 IHC Score 1+, Case 1:** This case shows tumor with cytoplasmic bluish, making discernment of true faint to weak membrane staining difficult. While some HER2 staining is apparent at 10x, examination at higher magnifications (up to 40x) is necessary to see the faint membrane staining (arrows). This is a challenging case showing 12% partial, faint to weak membrane staining and was scored as HER2 IHC Score 1+.



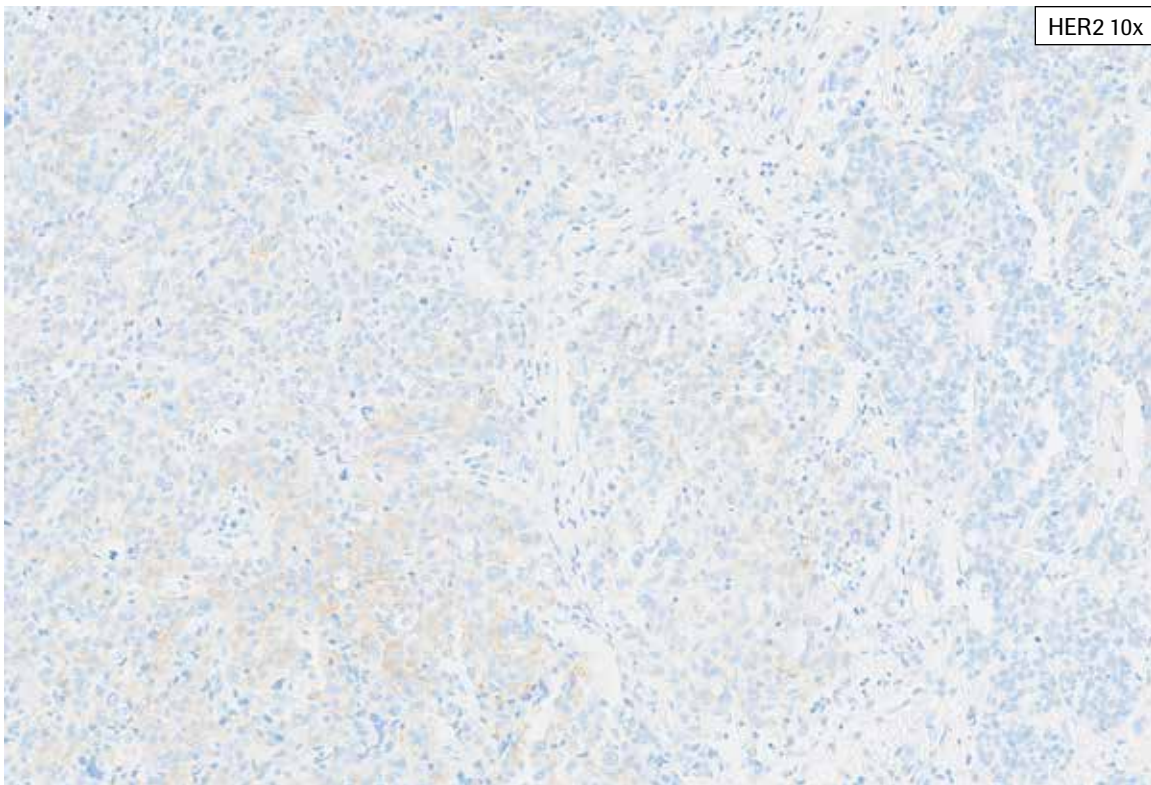
**HER2 IHC Score 1+, Case 2:** This case shows tumor with cytoplasmic blush, making discernment of true faint to weak membrane staining difficult and requiring examination at 40x magnification. Occasional cells are seen with weak complete membrane staining, but these cells represent <10% of the tumor cell population. This is a challenging case showing 15% tumor membrane staining and was scored as HER2 IHC Score 1+.



**HER2 IHC Score 1+, Case 2:** This case shows tumor with cytoplasmic blush, making discernment of true faint to weak membrane staining difficult and requiring examination at 40x magnification. Occasional cells are seen with weak complete membrane staining, but these cells represent <10% of the tumor cell population. This is a challenging case showing 15% tumor membrane staining and was scored as HER2 IHC Score 1+.



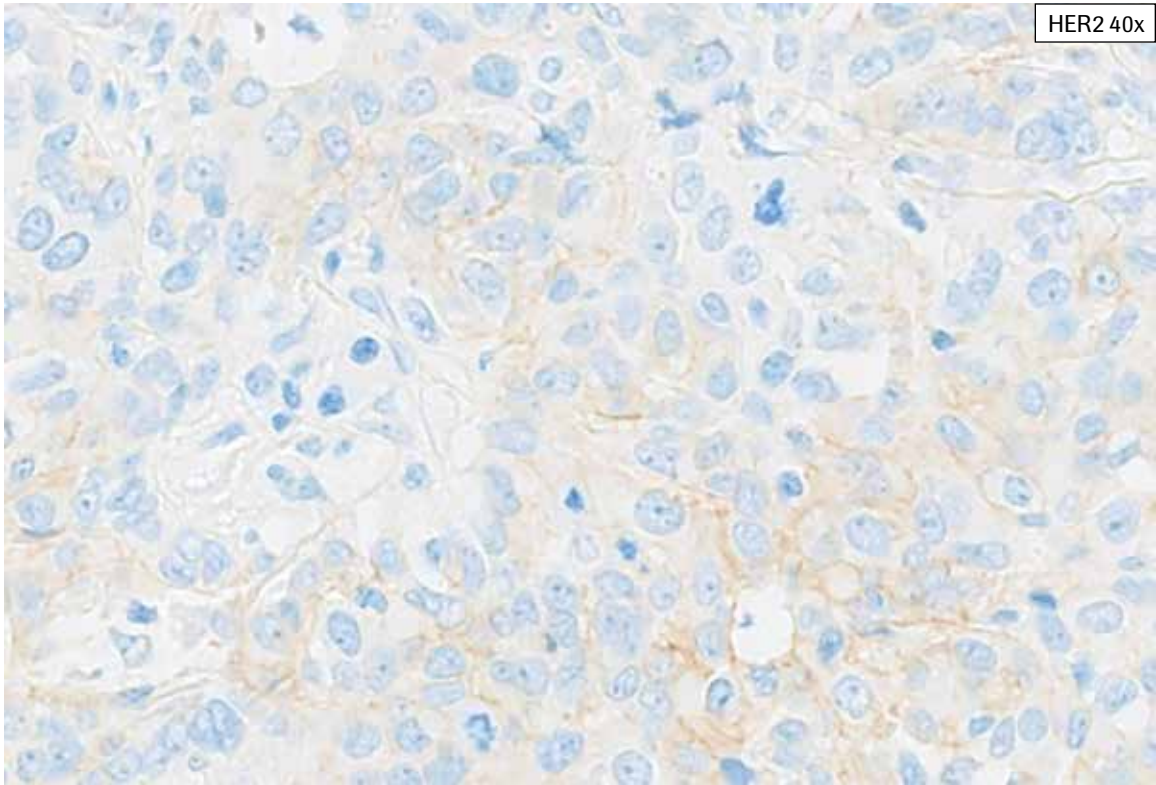
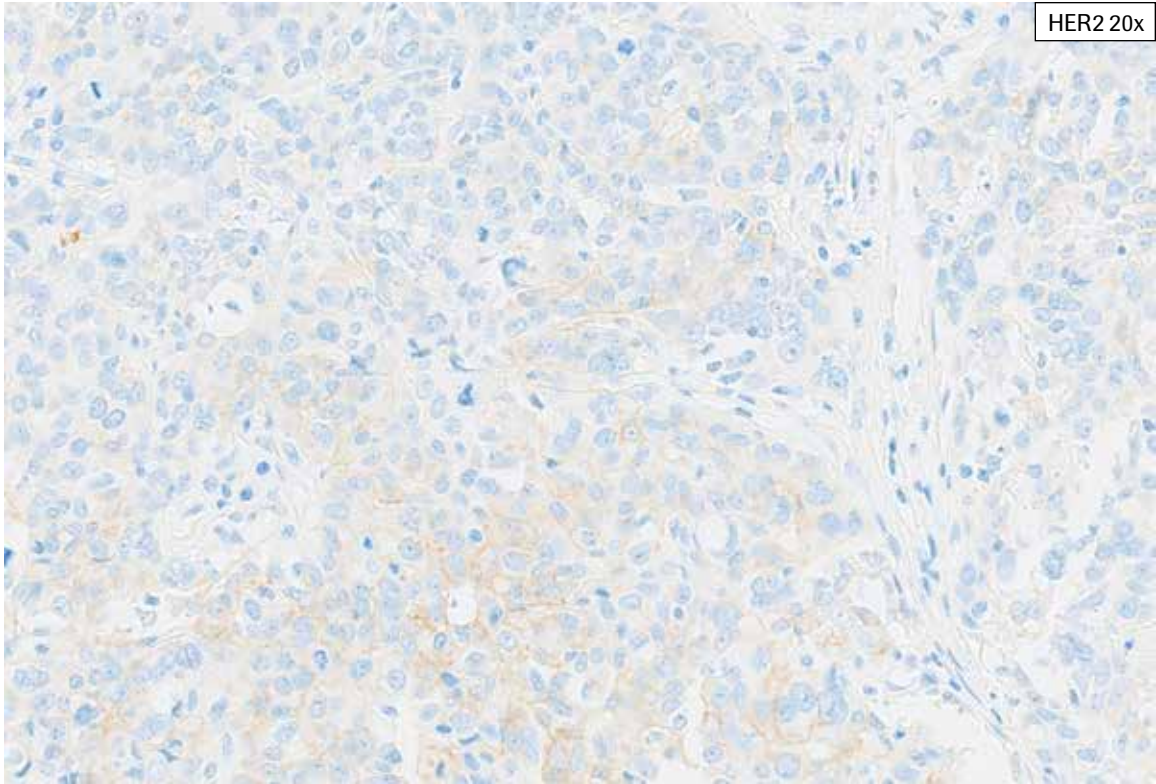
H&E 20x



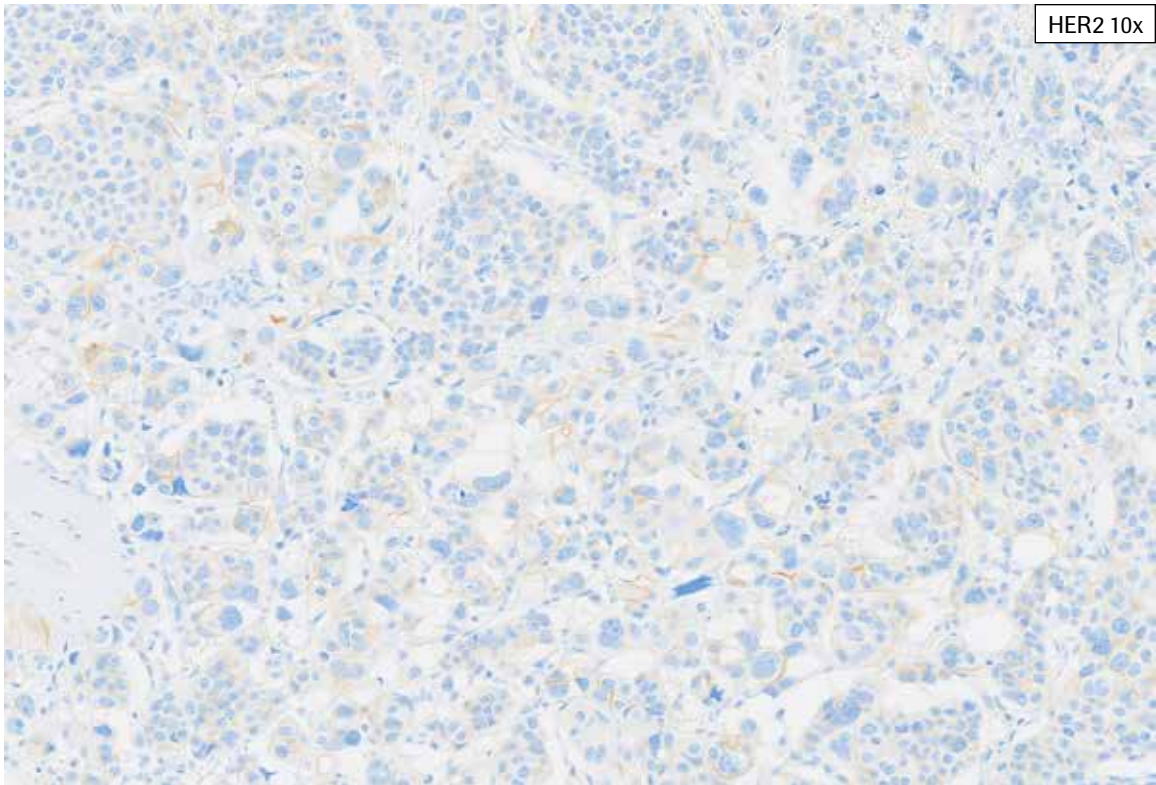
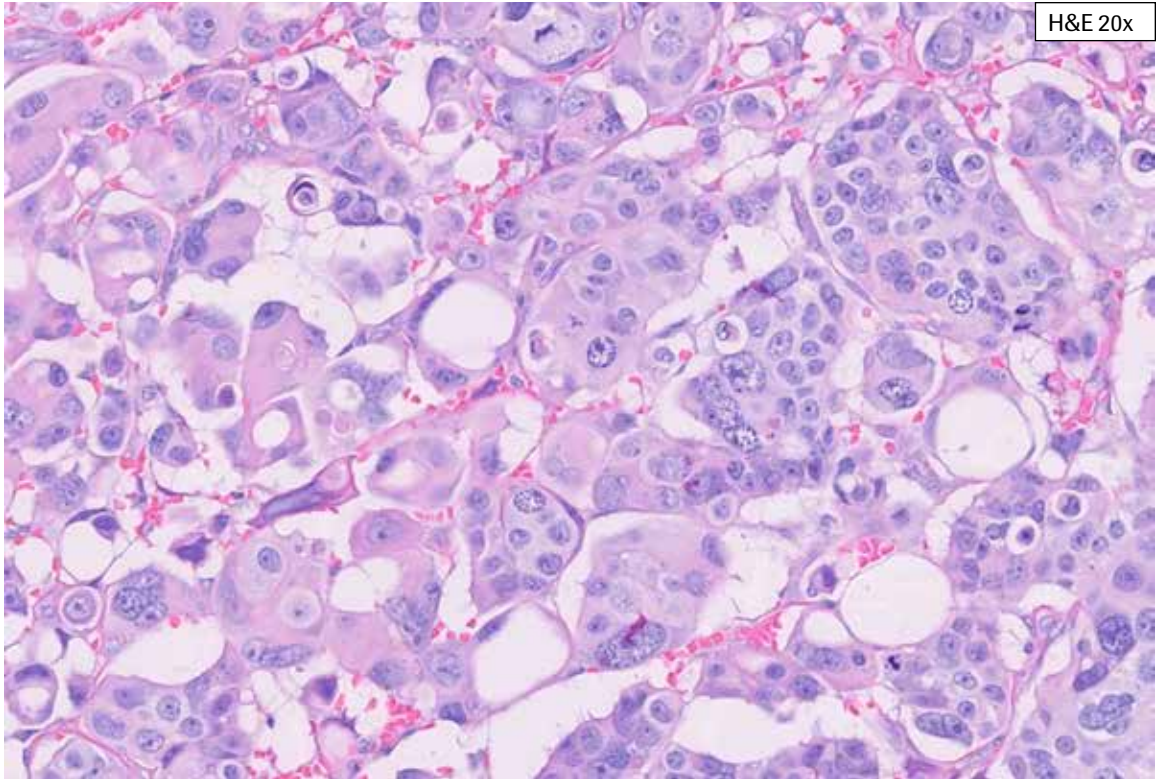
HER2 10x

**HER2 IHC Score 1+, Case 3:** This biopsy case shows abundant invasive tumor with some necrosis. Non-neoplastic breast epithelium is also present. Patchy variable cytoplasmic blush is seen (even from lower magnification). Patchy faint to moderate partial membrane staining is seen. A rare tumor cell shows complete membrane staining. While some tumor cell membrane staining can be seen at a lower magnification, it is necessary to review the tissue at 40x to include all faint membrane staining. This case is challenging with 20% tumor cell membrane staining and was scored as HER2 IHC Score 1+.

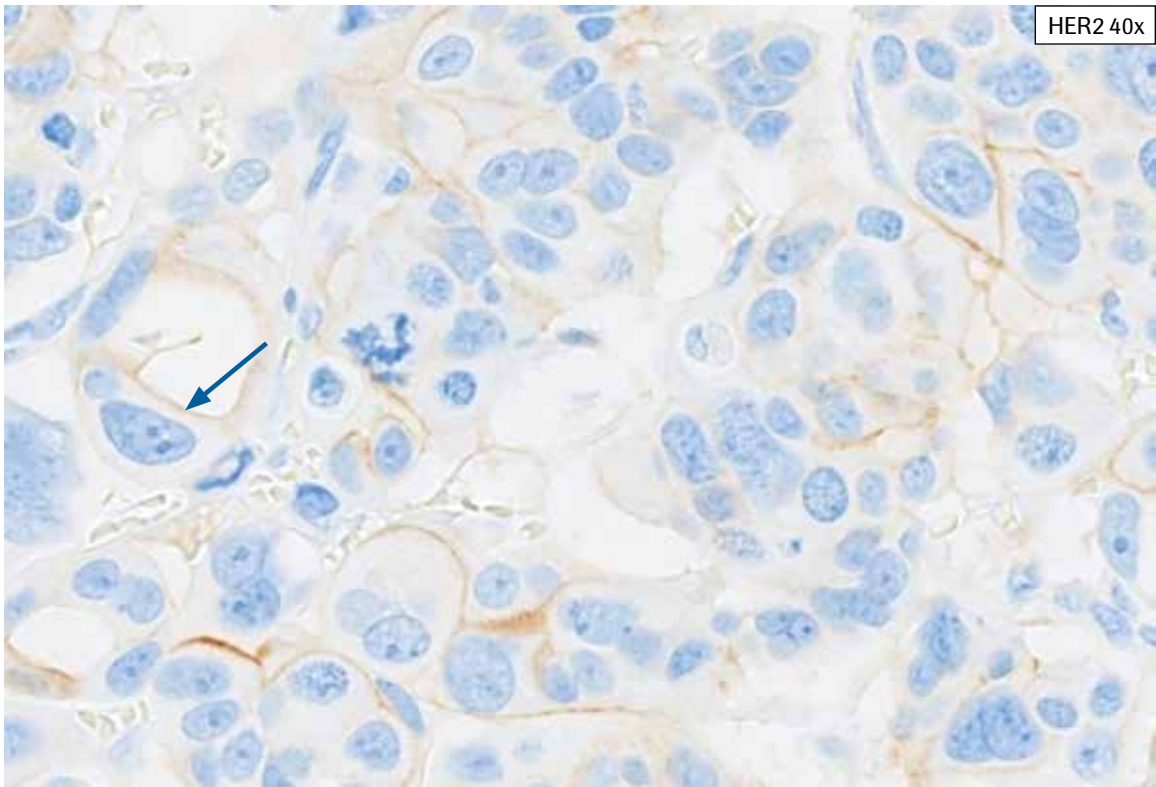
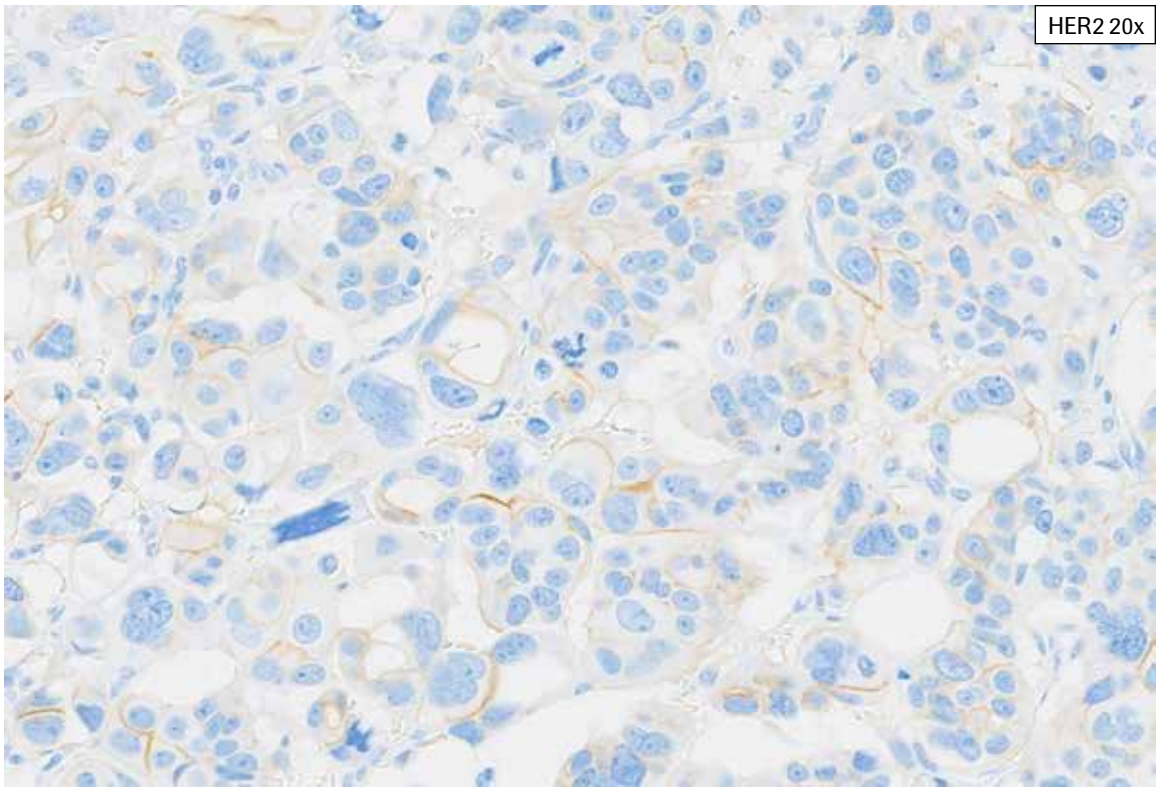




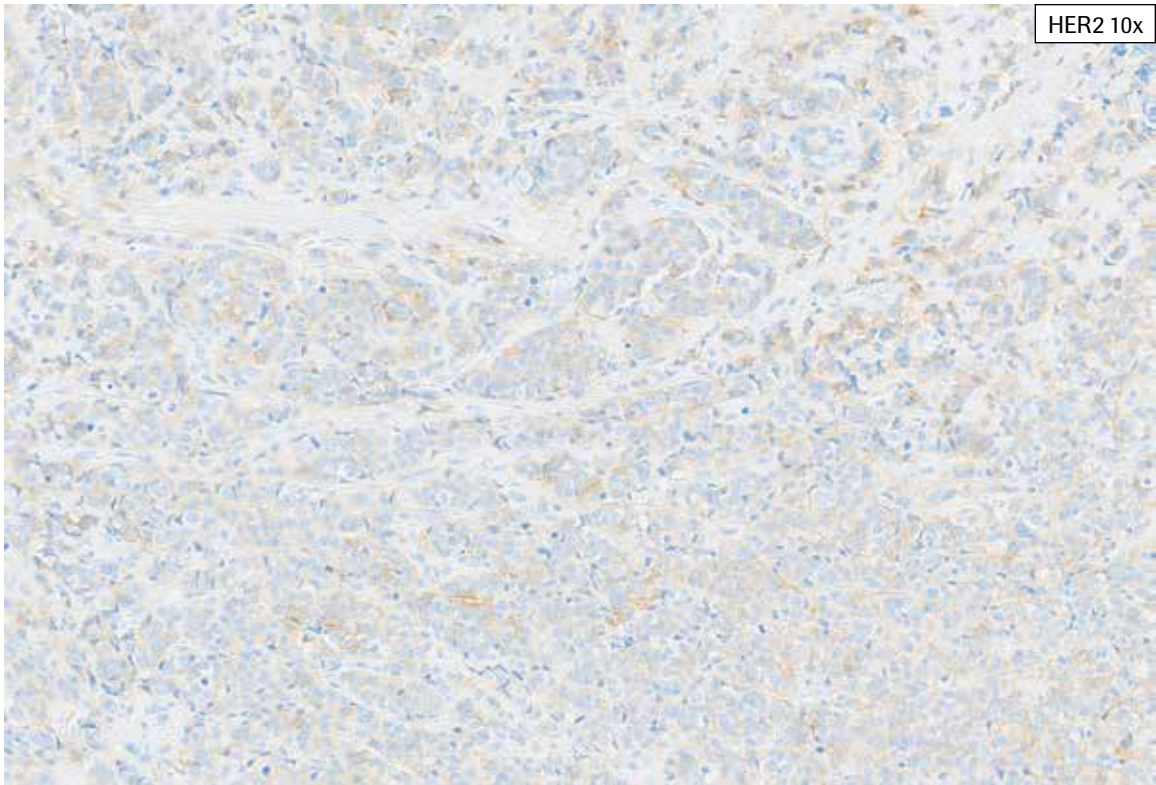
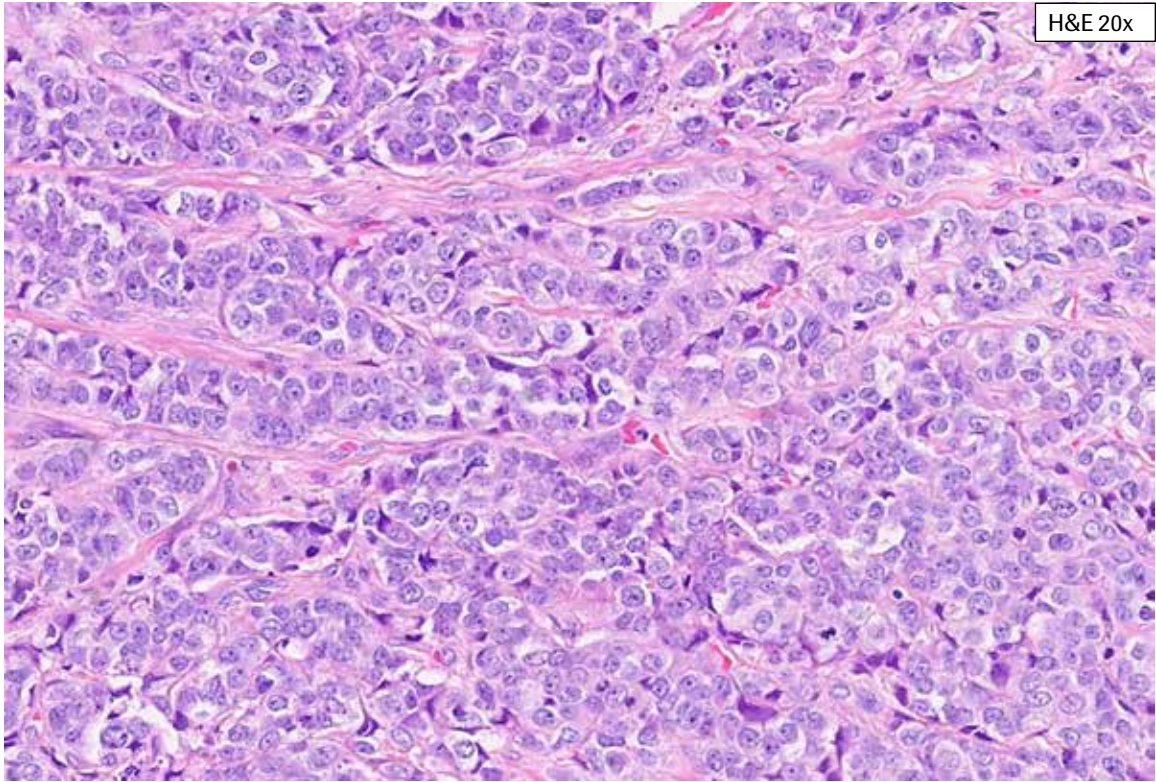
**HER2 IHC Score 1+, Case 3:** This biopsy case shows abundant invasive tumor with some necrosis. Non-neoplastic breast epithelium is also present. Patchy variable cytoplasmic blush is seen (even from lower magnification). Patchy faint to moderate partial membrane staining is seen. A rare tumor cell shows complete membrane staining. While some tumor cell membrane staining can be seen at a lower magnification, it is necessary to review the tissue at 40x to include all faint membrane staining. This case is challenging with 20% tumor cell membrane staining and was scored as HER2 IHC Score 1+.



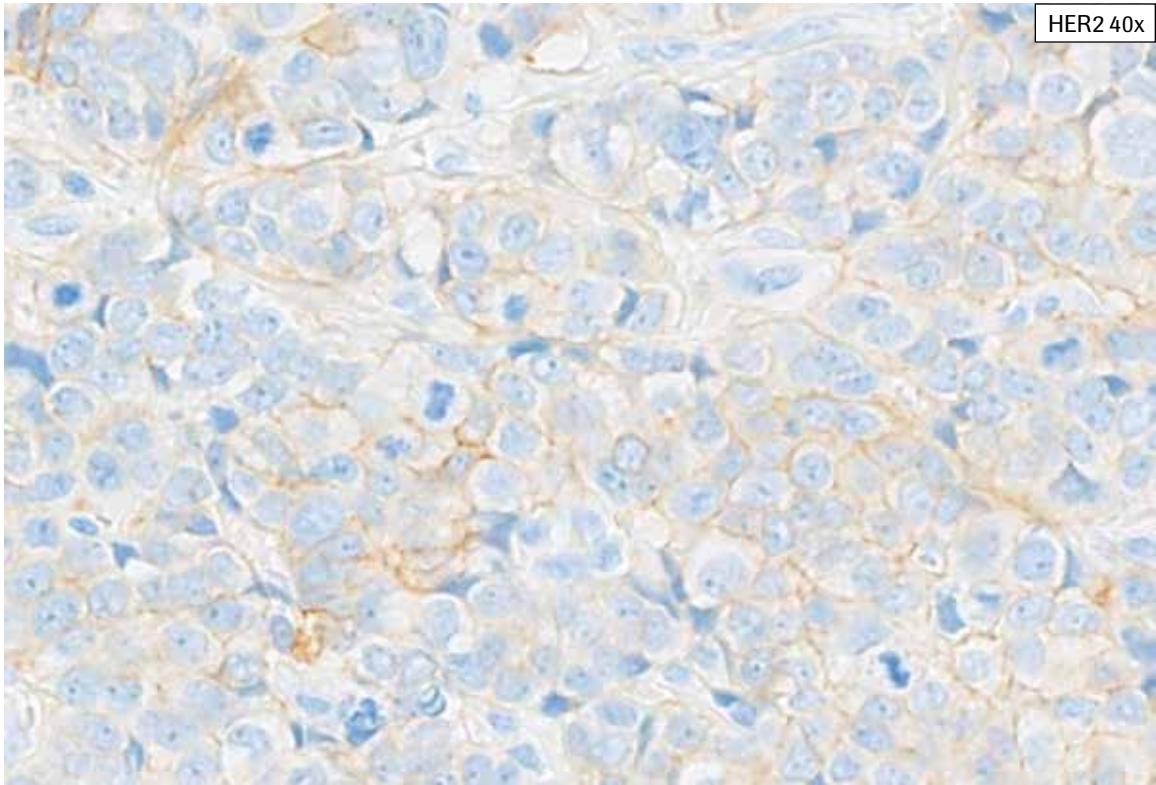
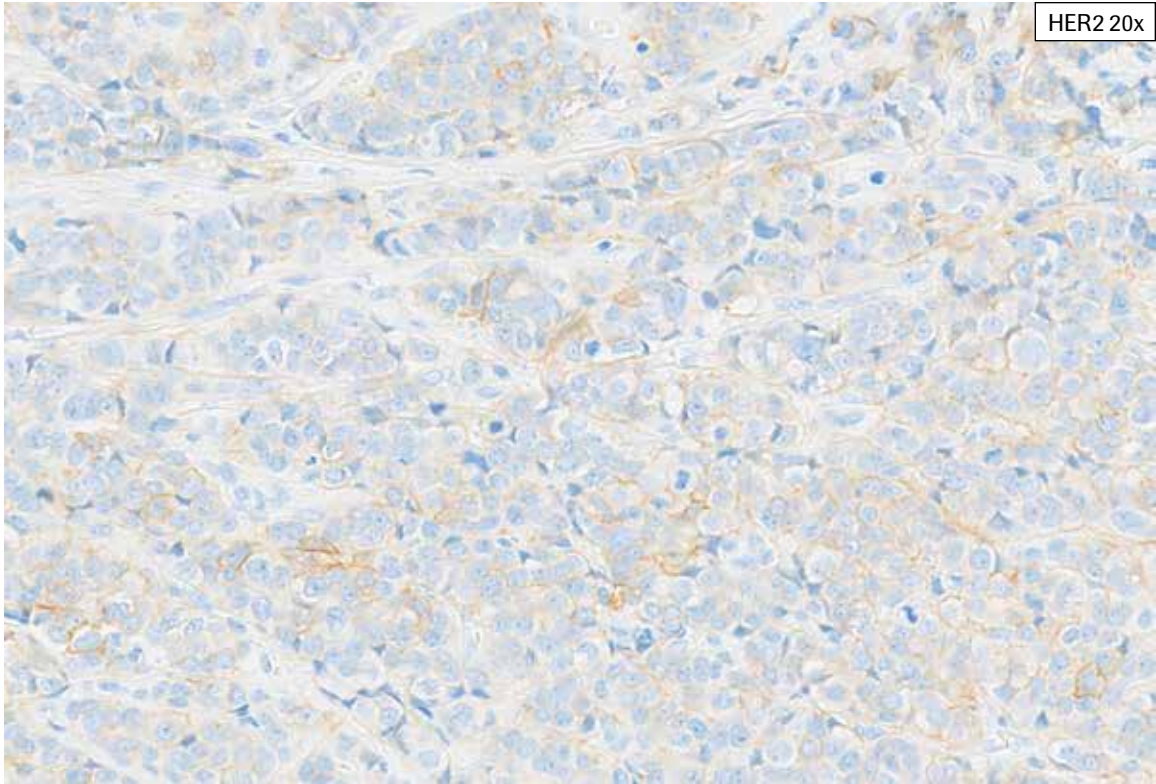
**HER2 IHC Score 1+, Case 4:** Abundant invasive tumor with cytoplasmic blush is seen, making discernment of true faint to weak membrane staining difficult and requiring examination at 40X. Staining along open spaces is present and is not included in HER2 scoring if there is no other tumor cell membrane staining. This is not included in HER2 scoring. Overall, this case shows 35% partial tumor cell membrane staining and was scored as HER2 IHC Score 1+.



**HER2 IHC Score 1+, Case 4:** Abundant invasive tumor with cytoplasmic bluish is seen, making discernment of true faint to weak membrane staining difficult and requiring examination at 40X. Staining along open spaces (arrow) is present and is not included in HER2 scoring if there is no other tumor cell membrane staining. This is not included in HER2 scoring. Overall, this case shows 35% partial tumor cell membrane staining and was scored as HER2 IHC Score 1+.


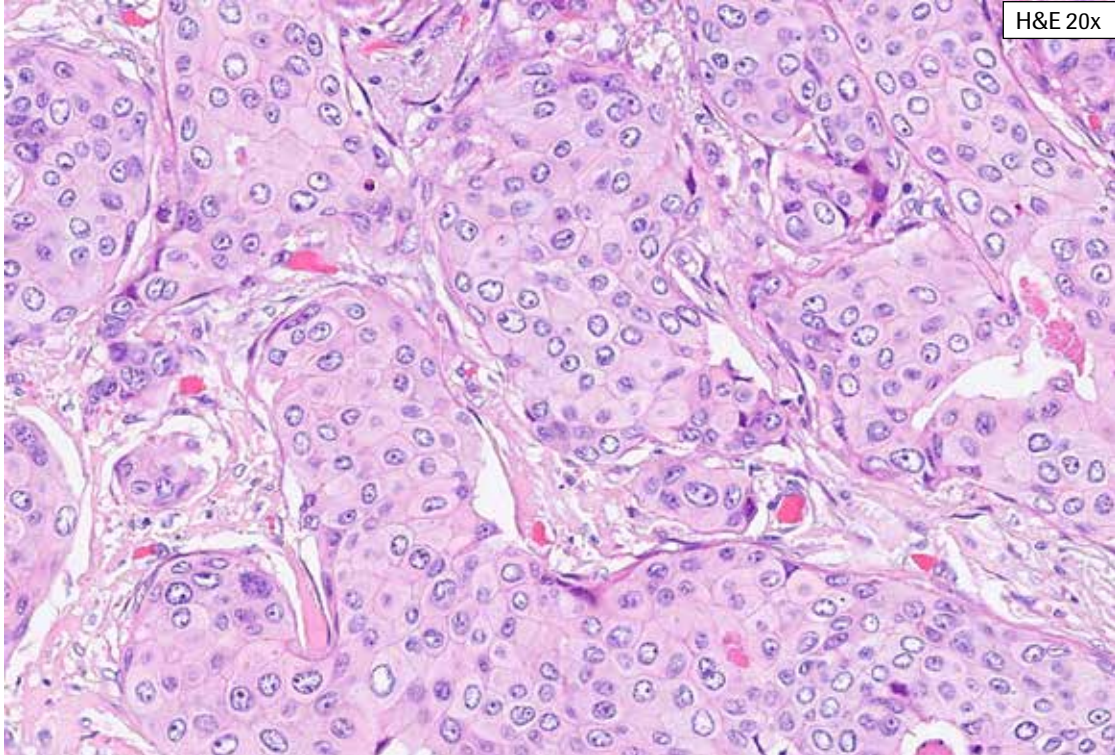


**HER2 IHC Score 1+, Case 5:** This case shows heterogeneity in HER2 membrane staining and variable cytoplasmic blush. Partial faint, weak or moderate membrane staining is present in 35% of tumor cells (HER2 IHC Score 1+). Variable cytoplasmic blush makes discernment of faint to weak membrane staining difficult. Examination at up to 40x magnification is required to include all faint to weak membrane staining in HER2 scoring.

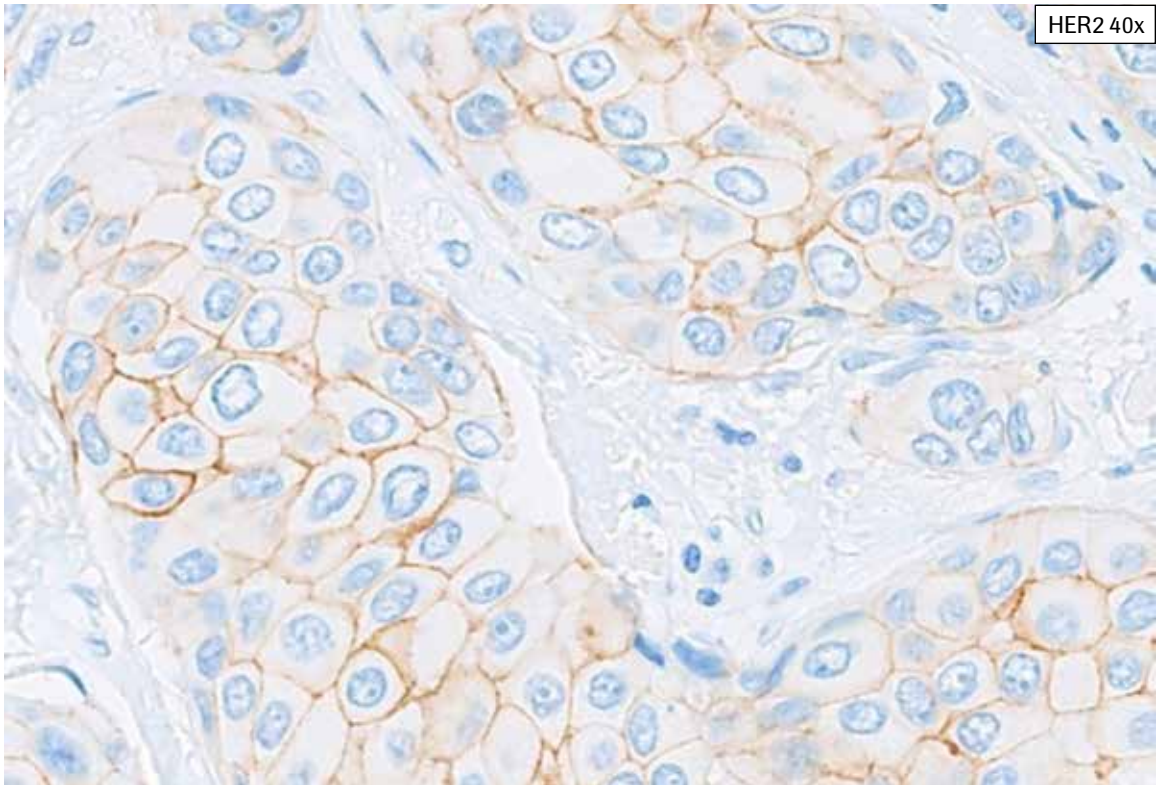
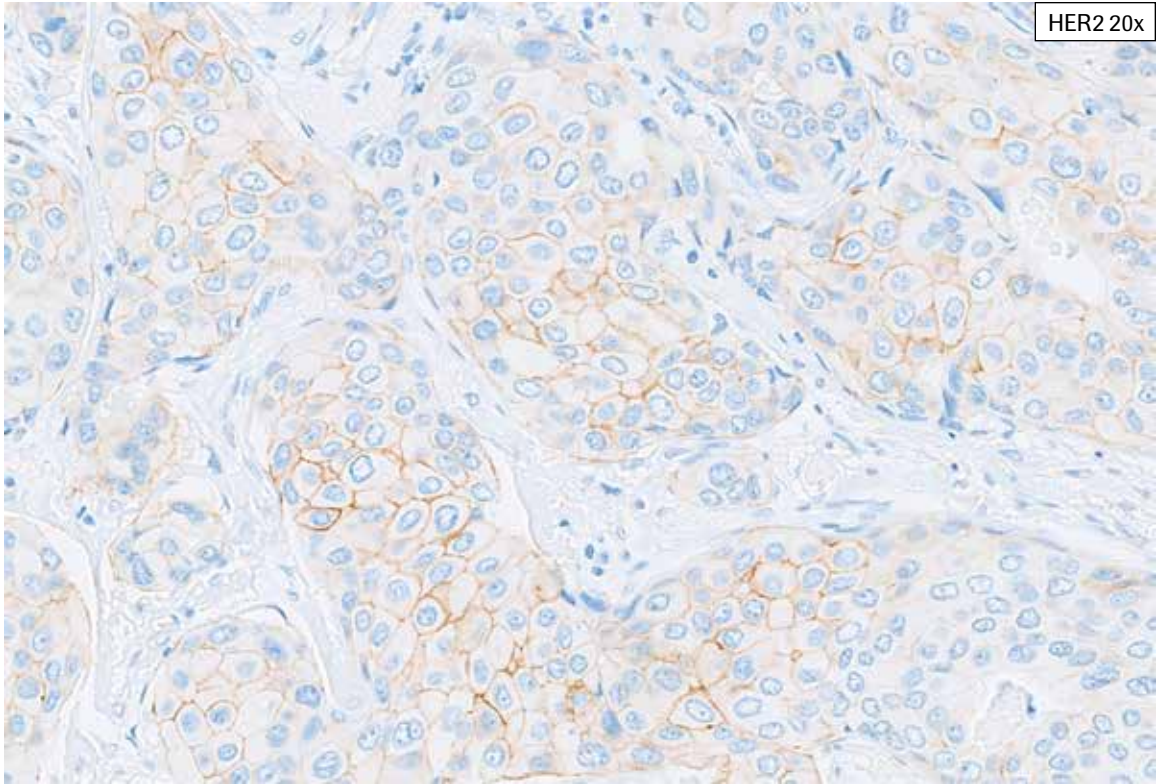


**HER2 IHC Score 1+, Case 5:** This case shows heterogeneity in HER2 membrane staining and variable cytoplasmic blush. Partial faint, weak or moderate membrane staining is present in 35% of tumor cells (HER2 IHC Score 1+). Variable cytoplasmic blush makes discernment of faint to weak membrane staining difficult. Examination at up to 40x magnification is required to include all faint to weak membrane staining in HER2 scoring.

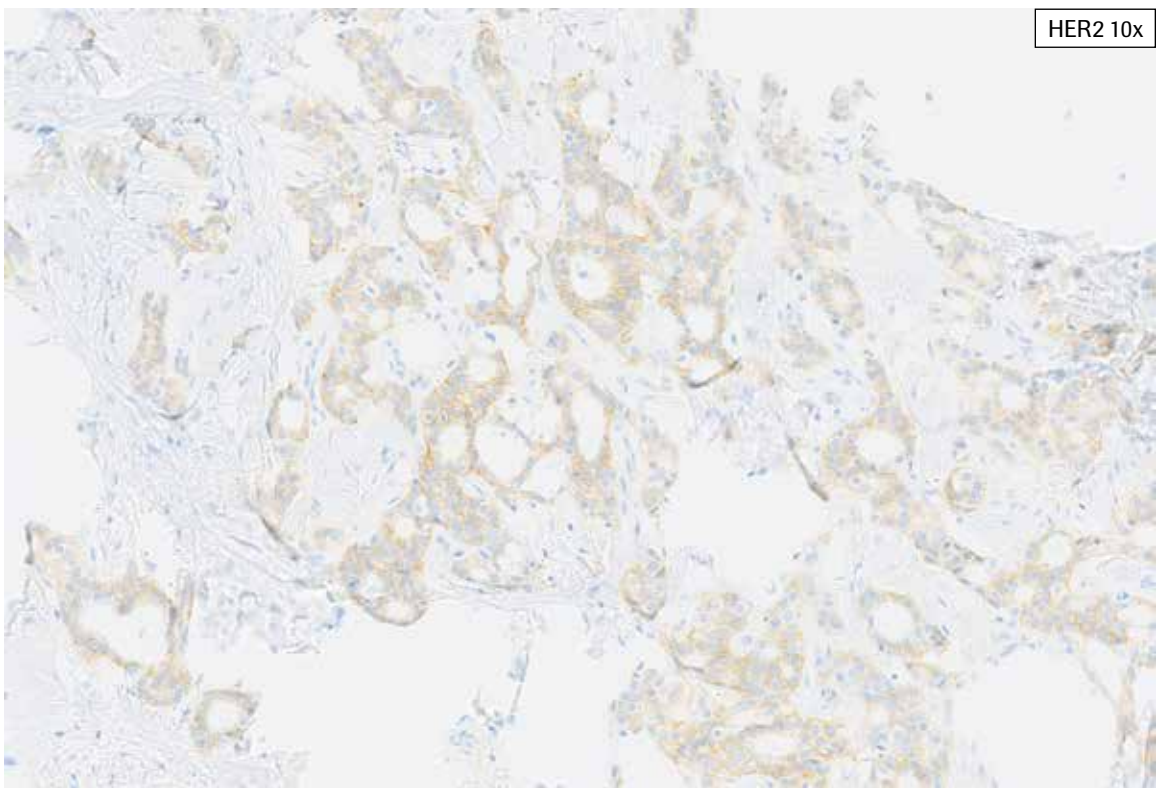
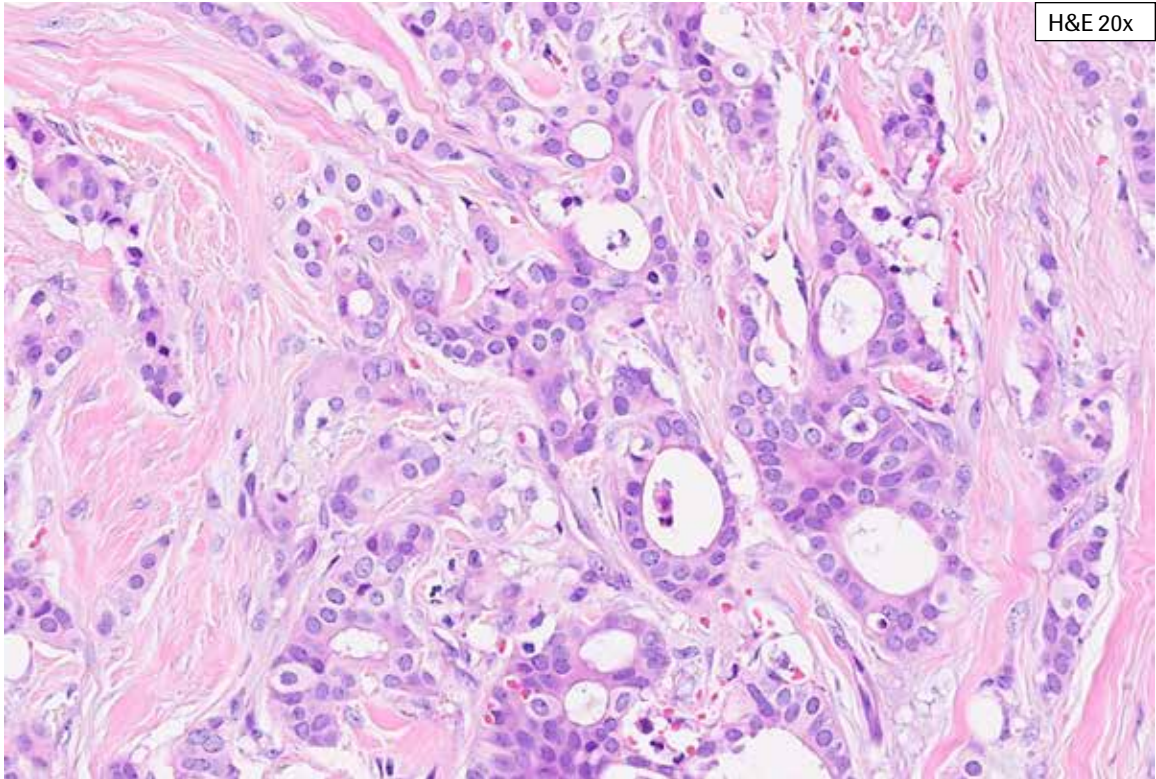
## PATHWAY anti-HER-2/neu Rabbit Monoclonal Antibody Staining in Breast Cancer: IHC Score 2+



**HER2 IHC Score 2+, Case 1:** This case shows complete, moderate HER2 membrane staining at 10x. Examination at higher magnification reveals weak to moderate complete membrane staining. This case is challenging in that overall, the viable tumor demonstrated 15% complete, weak to moderate membrane staining (HER2 IHC Score 2+) and was therefore extremely close to the >10% cutoff. Partial, faint to weak membrane staining is also focally present.

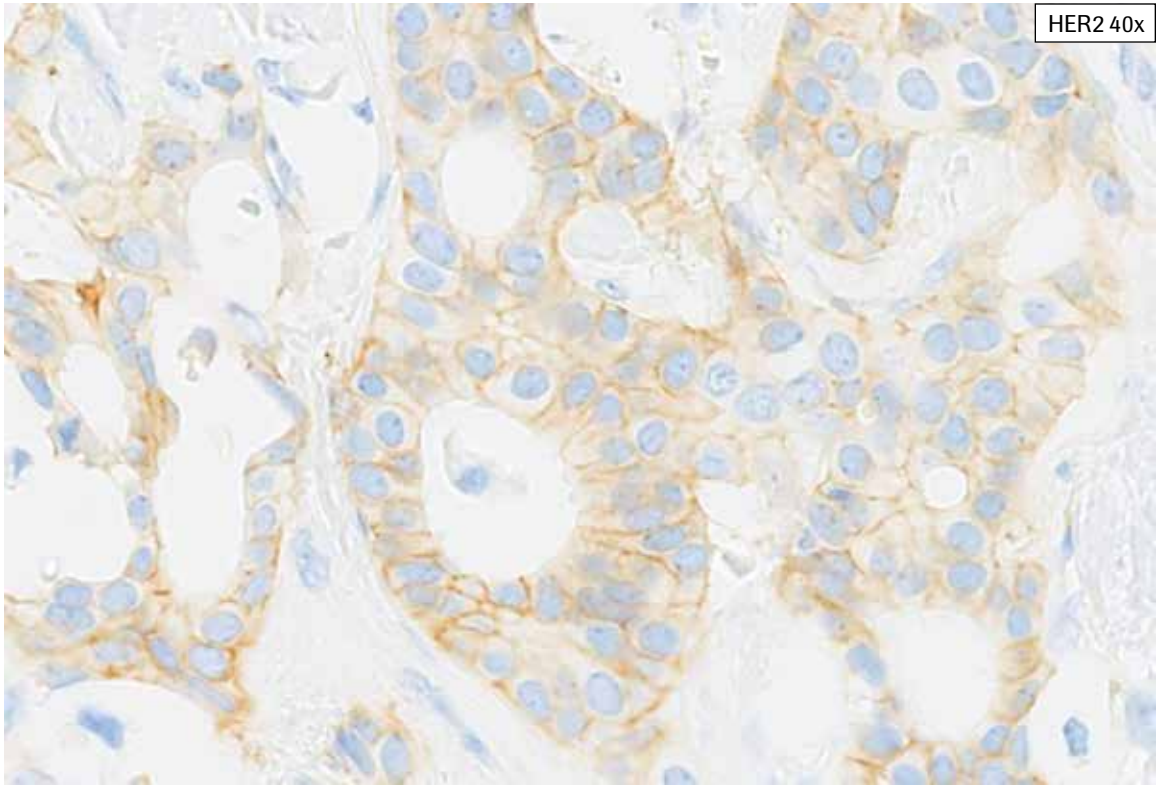
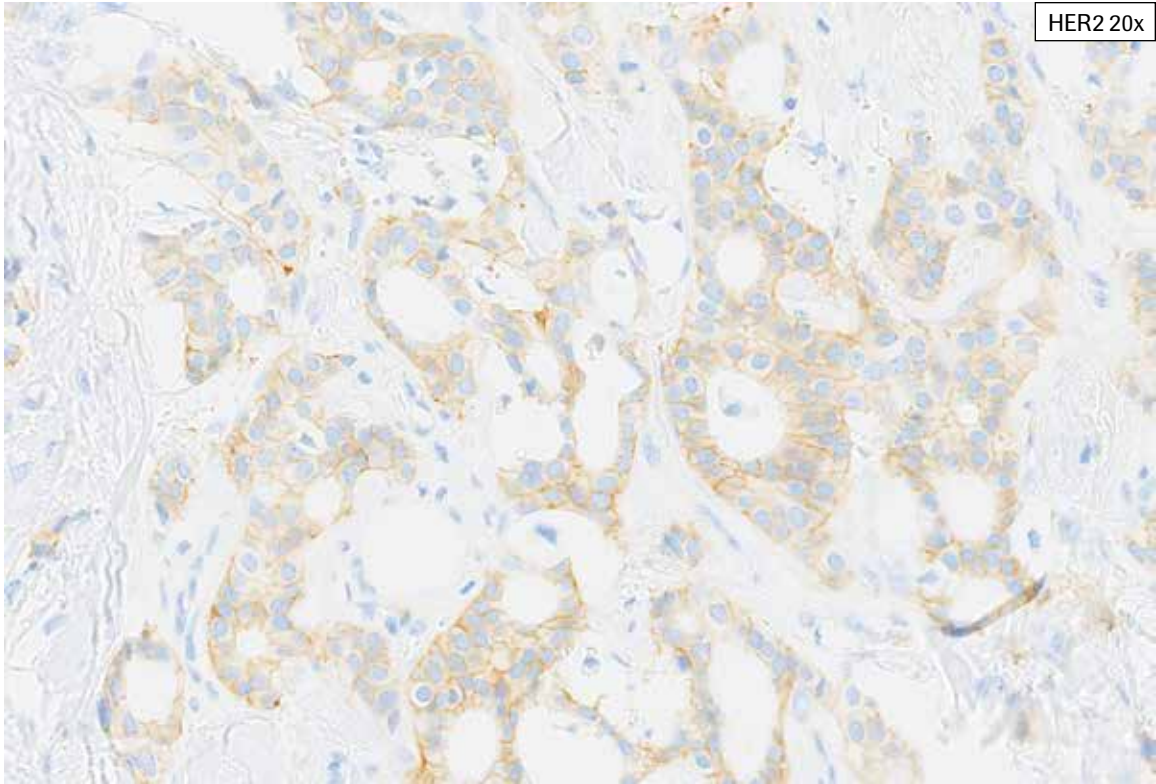


**HER2 IHC Score 2+, Case 1:** This case shows complete, moderate HER2 membrane staining at 10x. Examination at higher magnification reveals weak to moderate complete membrane staining. This case is challenging in that overall, the viable tumor demonstrated 15% complete, weak to moderate membrane staining (HER2 IHC Score 2+) and was therefore extremely close to the >10% cutoff. Partial, faint to weak membrane staining is also focally present.

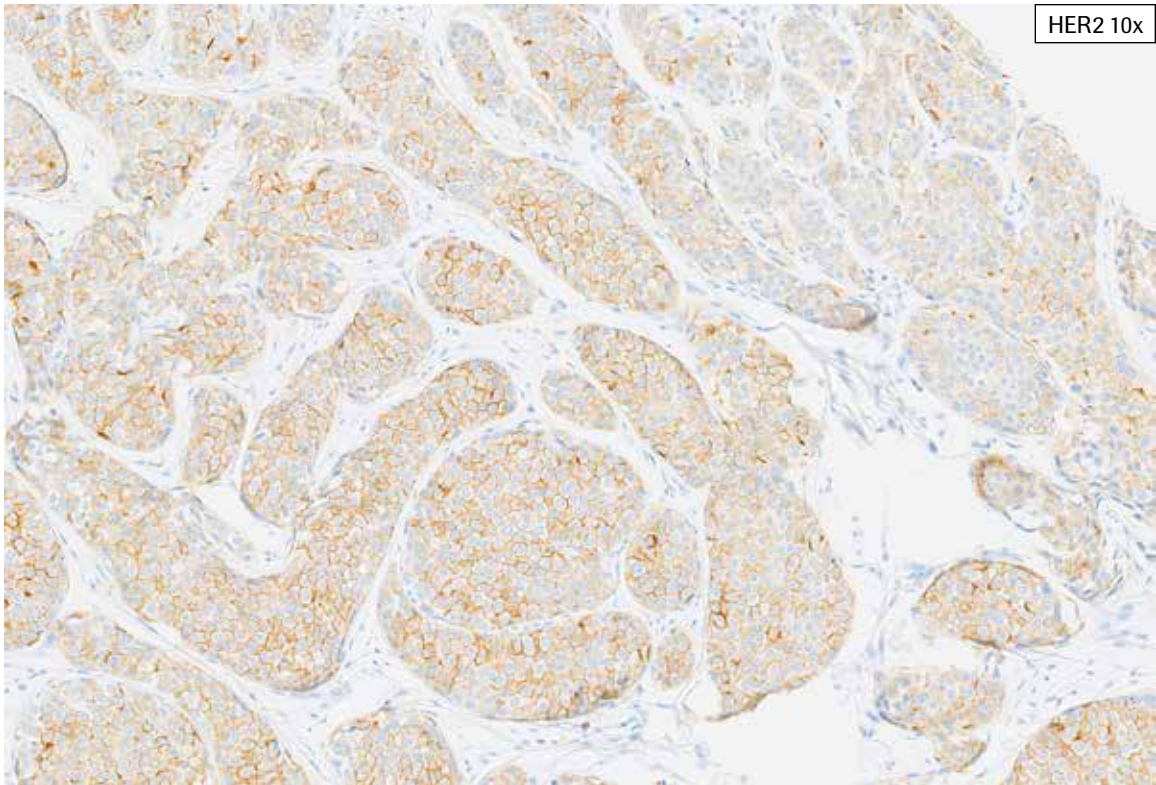
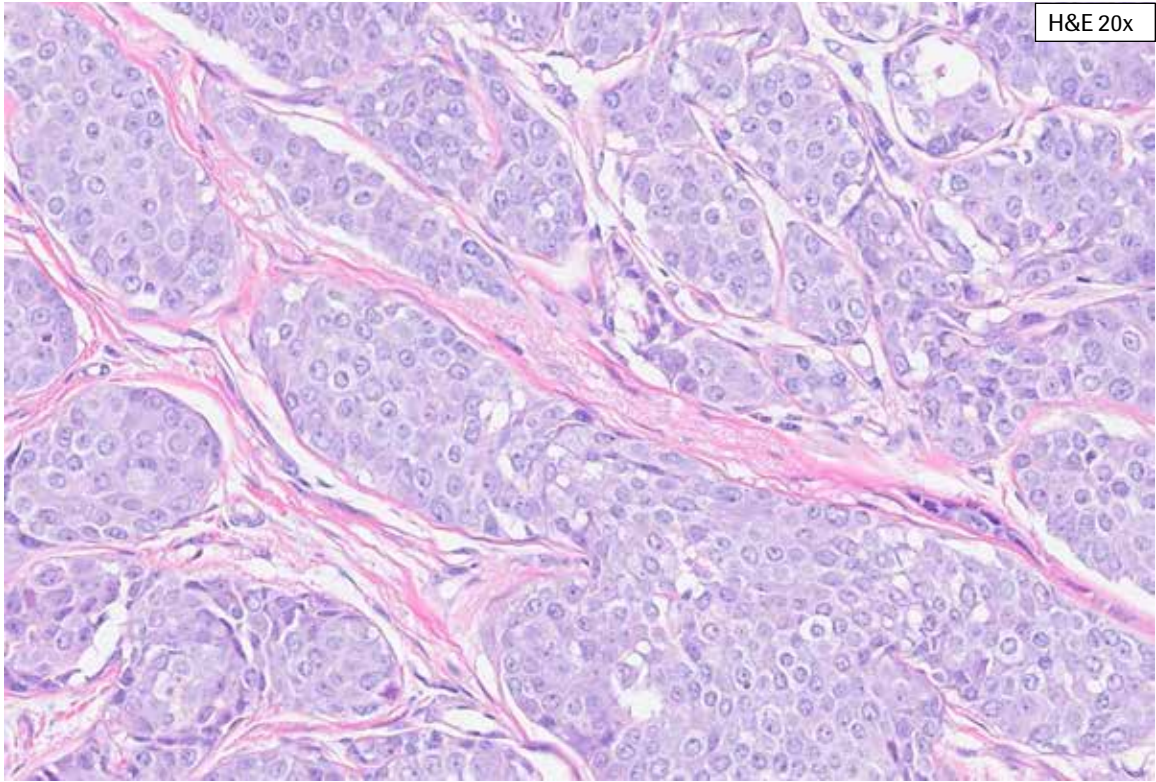


**HER2 IHC Score 2+, Case 2:** In this case, scattered gland formation is present within the tumor. At 10x, cytoplasmic bluish and focal membrane staining is noted. With progressively higher magnification, complete weak to moderate membrane staining is seen. This case is challenging with cytoplasmic bluish and 20% overall 2+ membrane staining (HER2 IHC Score 2+) of viable tumor.

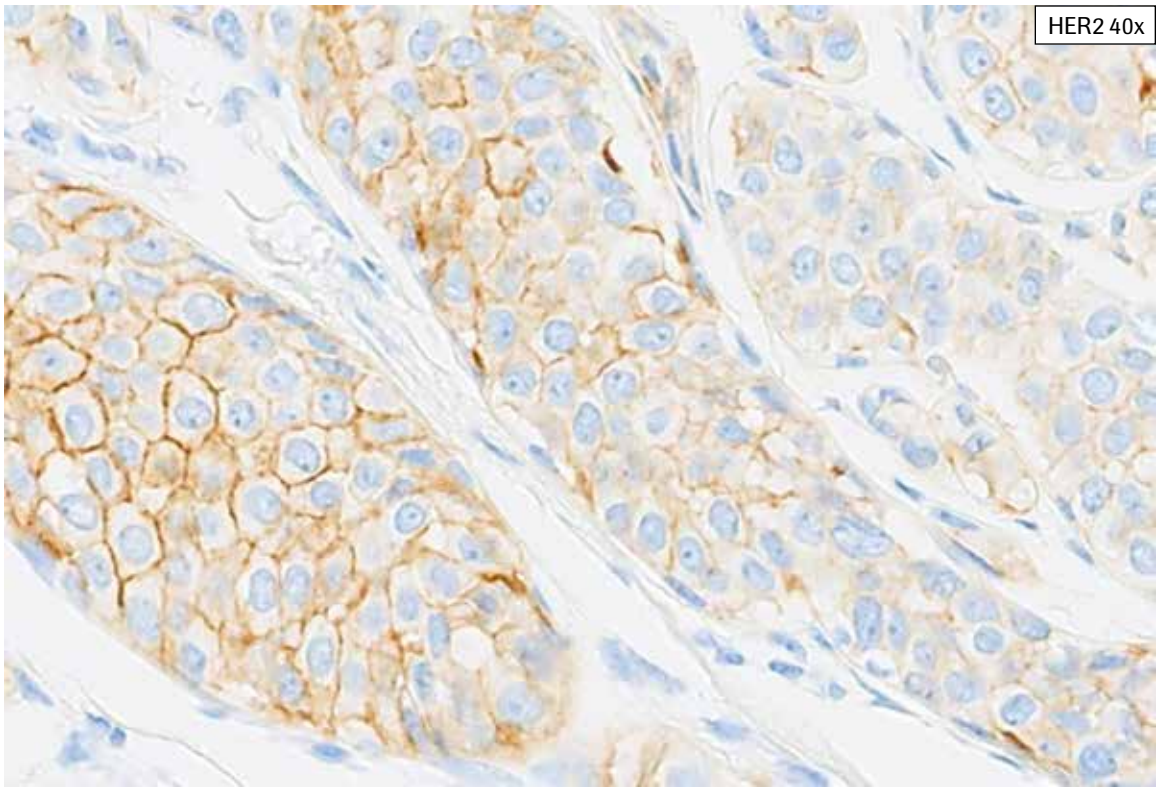
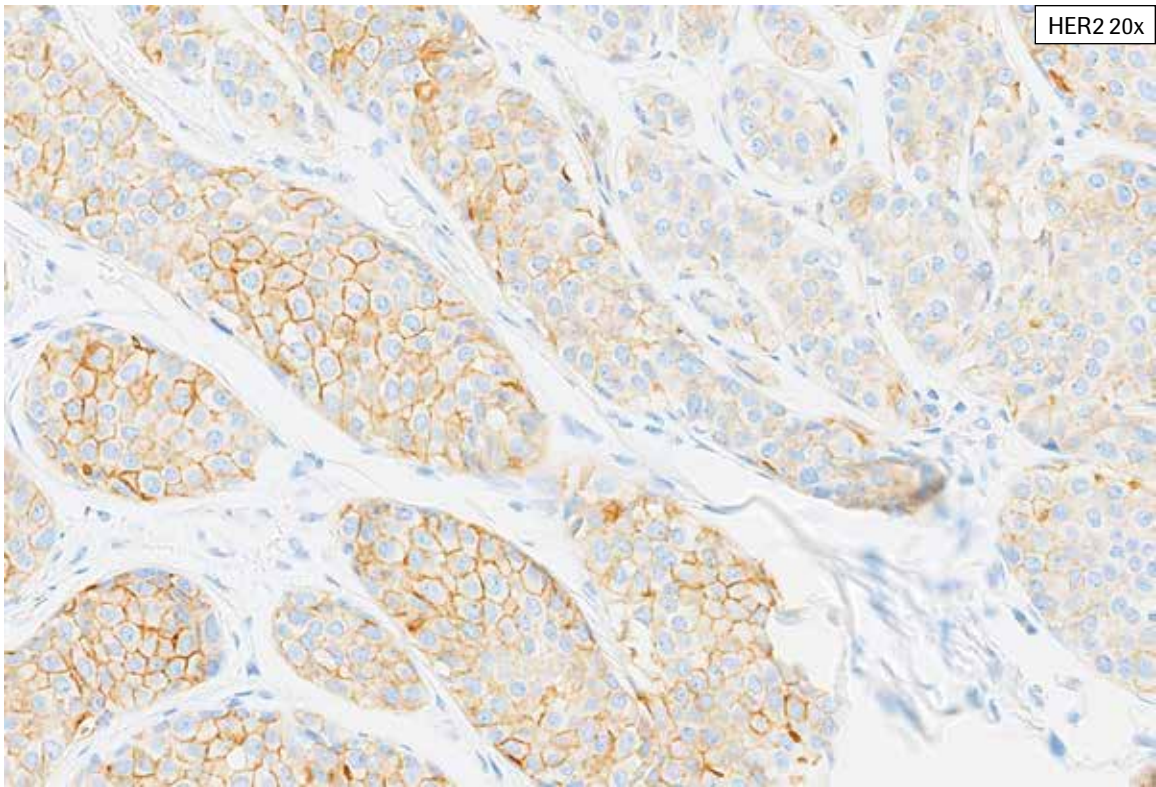




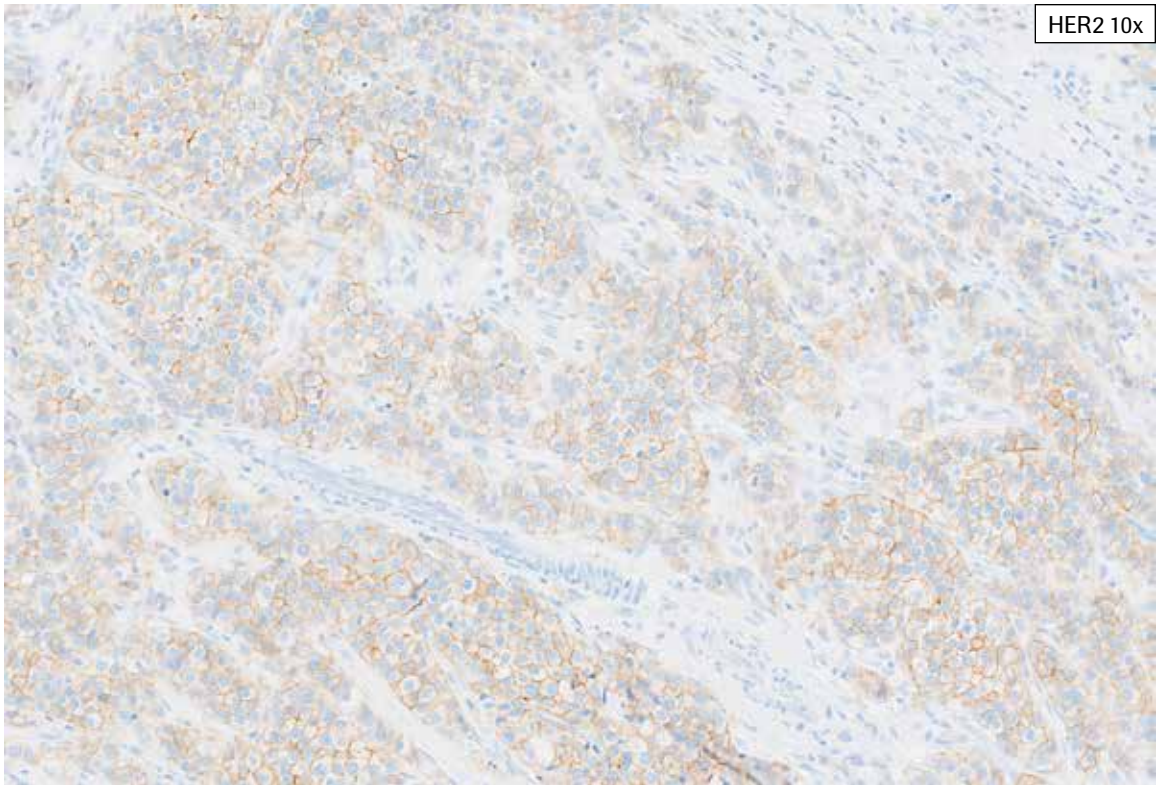
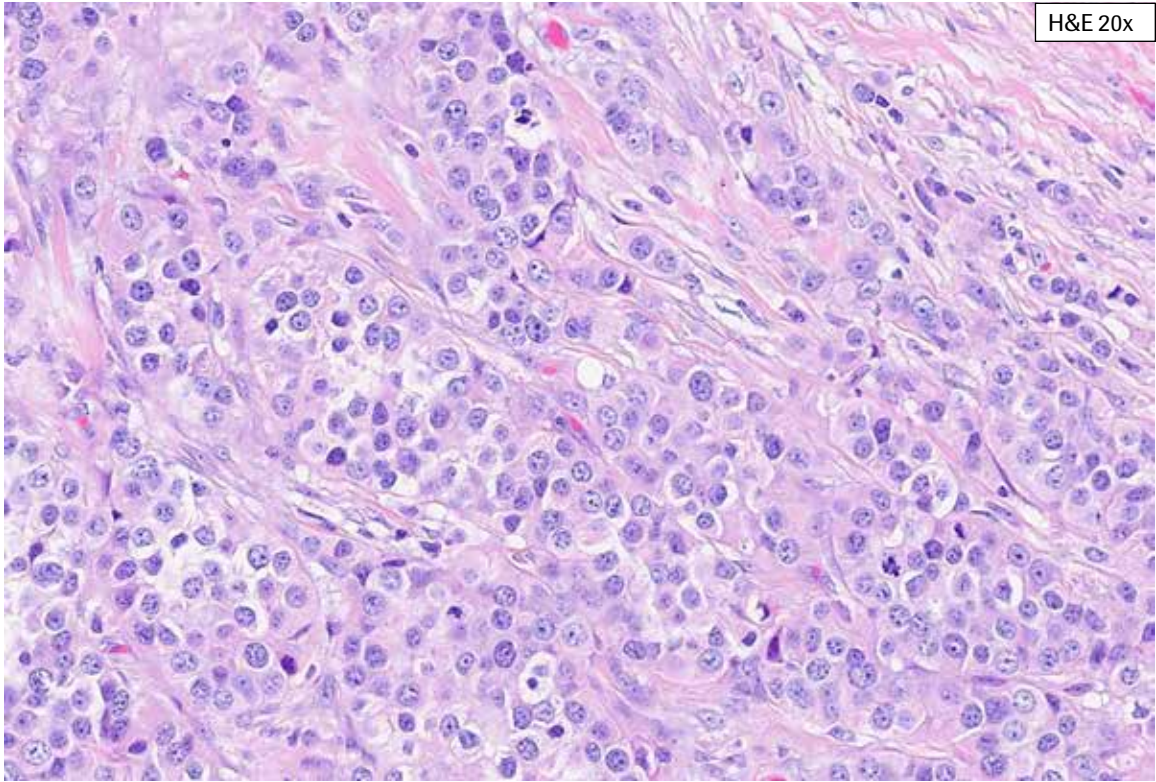
**HER2 IHC Score 2+, Case 2:** In this case, scattered gland formation is present within the tumor. At 10x, cytoplasmic blush and focal membrane staining is noted. With progressively higher magnification, complete weak to moderate membrane staining is seen. This case is challenging with cytoplasmic blush and 20% overall 2+ membrane staining (HER2 IHC Score 2+) of viable tumor.



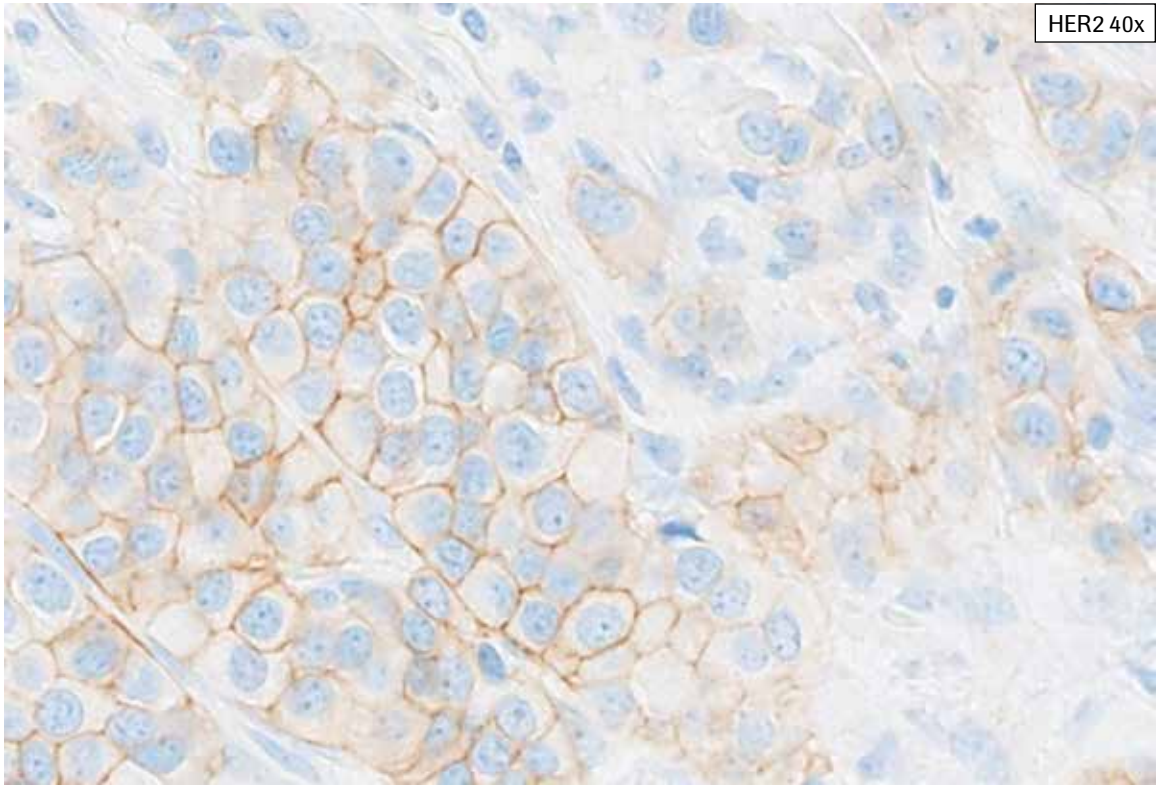
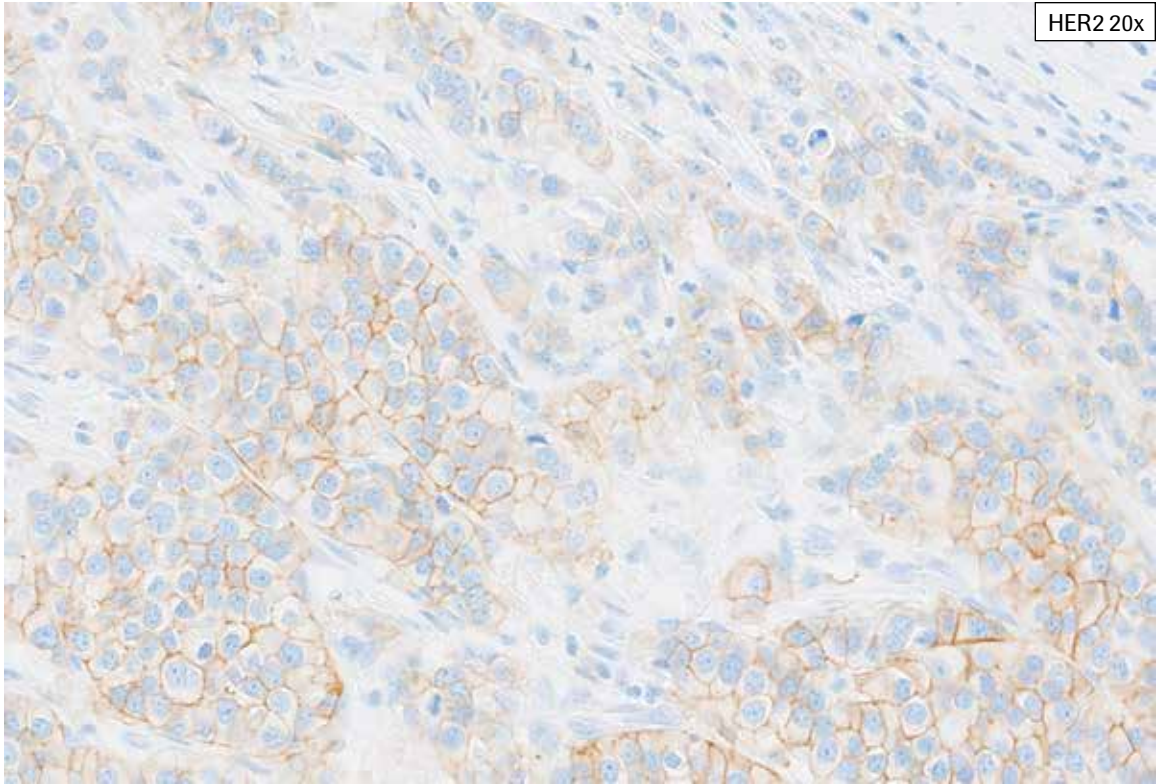
**HER2 IHC Score 2+, Case 3:** This case shows abundant invasive tumor. From 10x, moderate complete membrane staining can be seen. Also, variability in the intensity of tumor cell membrane staining and cytoplasmic blush is noted. At progressively higher magnification, more faint to weak membrane staining is appreciated. This case shows 40% complete membrane staining overall and was scored as HER2 IHC Score 2+.



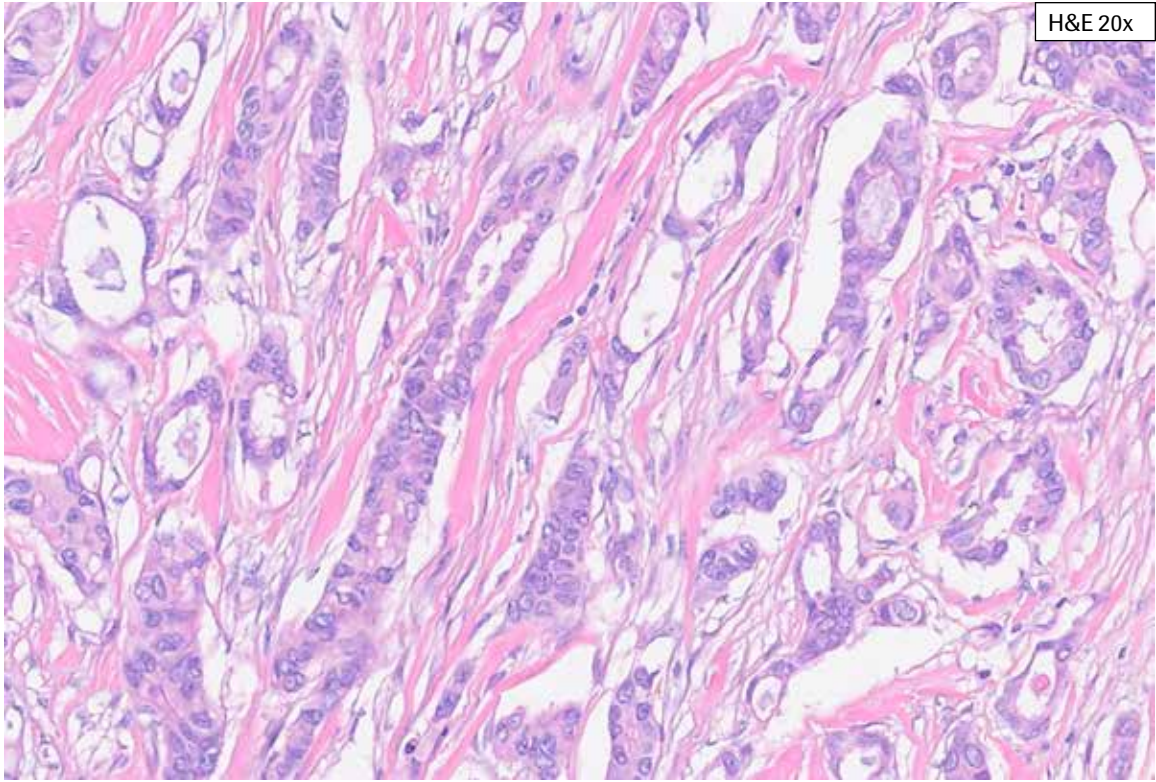
**HER2 IHC Score 2+, Case 3:** This case shows abundant invasive tumor. From 10x, moderate complete membrane staining can be seen. Also, variability in the intensity of tumor cell membrane staining and cytoplasmic blush is noted. At progressively higher magnification, more faint to weak membrane staining is appreciated. This case shows 40% complete membrane staining overall and was scored as HER2 IHC Score 2+.



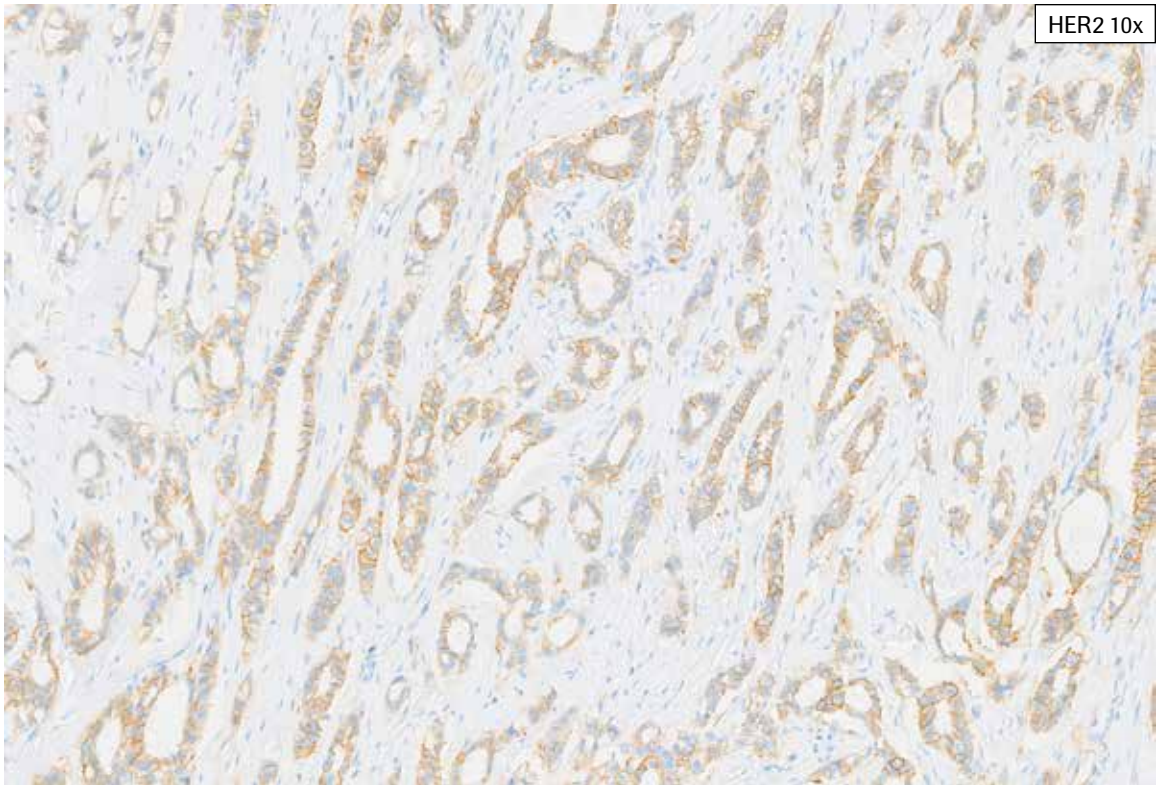
**HER2 IHC Score 2+, Case 4:** In this case, moderate complete membrane staining is seen at 10x. At higher magnification, weak complete and weak partial membrane staining is also noted. This case shows 50% complete membrane staining overall and was scored as HER2 IHC Score 2+.



**HER2 IHC Score 2+, Case 4:** In this case, moderate complete membrane staining is seen at 10x. At higher magnification, weak complete and weak partial membrane staining is also noted. This case shows 50% complete membrane staining overall and was scored as HER2 IHC Score 2+.

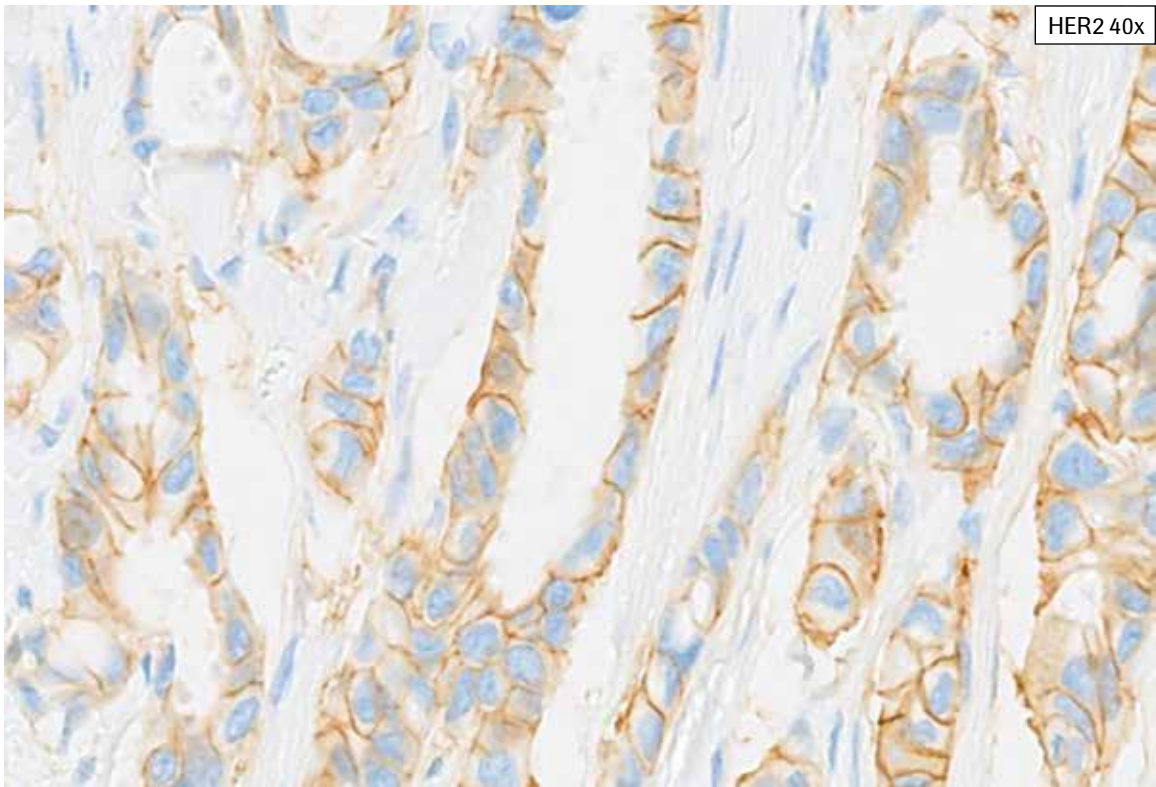
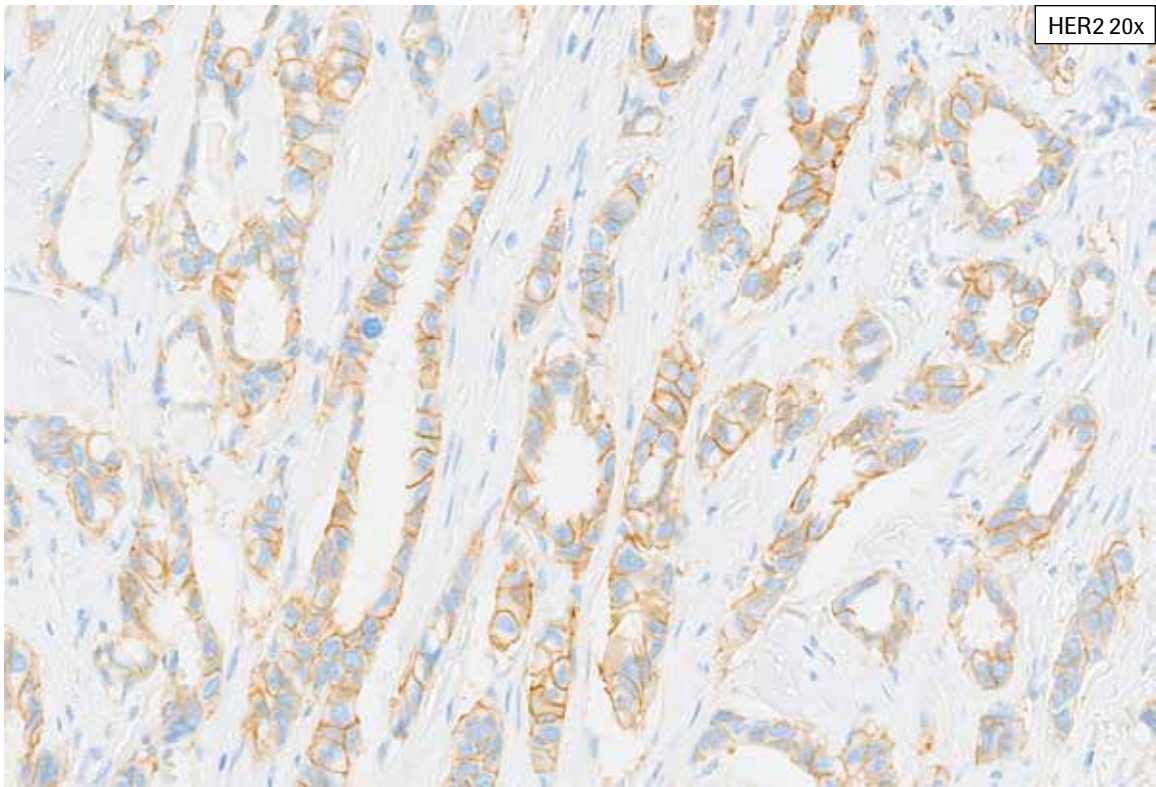


H&E 20x


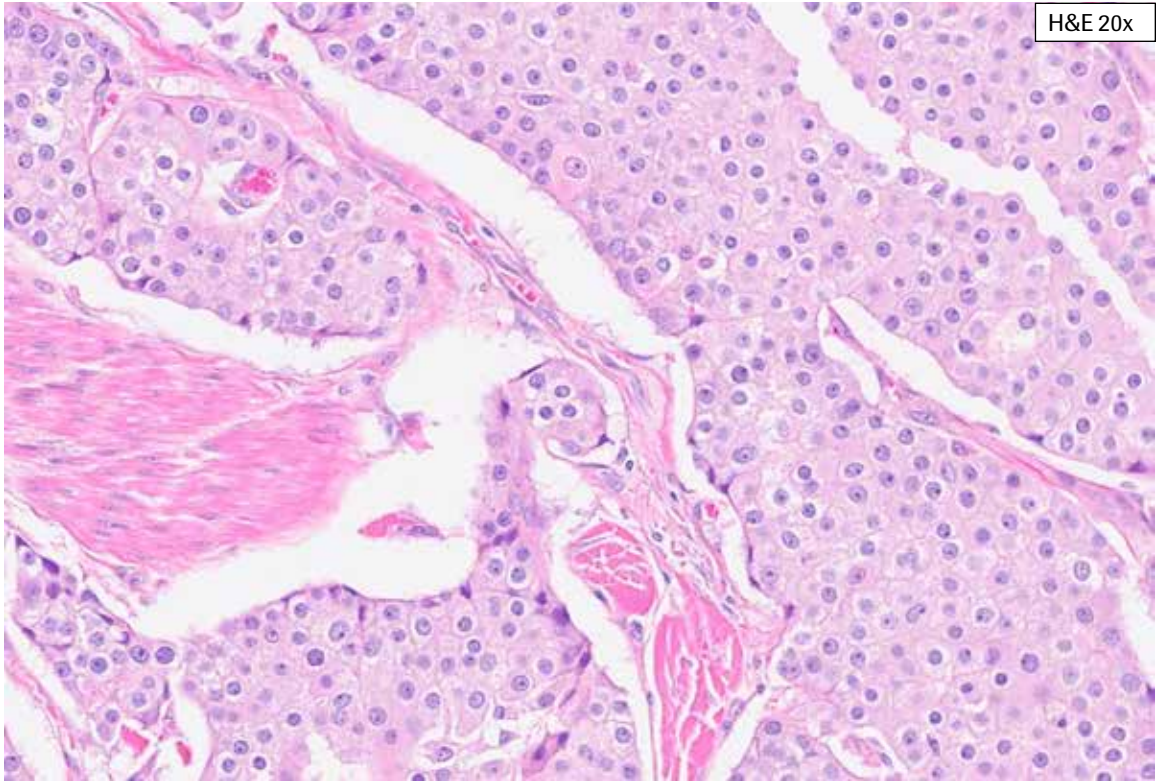


HER2 10x

**HER2 IHC Score 2+, Case 5:** Some complete, moderate staining is seen in this biopsy case at 10x. However, examination at higher magnification is required to discern the predominant complete, weak membrane staining. Partial, faint HER2 membrane staining and cytoplasmic blush are present. This case showed complete, weak to moderate membrane staining in 65% of the viable tumor cells (HER2 IHC Score 2+).

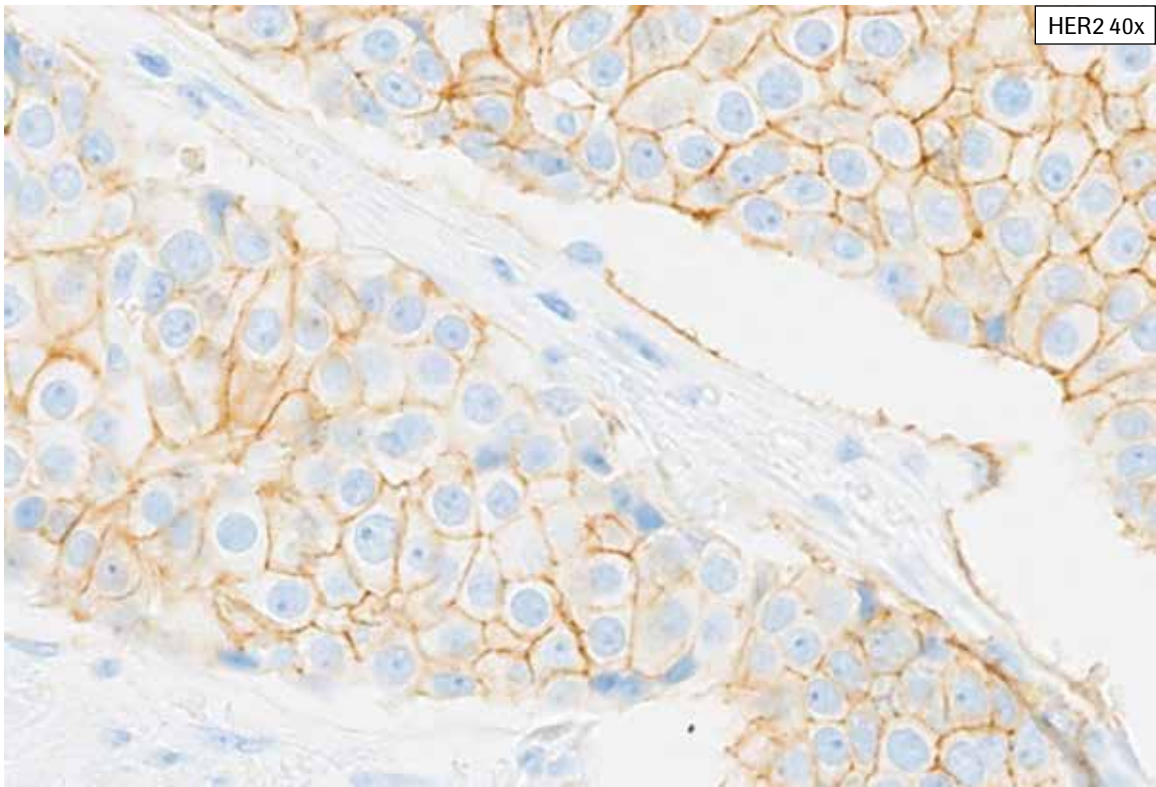
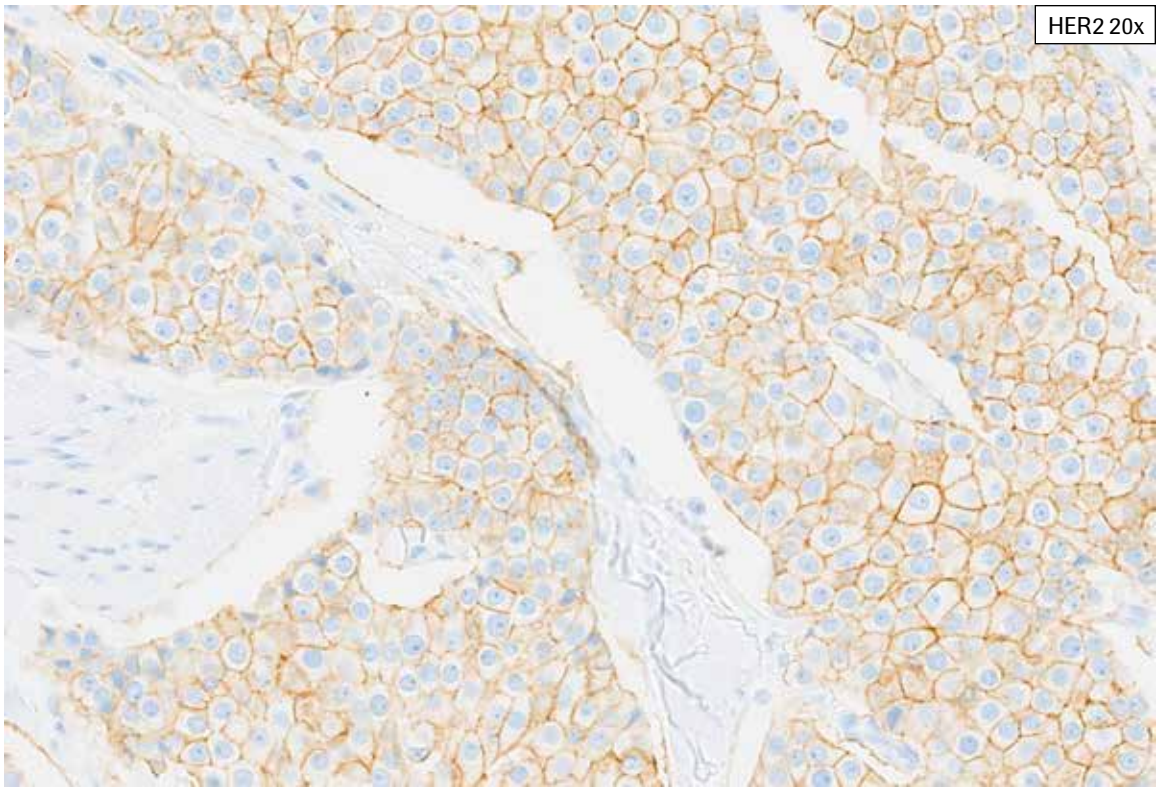


**HER2 IHC Score 2+, Case 5:** Some complete, moderate staining is seen in this biopsy case at 10x. However, examination at higher magnification is required to discern the predominant complete, weak membrane staining. Partial, faint HER2 membrane staining and cytoplasmic blush are present. This case showed complete, weak to moderate membrane staining in 65% of the viable tumor cells (HER2 IHC Score 2+).



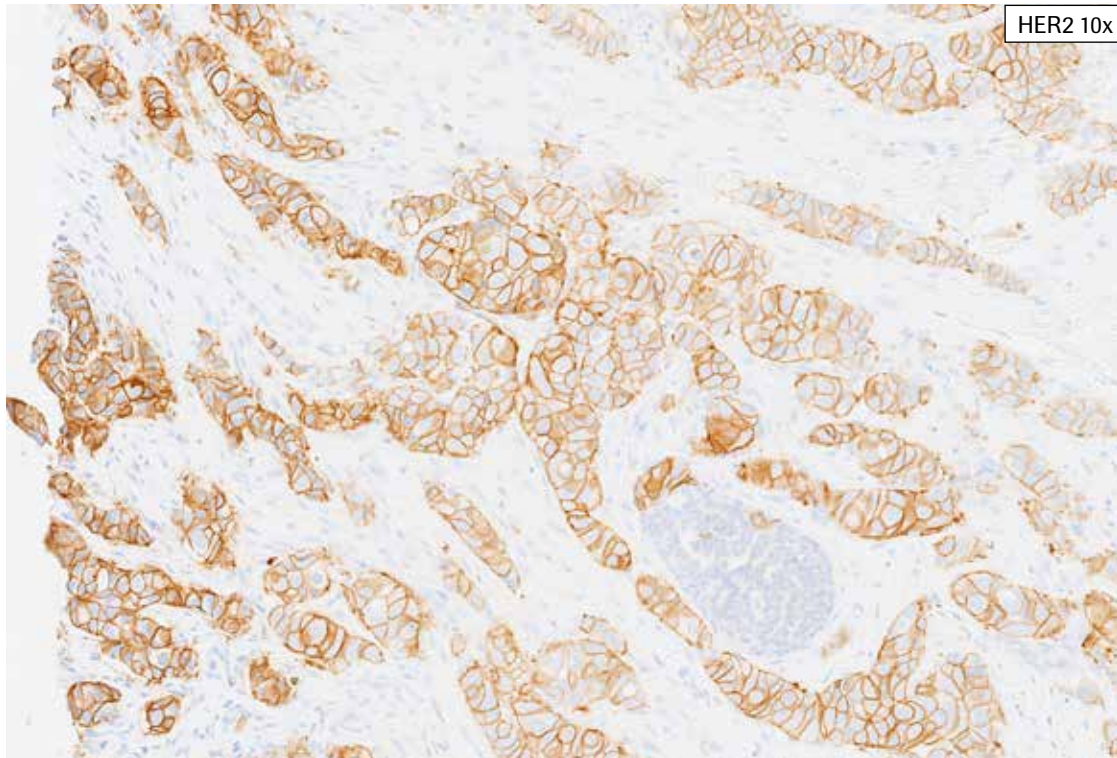
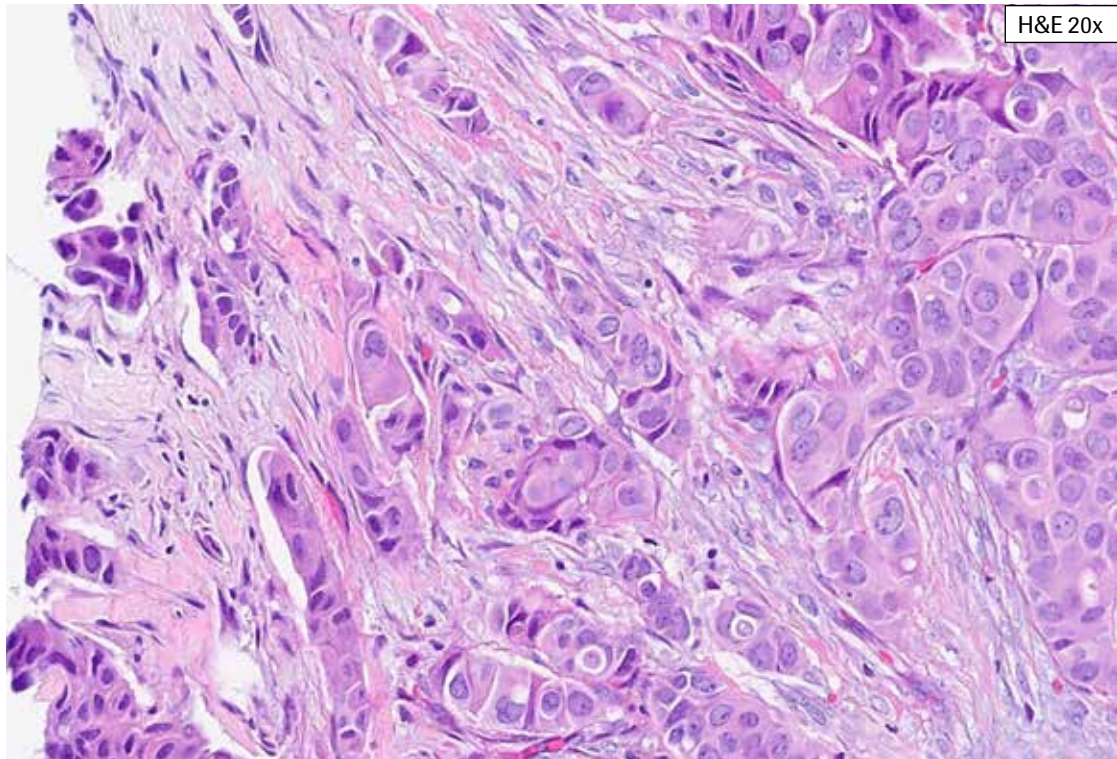
**HER2 IHC Score 2+, Case 6:** Complete, moderate membrane staining is visible at 10x. Examination at higher magnification reveals complete, weak membrane staining as well as weak to moderate partial membrane staining. Tumor cells showing only ring-like weak to moderate staining should be included in HER2 2+ scoring. This tissue overall showed 75% complete, weak to moderate membrane staining (HER2 IHC Score 2+).



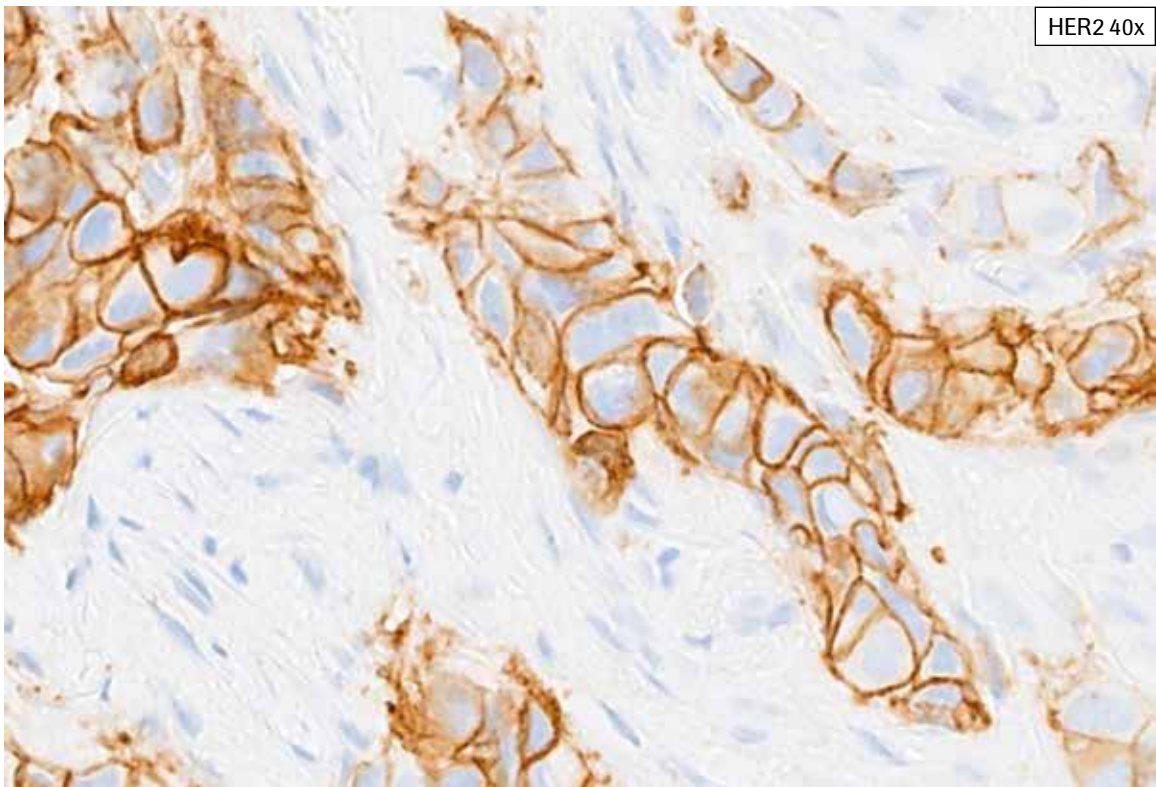
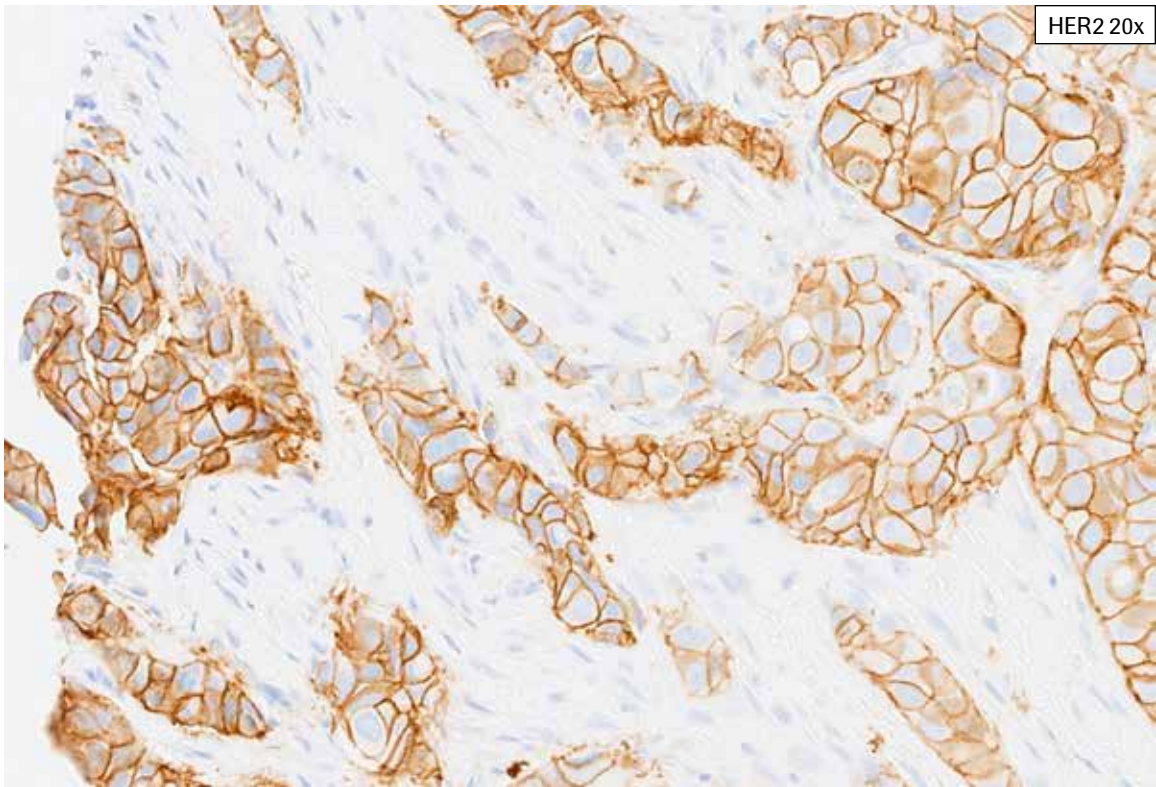


**HER2 IHC Score 2+, Case 6:** Complete, moderate membrane staining is visible at 10x. Examination at higher magnification reveals complete, weak membrane staining as well as weak to moderate partial membrane staining. Tumor cells showing only ring-like weak to moderate staining should be included in HER2 2+ scoring. This tissue overall showed 75% complete, weak to moderate membrane staining (HER2 IHC Score 2+).

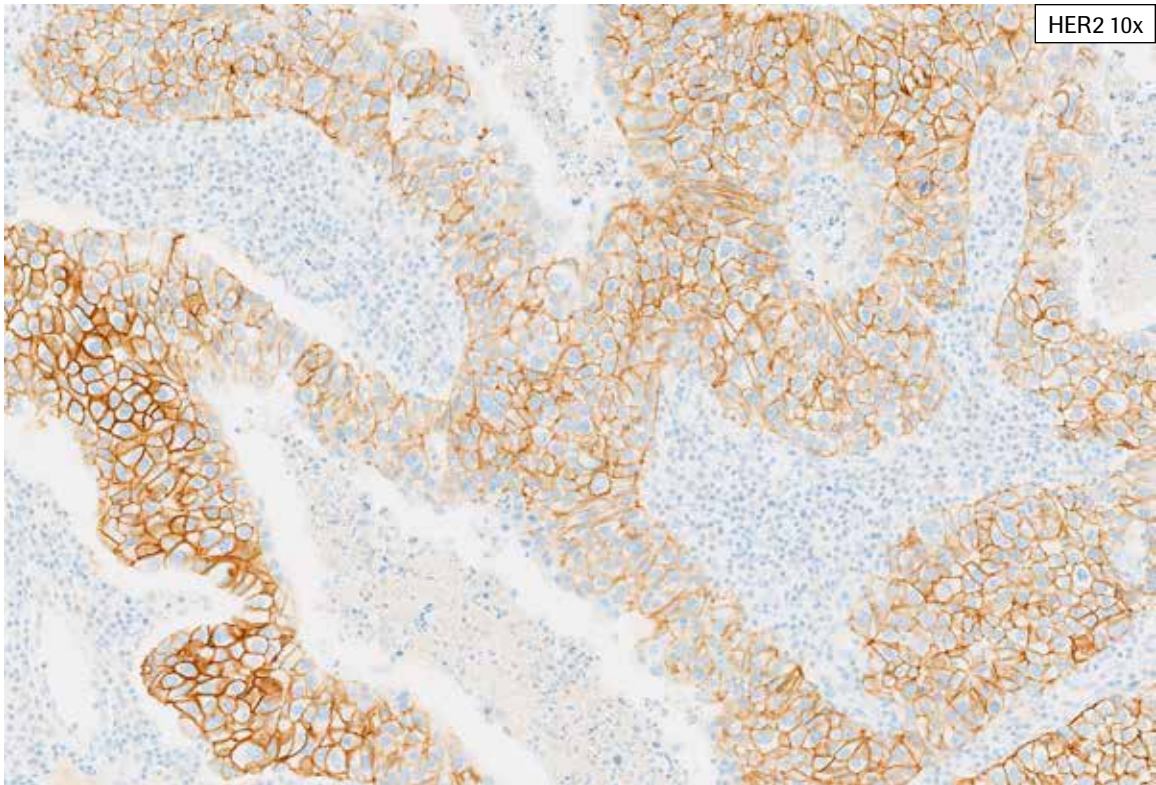
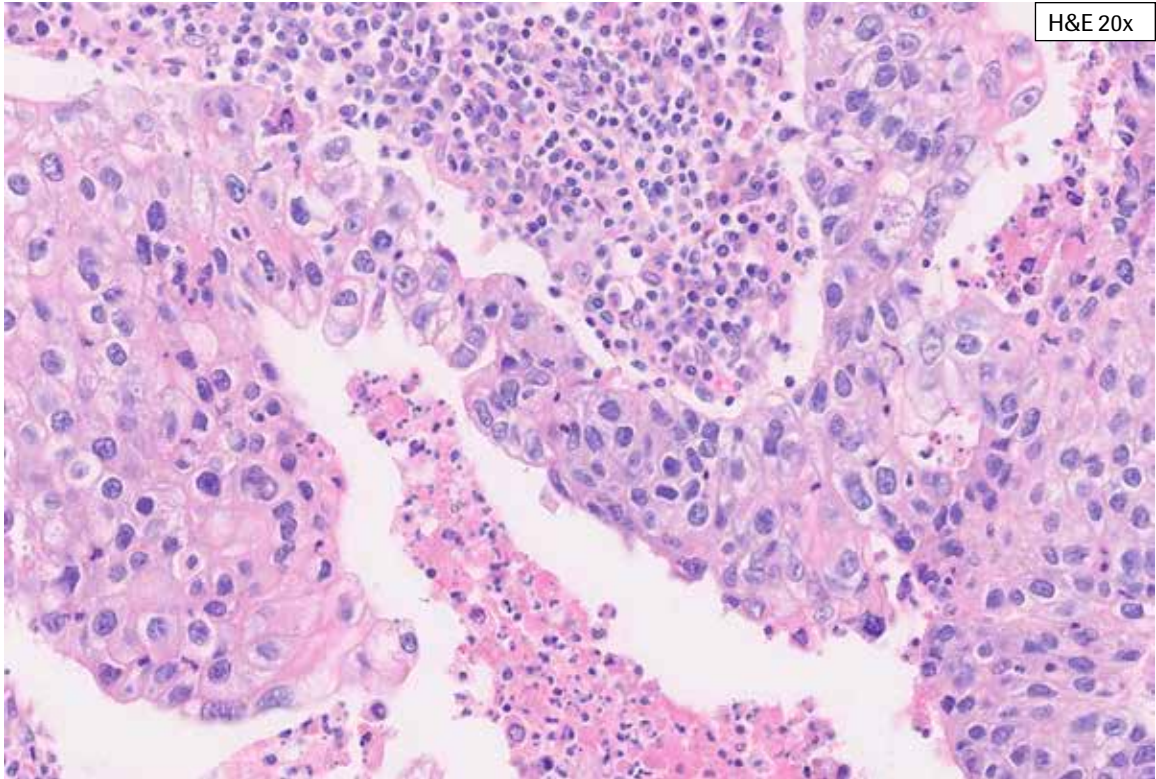
## PATHWAY anti-HER-2/neu Rabbit Monoclonal Antibody Staining in Breast Cancer: IHC Score 3+



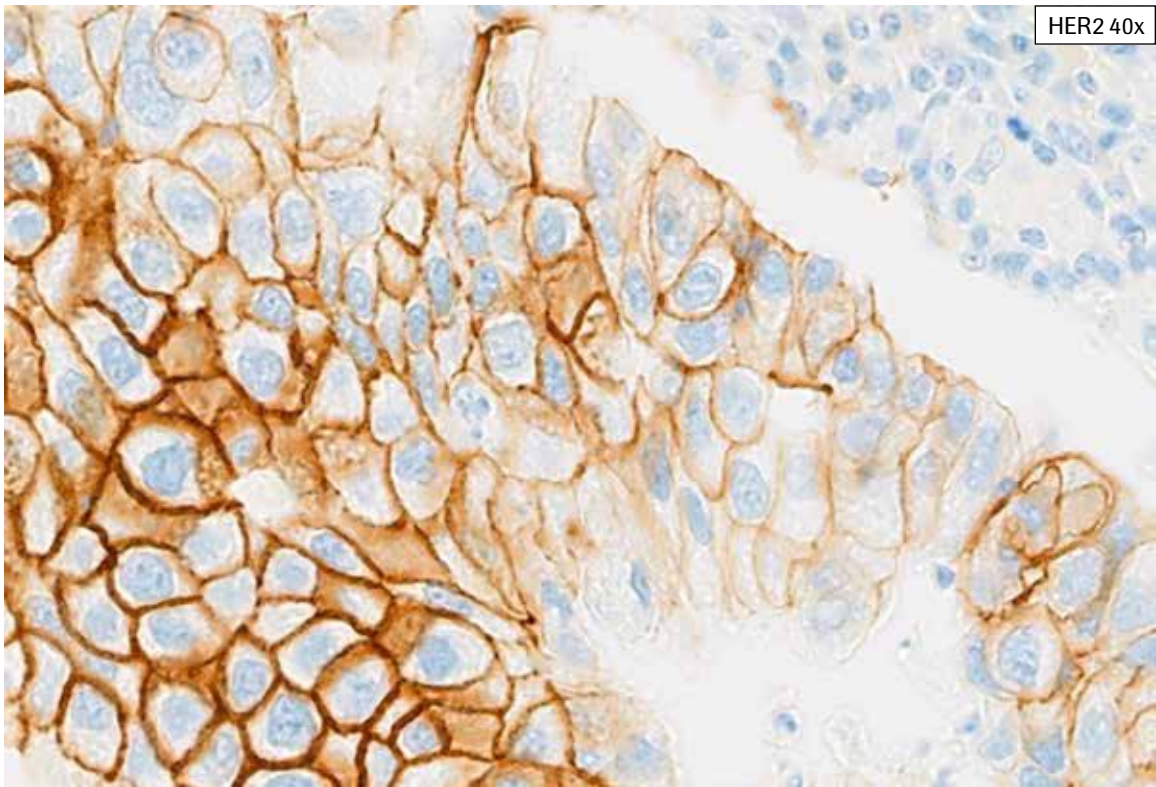
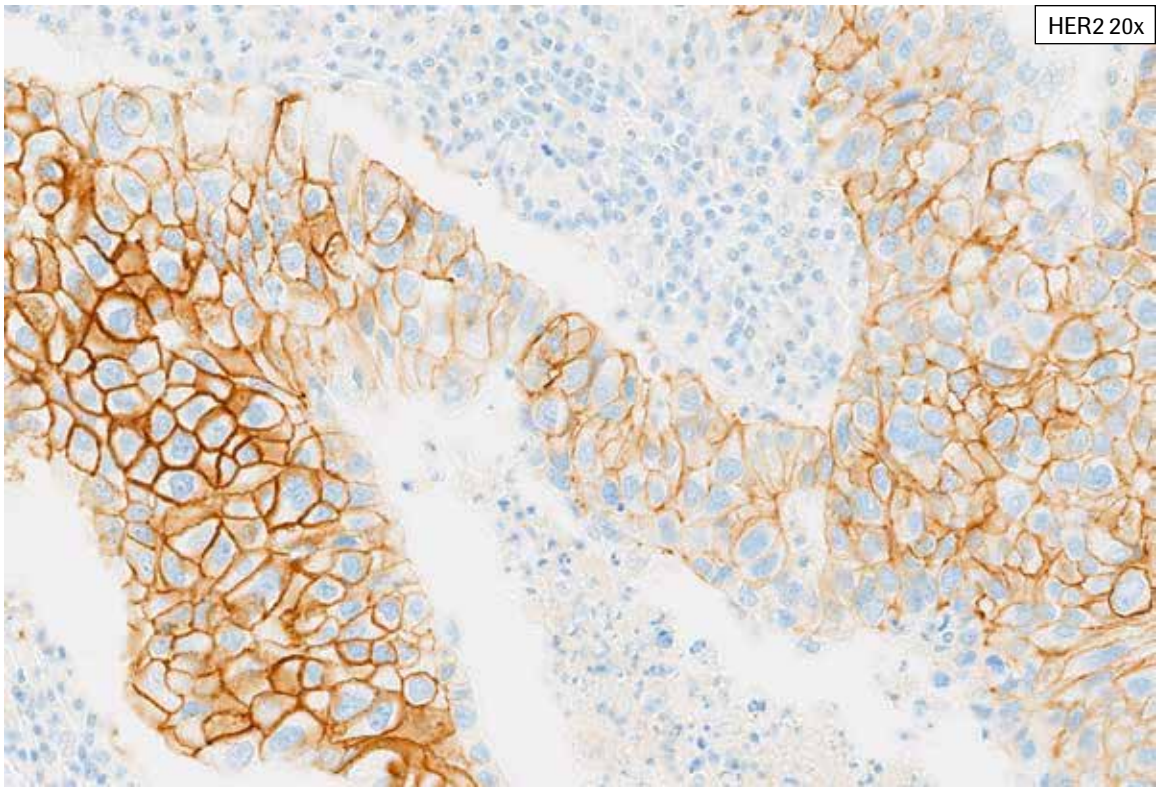
**HER2 IHC Score 3+, Case 1:** Invasive tumor as well a focus of DCIS is seen. Moderate to strong complete membrane staining and cytoplasmic staining are present. Minimal acceptable background staining is noted. This case is challenging in that the 3+ staining represents 15% of the viable tumor (HER2 IHC Score 3+), close to the 3+ cutoff.



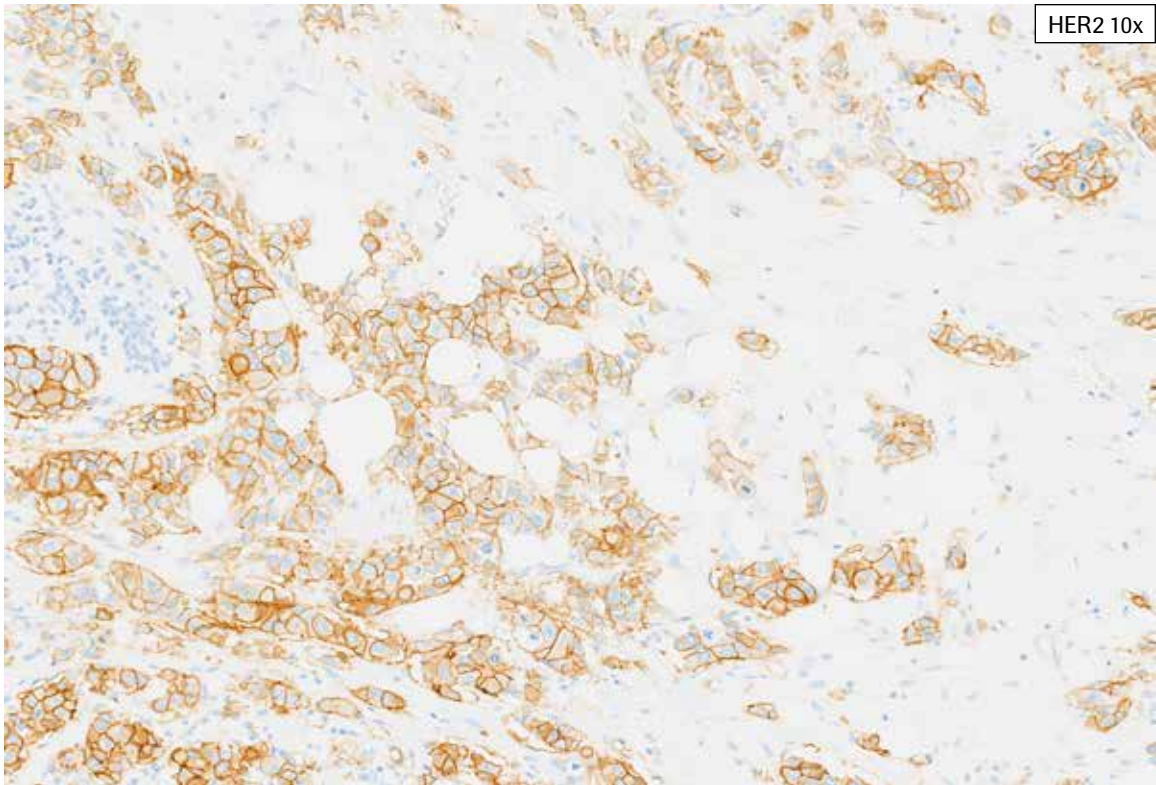
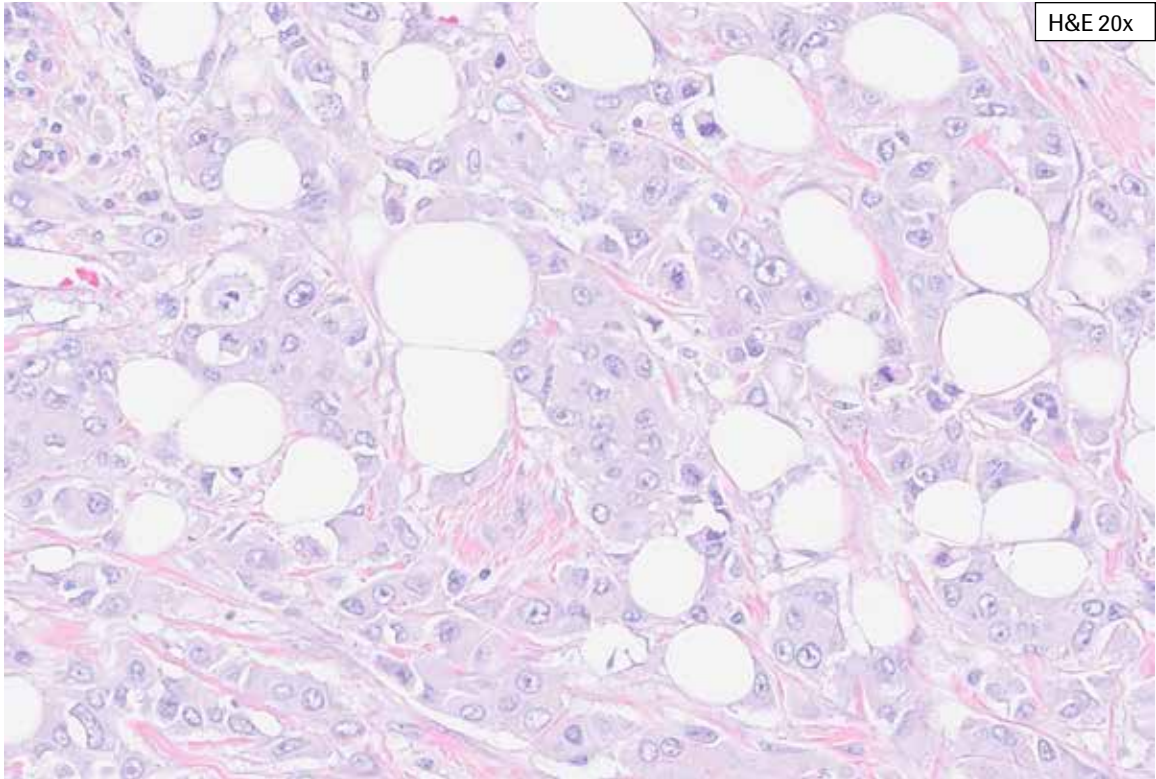
**HER2 IHC Score 3+, Case 1:** Invasive tumor as well a focus of DCIS is seen. Moderate to strong complete membrane staining and cytoplasmic staining are present. Minimal acceptable background staining is noted. This case is challenging in that the 3+ staining represents 15% of the viable tumor (HER2 IHC Score 3+), close to the 3+ cutoff.



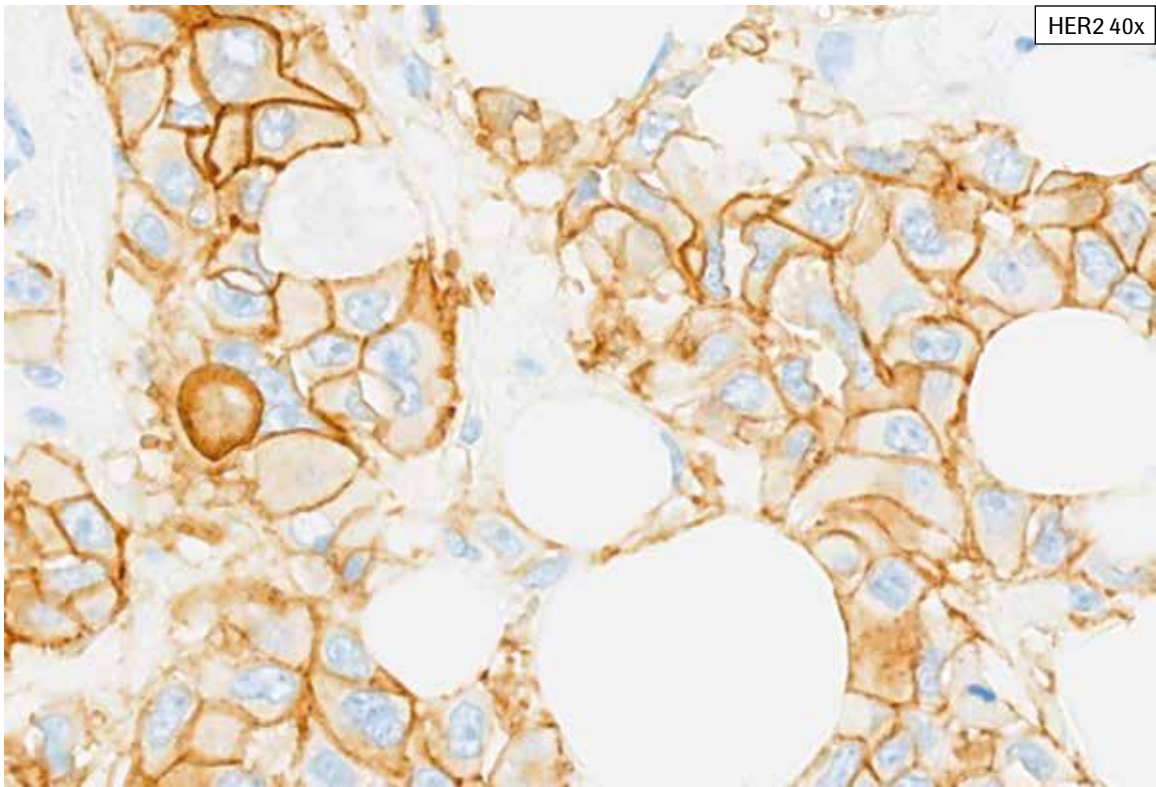
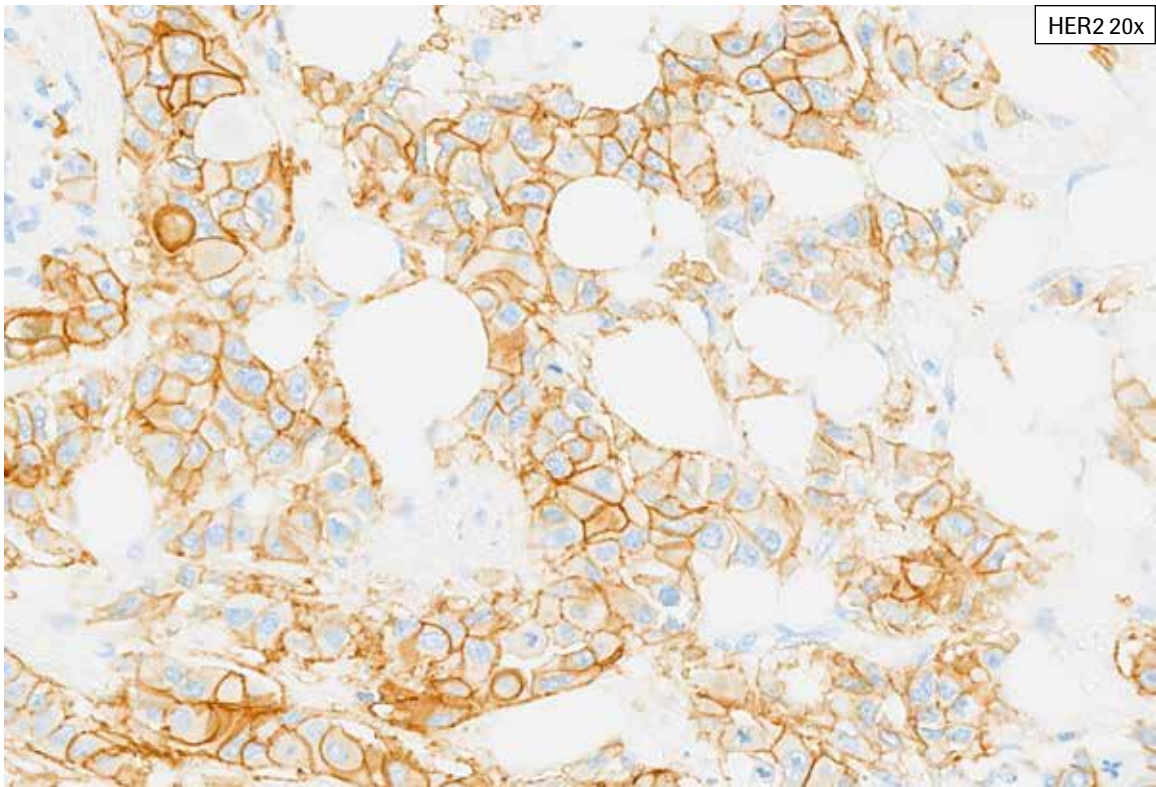
**HER2 IHC Score 3+, Case 2:** This case shows tumor with abundant necrosis. The HER2 staining is heterogeneous with weak to moderate to strong membrane staining. The majority of complete membrane staining is weak to moderate, however, 20% of the viable tumor cells showed complete, intense membrane staining. This case was scored as HER2 IHC 3+.



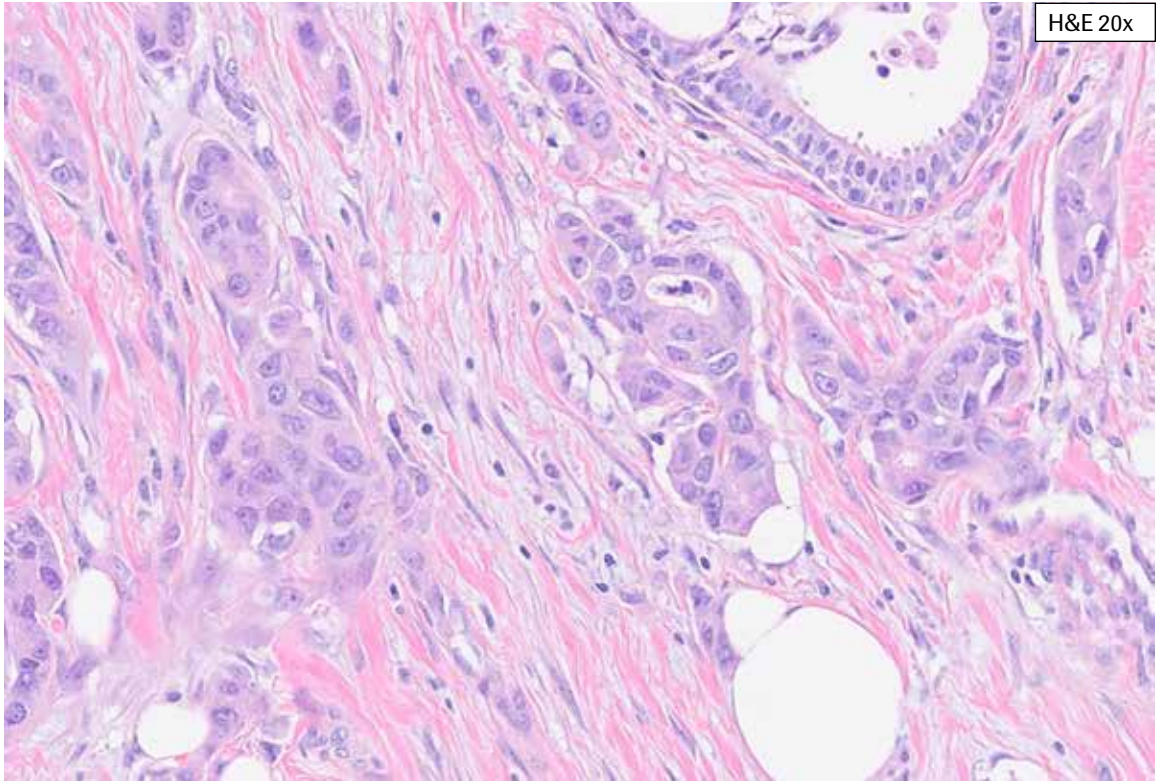
**HER2 IHC Score 3+, Case 2:** This case shows tumor with abundant necrosis. The HER2 staining is heterogeneous with weak to moderate to strong membrane staining. The majority of complete membrane staining is weak to moderate, however, 20% of the viable tumor cells showed complete, intense membrane staining. This case was scored as HER2 IHC 3+.



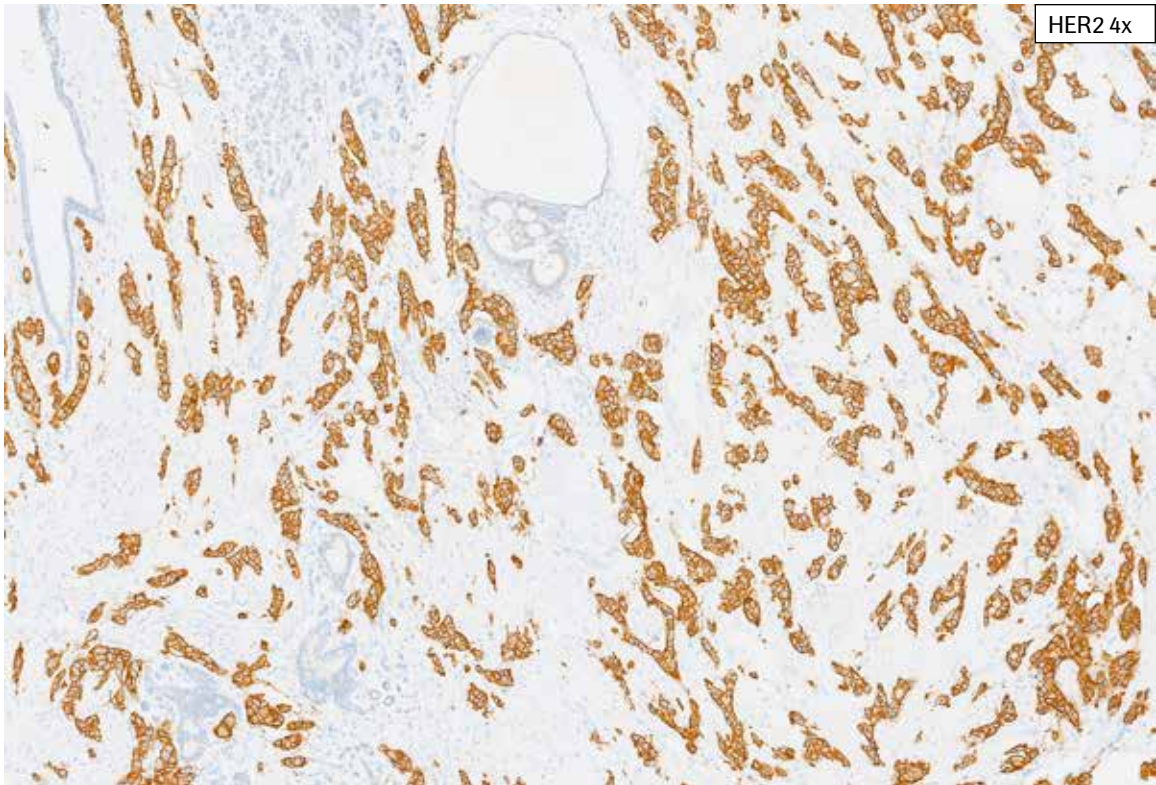
**HER2 IHC Score 3+, Case 3:** Heterogeneity in HER2 staining is present in this case. However, 45% of the viable tumor cells in the tissue section showed complete, intense thick membrane staining (arrow, HER2 IHC Score 3+). Cytoplasmic staining are also present.



**HER2 IHC Score 3+, Case 3:** Heterogeneity in HER2 staining is present in this case. However, 45% of the viable tumor cells in the tissue section showed complete, intense thick membrane staining (arrow, HER2 IHC Score 3+). Cytoplasmic staining are also present.



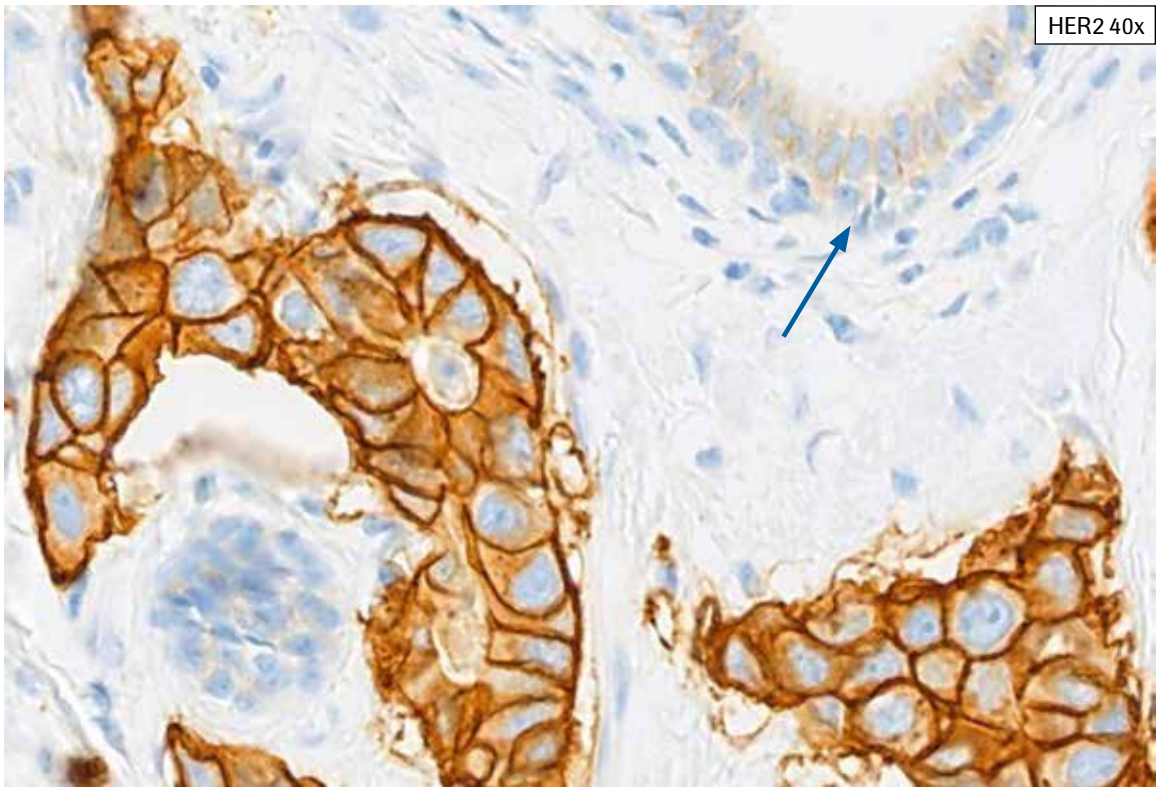
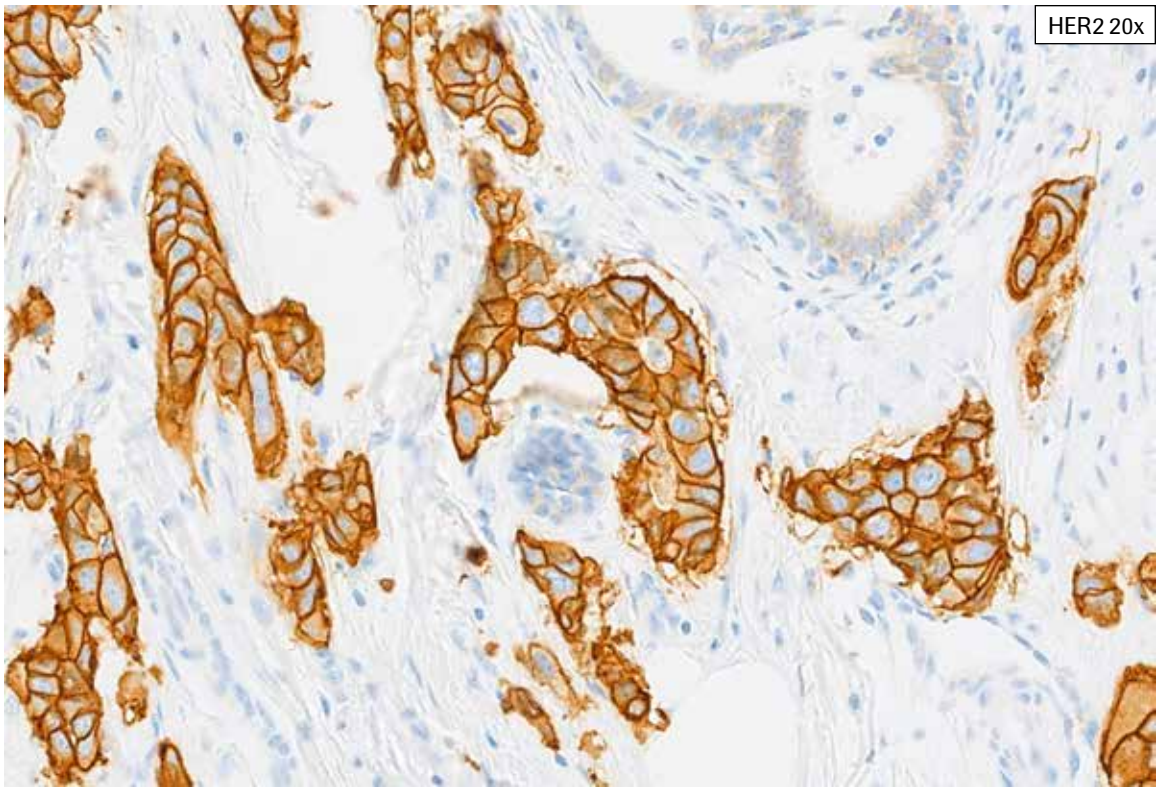
H&E 20x



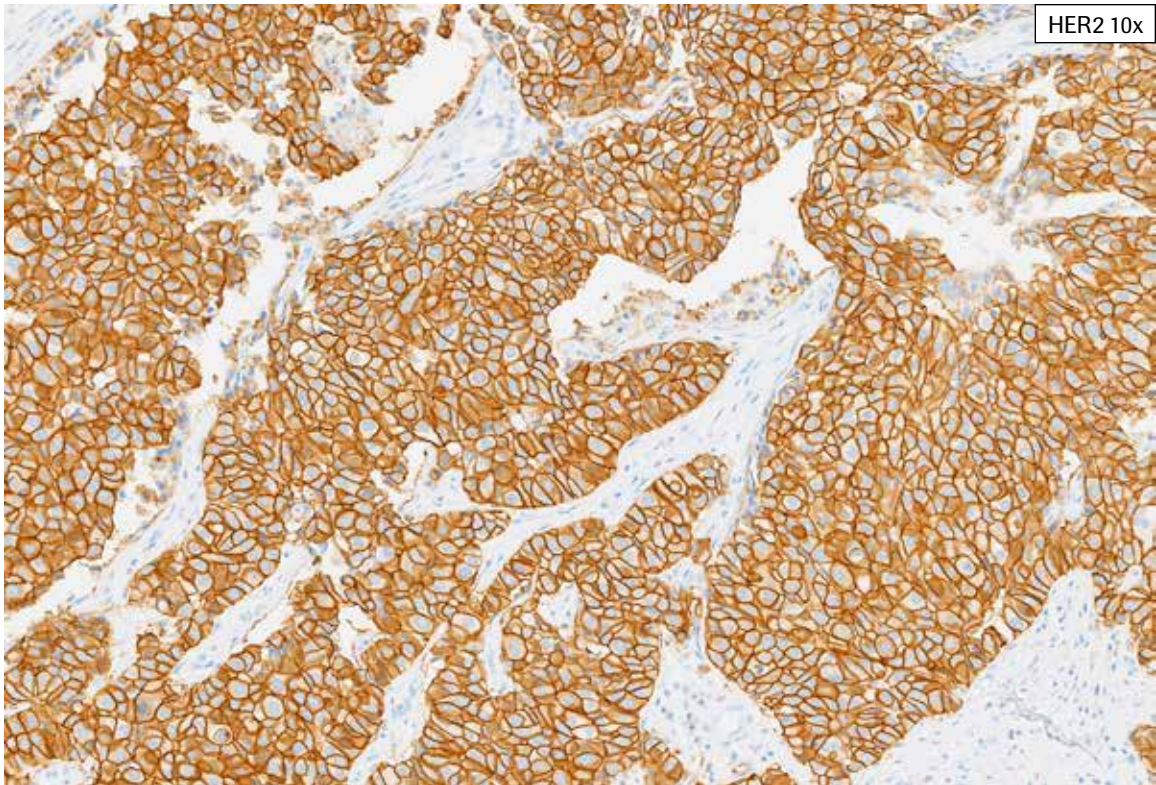
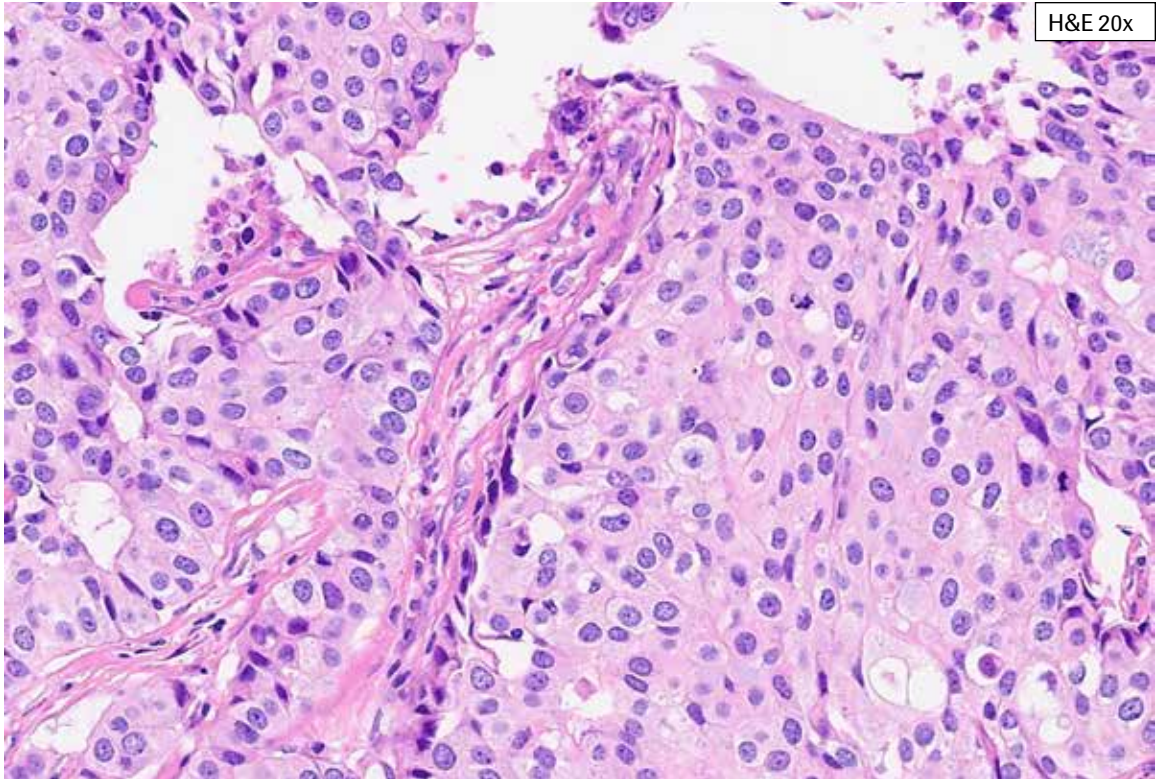
HER2 4x

**HER2 IHC Score 3+, Case 4:** This case exhibits complete, strong staining in the majority of tumor cell membranes. Some moderate complete staining is also present in the 4x image. Non-neoplastic breast epithelium shows faint to weak membrane staining and cytoplasmic bluish. HER2 staining of invasive tumor only is included in HER2 scoring. Overall, this case had 3+ staining in 70% of the tumor cells.

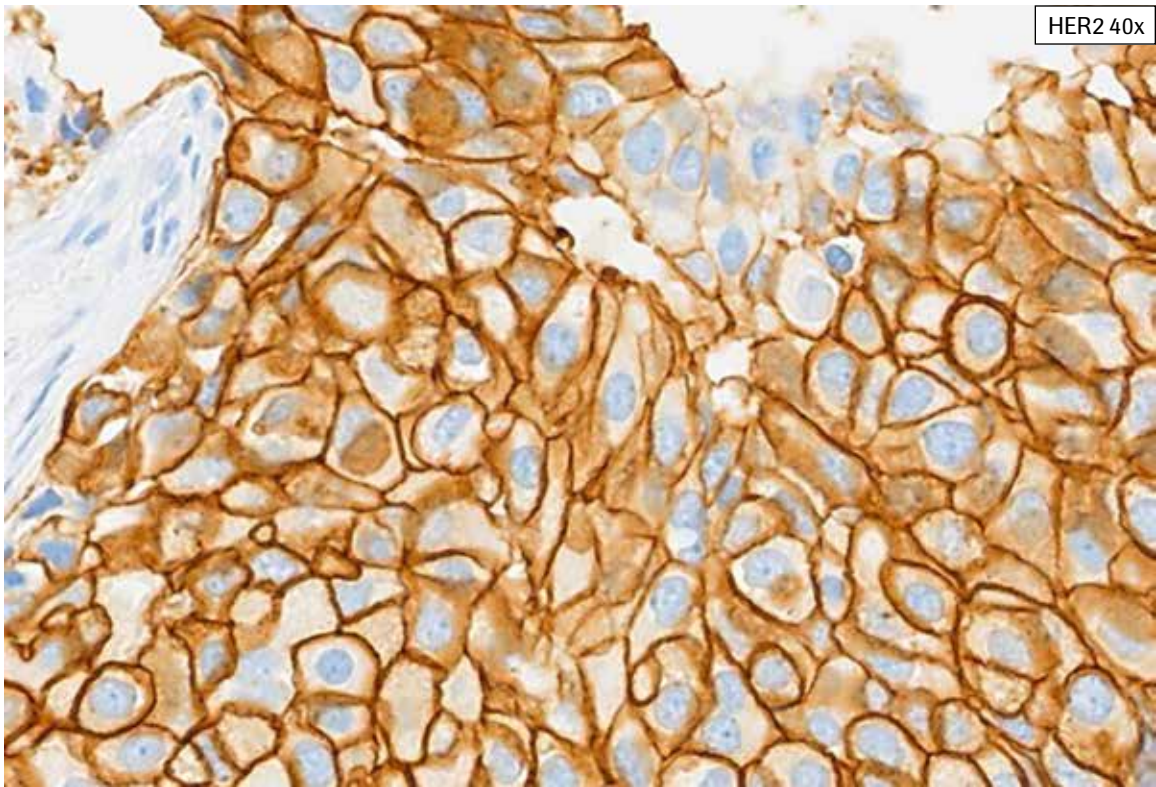
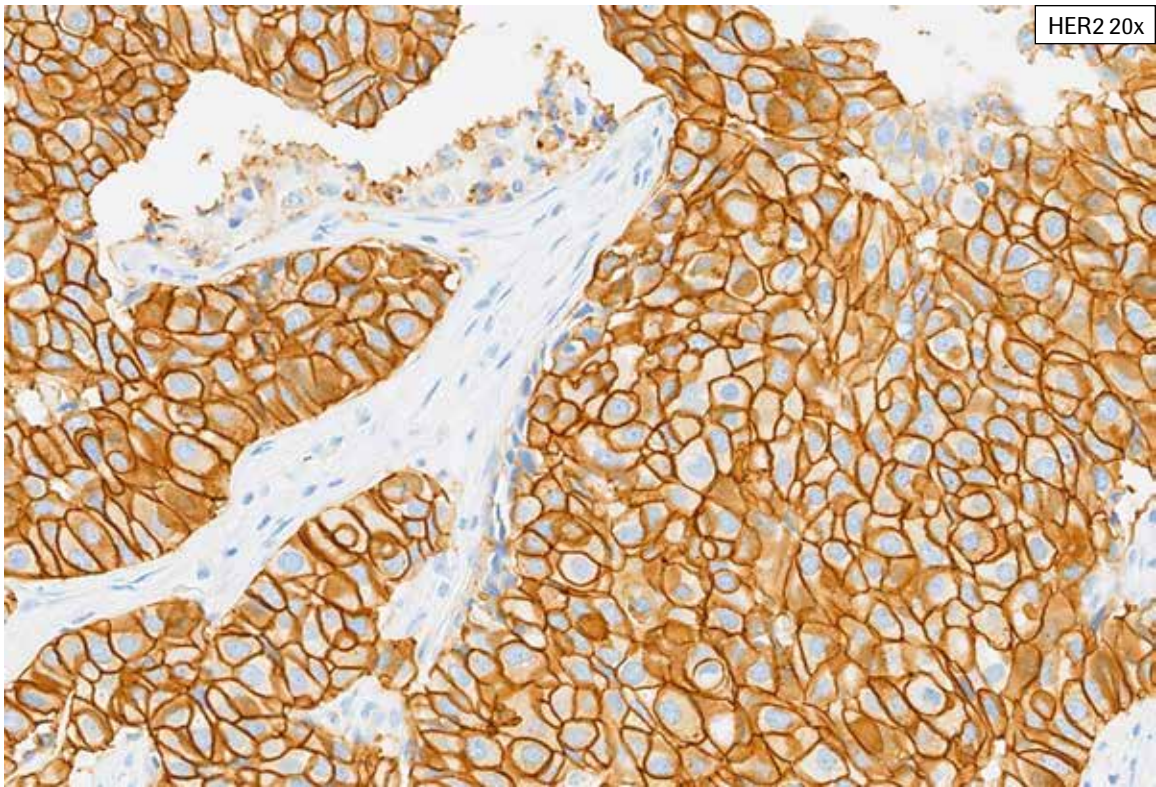




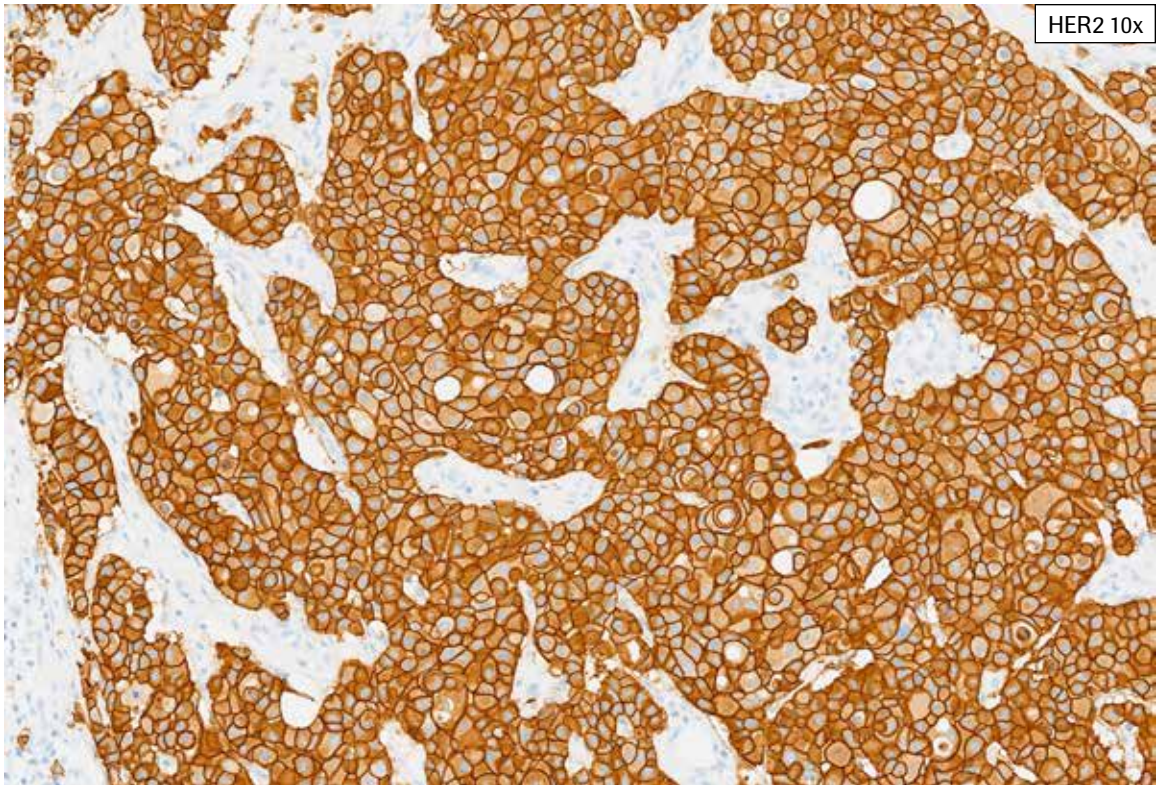
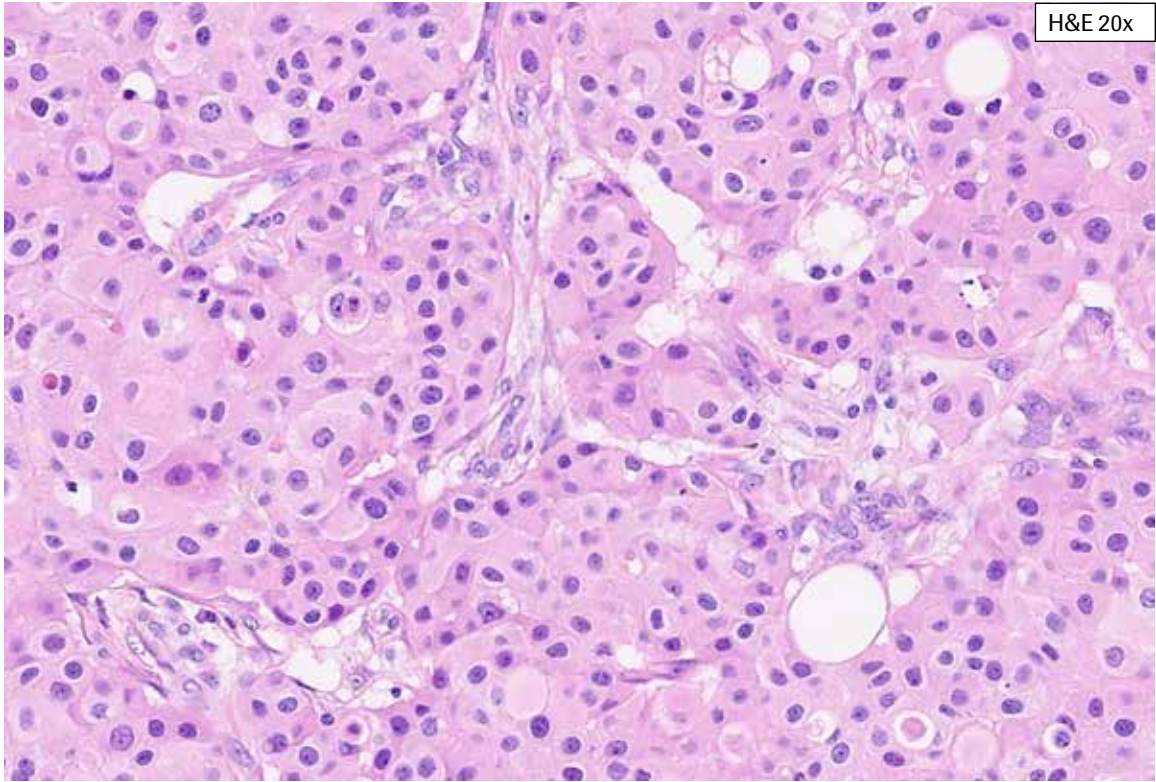
**HER2 IHC Score 3+, Case 4:** This case exhibits complete, strong staining in the majority of tumor cell membranes. Some moderate complete staining is also present in the 4x image. Non-neoplastic breast epithelium shows faint to weak membrane staining and cytoplasmic bluish (arrow). HER2 staining of invasive tumor only is included in HER2 scoring. Overall, this case had 3+ staining in 70% of the tumor cells.



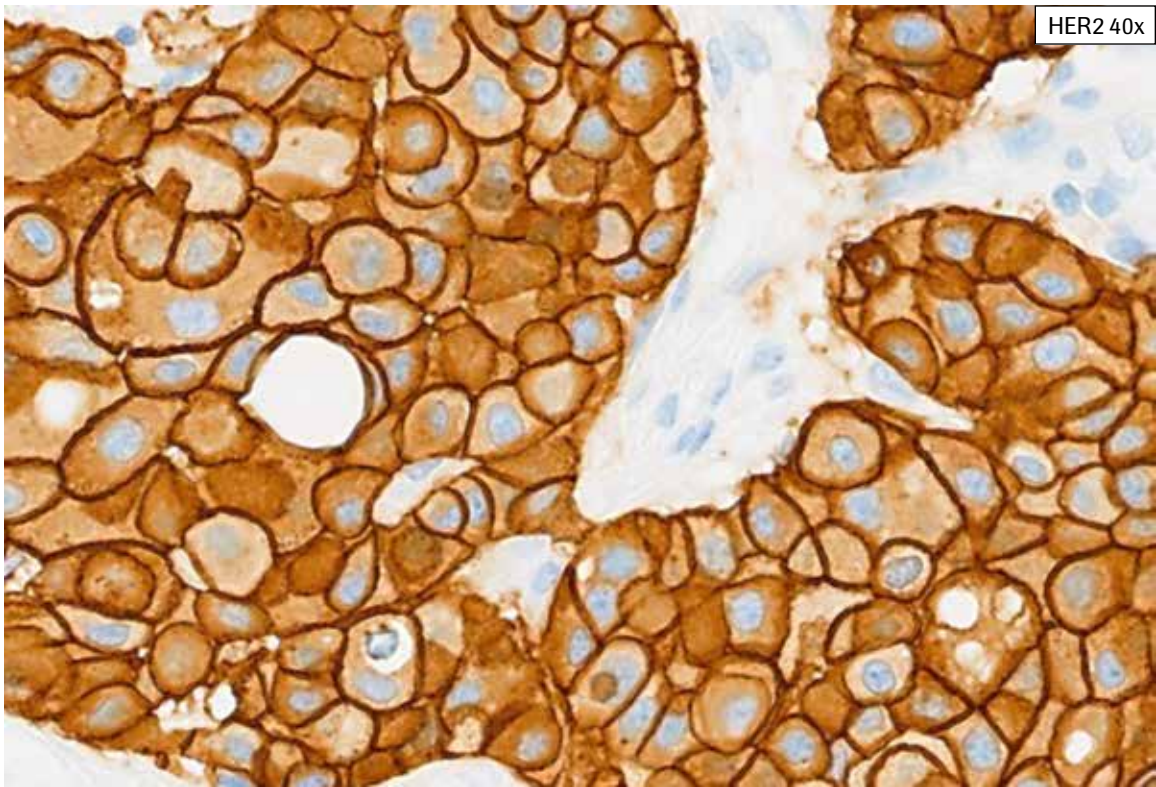
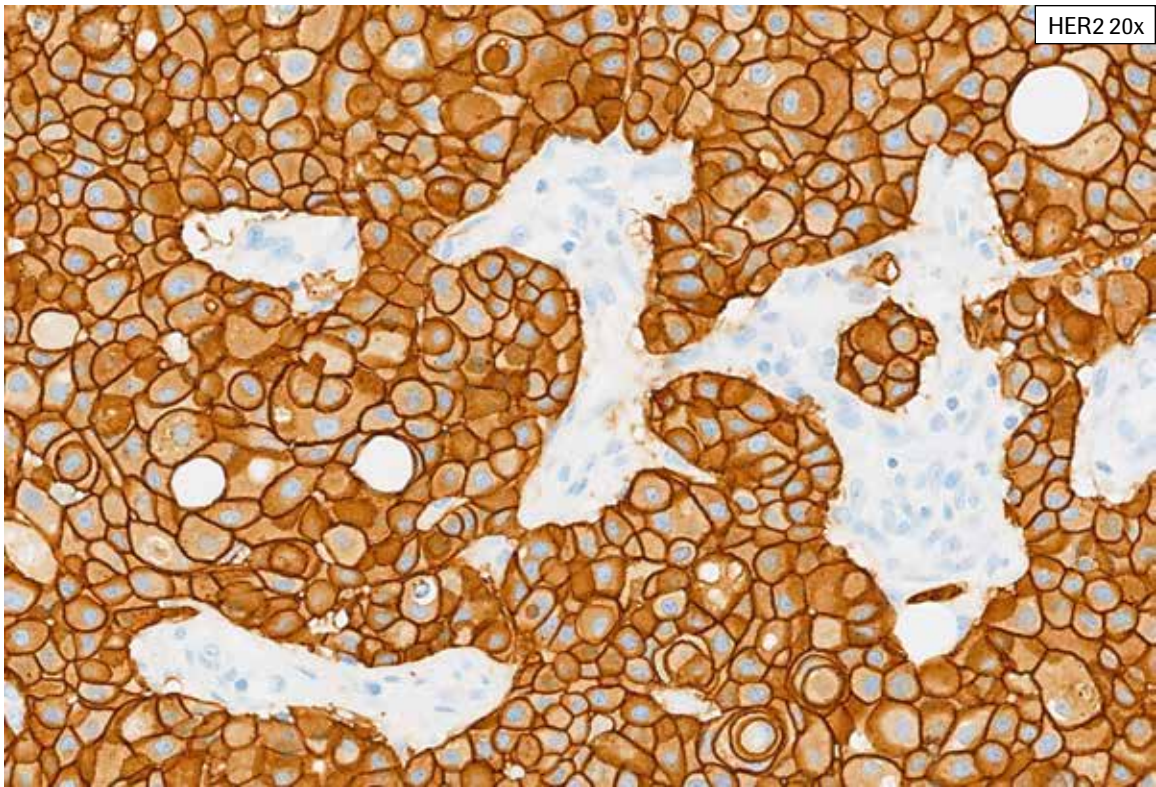
**HER2 IHC Score 3+, Case 5:** This case exhibits abundant invasive tumor with strong, complete membrane staining. There is some retraction artifact with tissue edges staining and not all tumor cells show 3+ staining. This case is a straightforward HER2 IHC score 3+ case with well over 10% complete, strong membrane staining.



**HER2 IHC Score 3+, Case 5:** This case exhibits abundant invasive tumor with strong, complete membrane staining. There is some retraction artifact with tissue edges staining and not all tumor cells show 3+ staining. This case is a straightforward HER2 IHC score 3+ case with well over 10% complete, strong membrane staining.


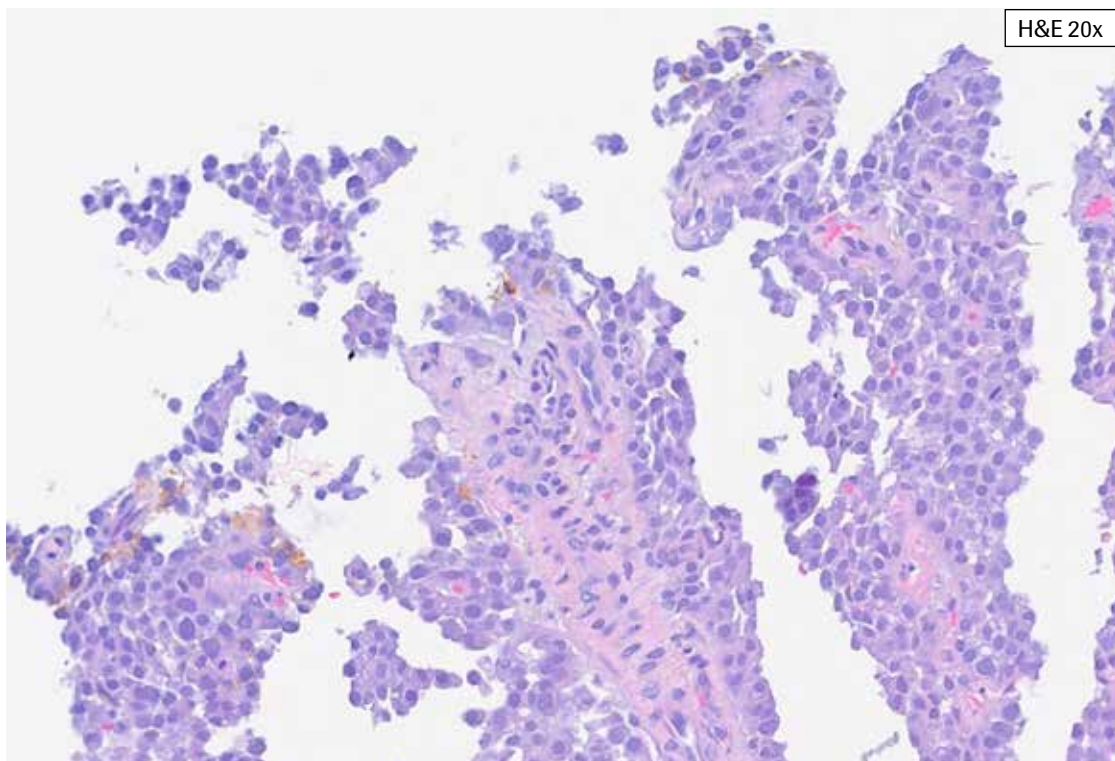


**HER2 IHC Score 3+, Case 6:** Complete, strong staining of practically all tumor cell membranes is present. Note that membranes are well-defined with thick, intense, ring-like HER2 staining.

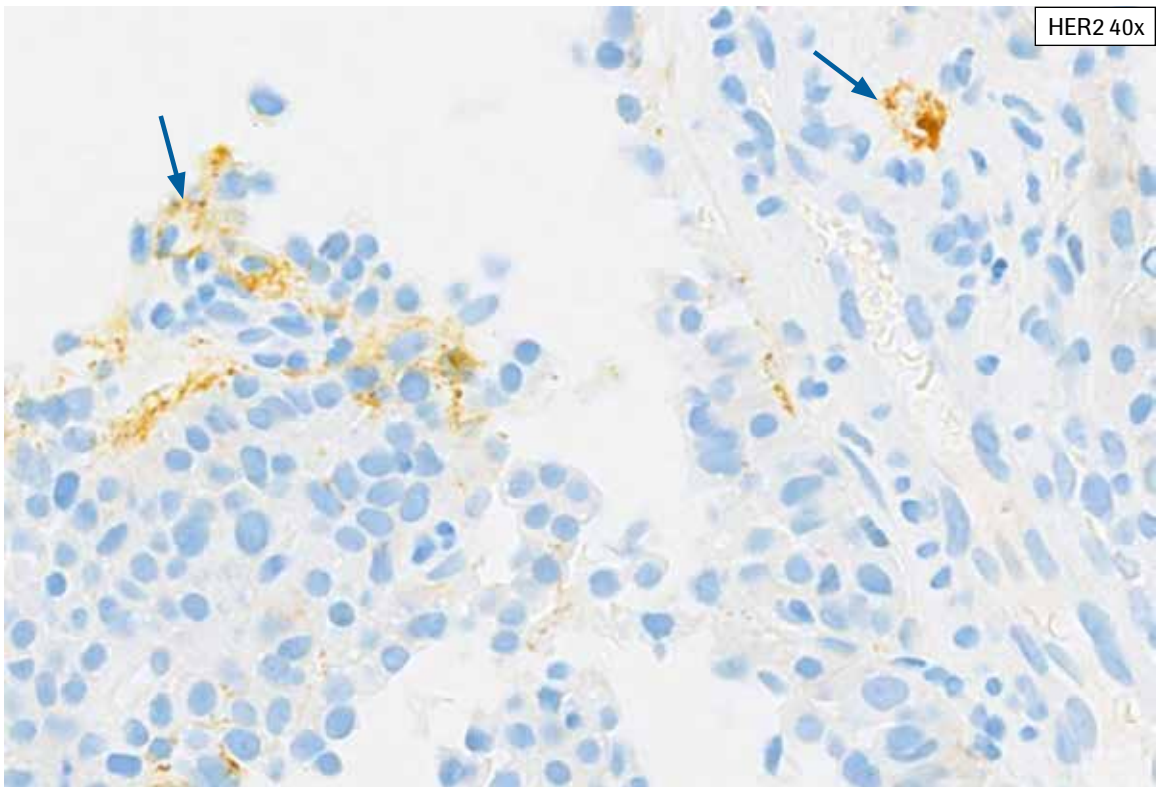
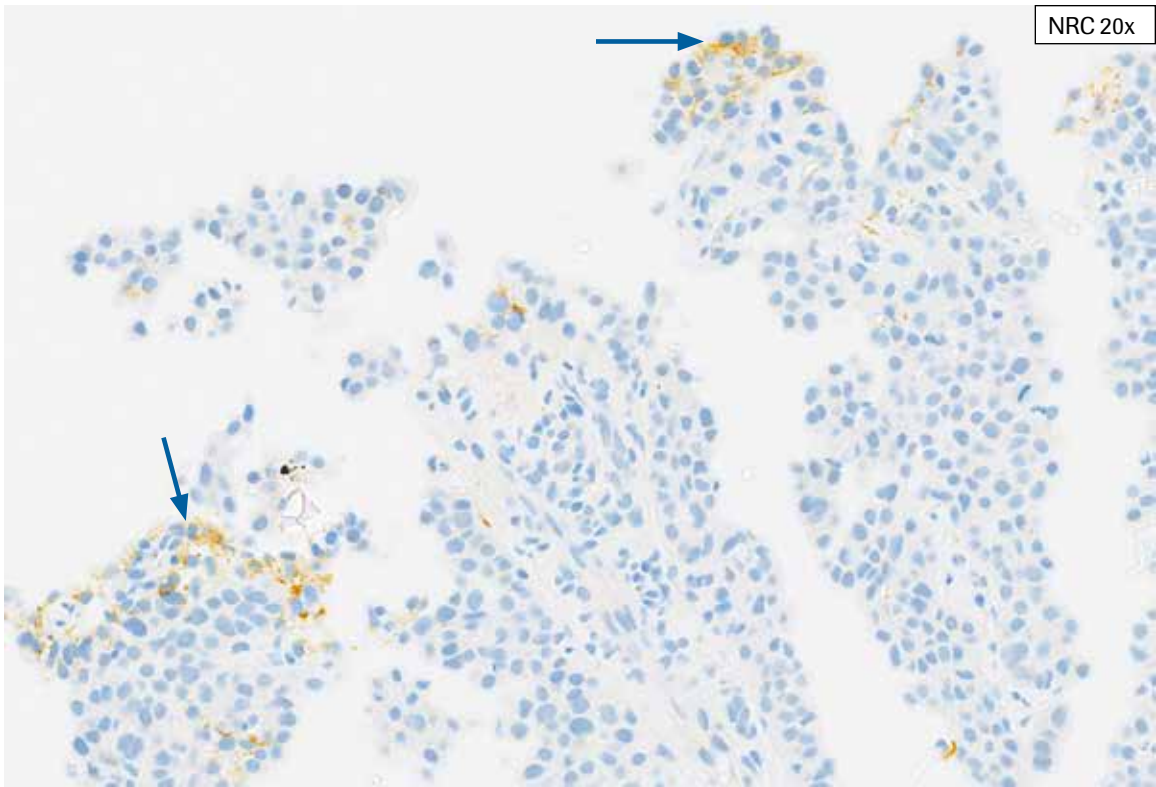


**HER2 IHC Score 3+, Case 6:** Complete, strong staining of practically all tumor cell membranes is present. Note that membranes are well-defined with thick, intense, ring-like HER2 staining.

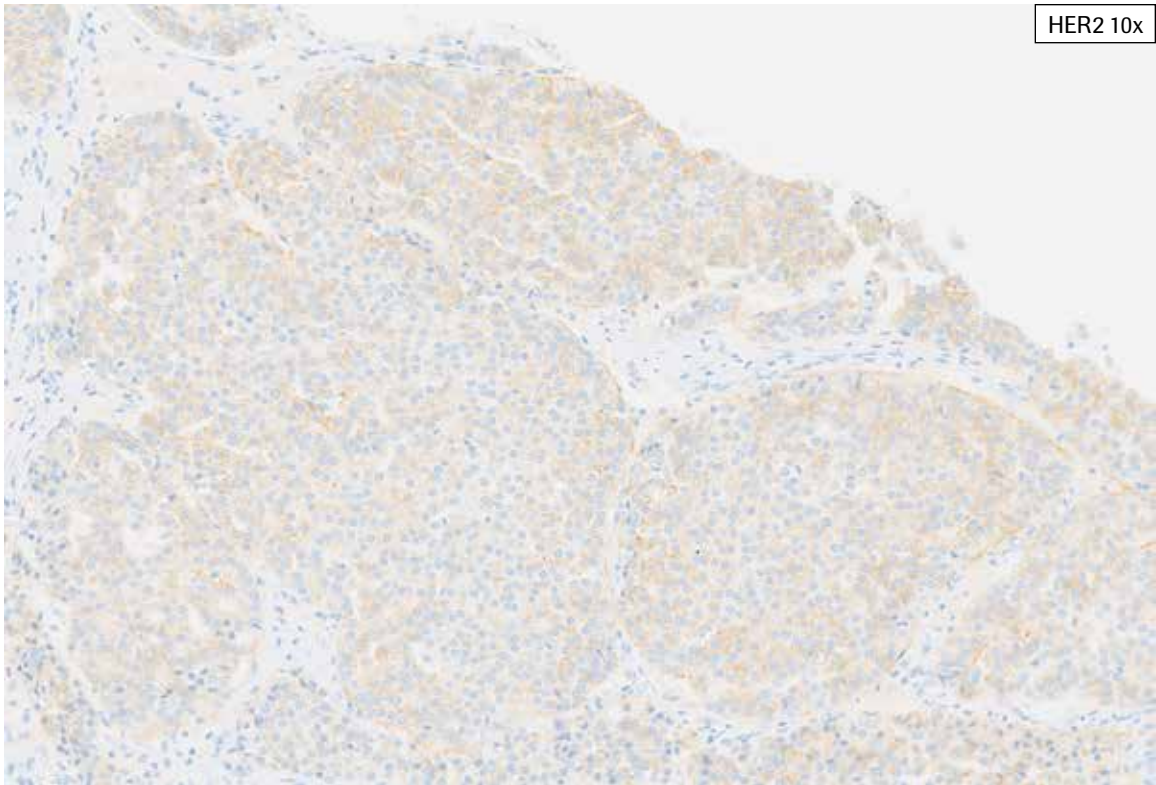
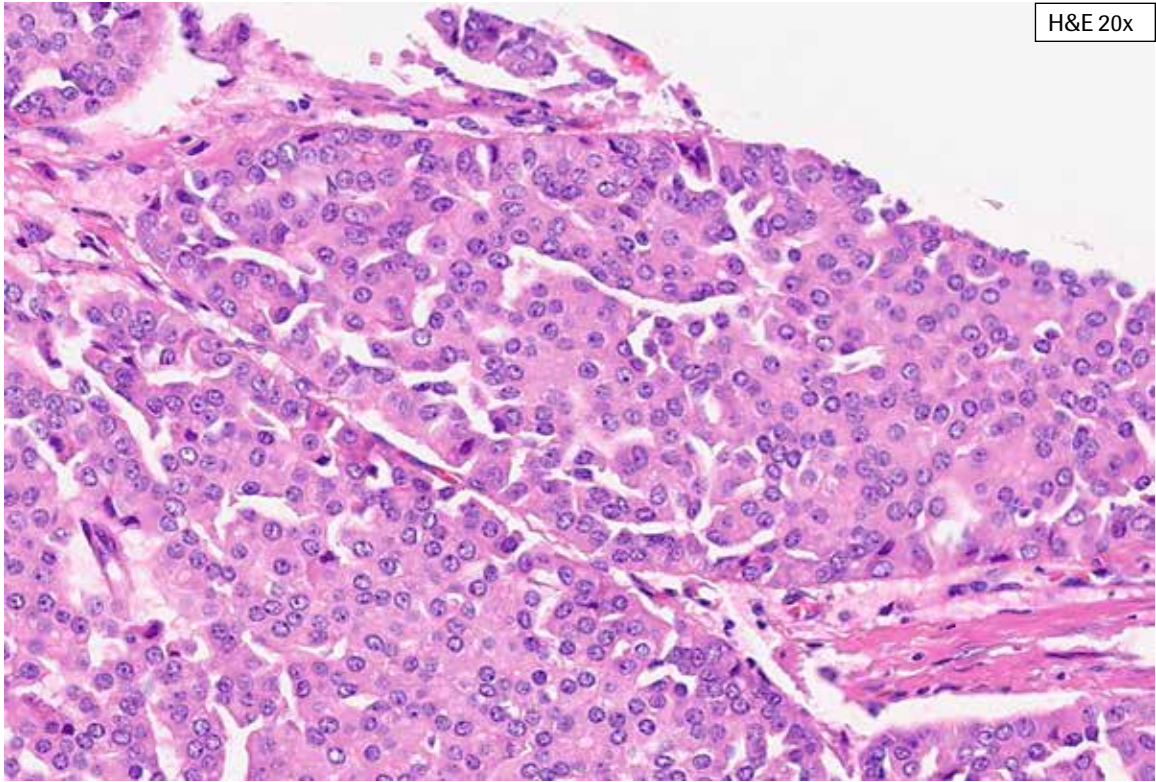
## Artifacts and Challenging Cases



**Artifacts/Challenging Case 1:** Care must be taken not to interpret yellow surgical ink as HER2 staining. This can be discerned by going to higher magnification and by reviewing the NRC slide. The overall HER2 staining in this tissue was 0% (HER2 IHC 0).

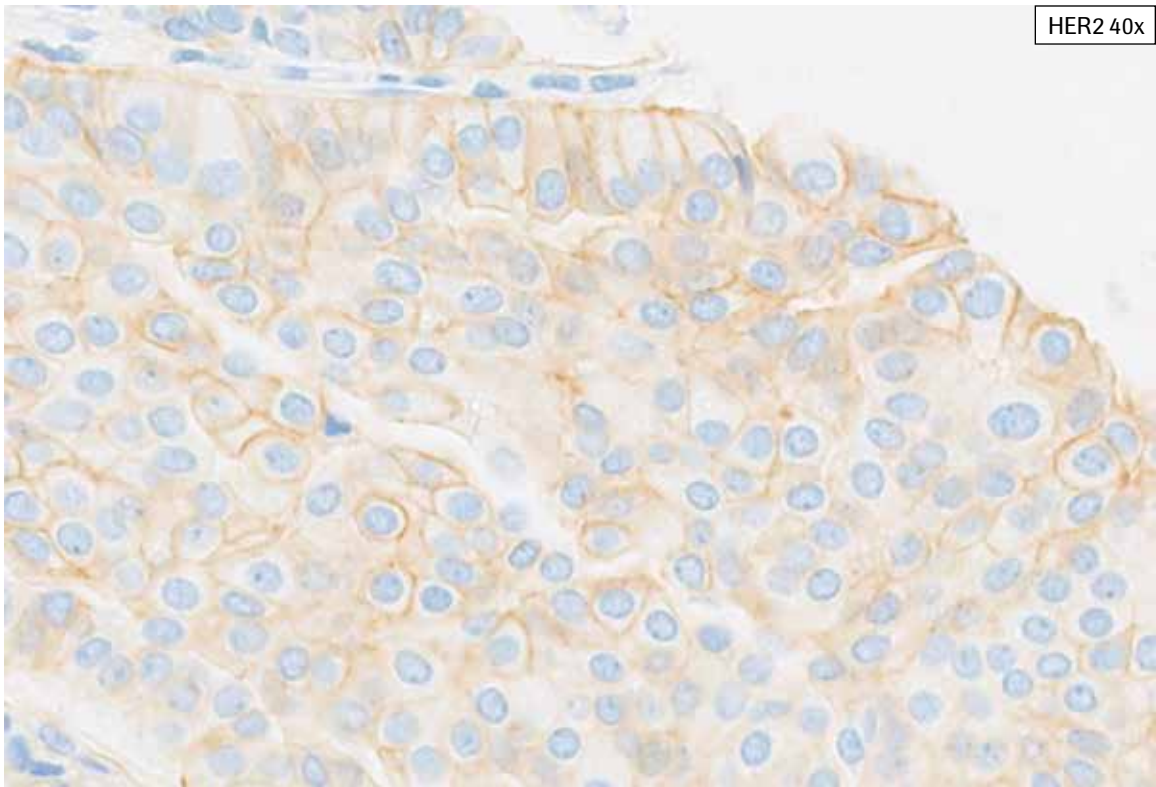
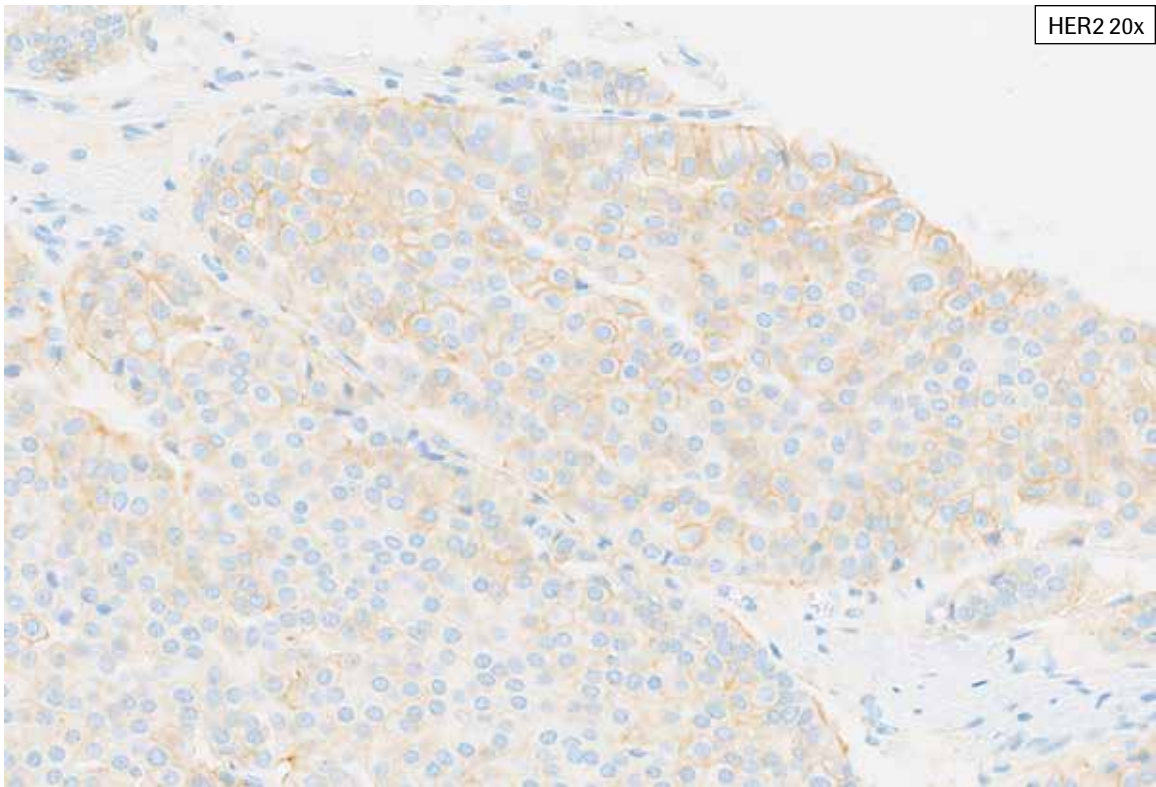


**Artifacts/Challenging Case 1:** Care must be taken not to interpret yellow surgical ink as HER2 staining (arrow). This can be discerned by going to higher magnification and by reviewing the NRC slide. The overall HER2 staining in this tissue was 0% (HER2 IHC 0).

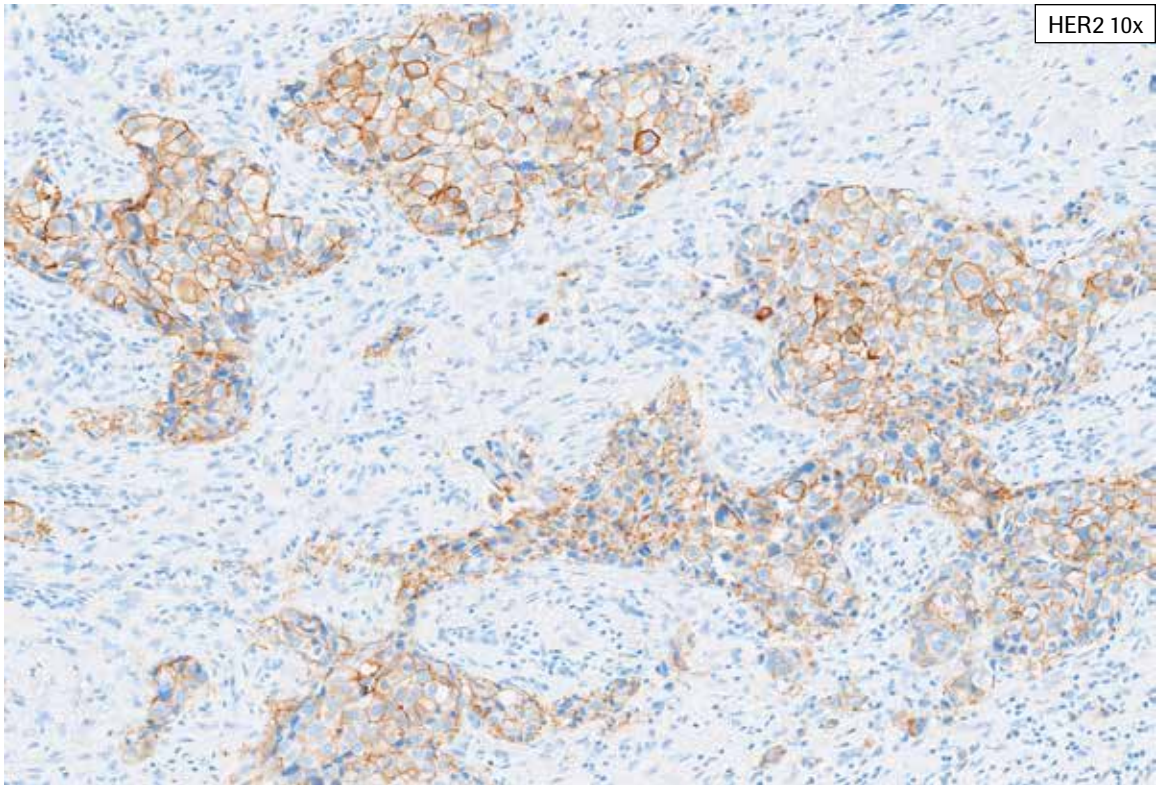
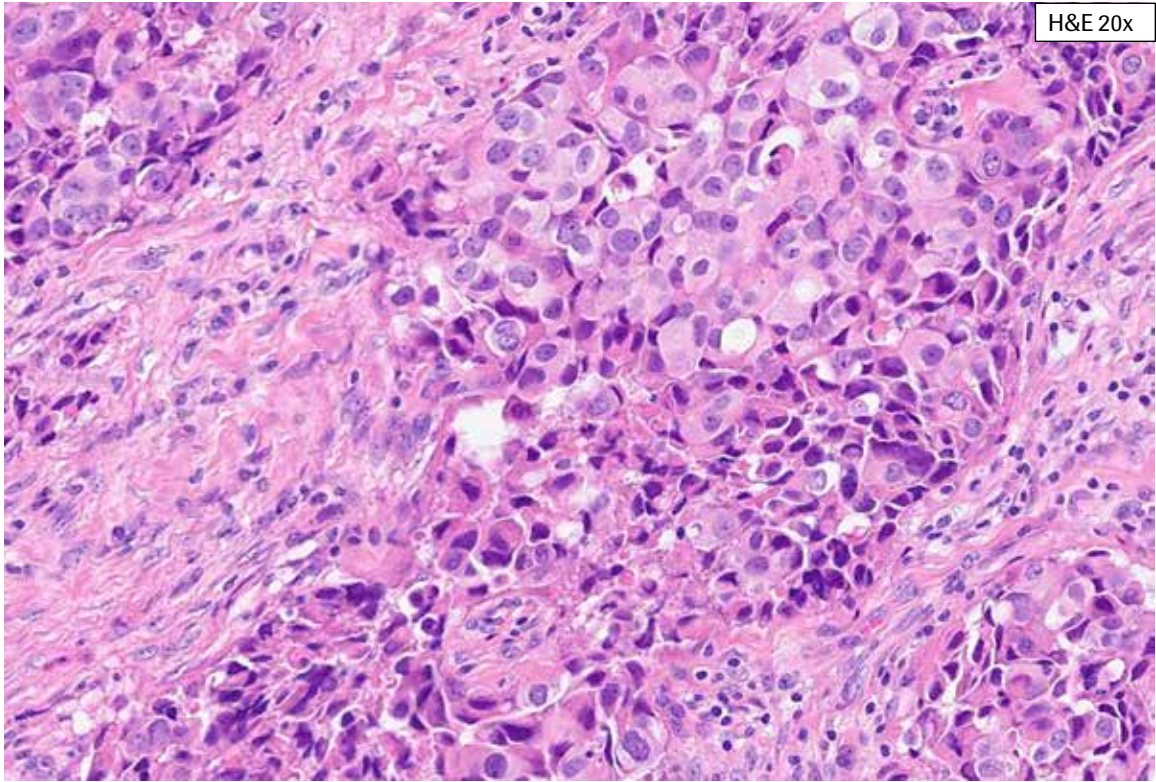


**Artifacts/Challenging Case 2:** This case exhibits more staining along one tissue edge. Preferential staining along tissue edge(s) may be artifactual and consideration should be given to repeat staining, particularly if the edge staining is associated with background staining. In this case, the staining along this tissue edge did not impact the overall tissue HER2 IHC Score of 2+.

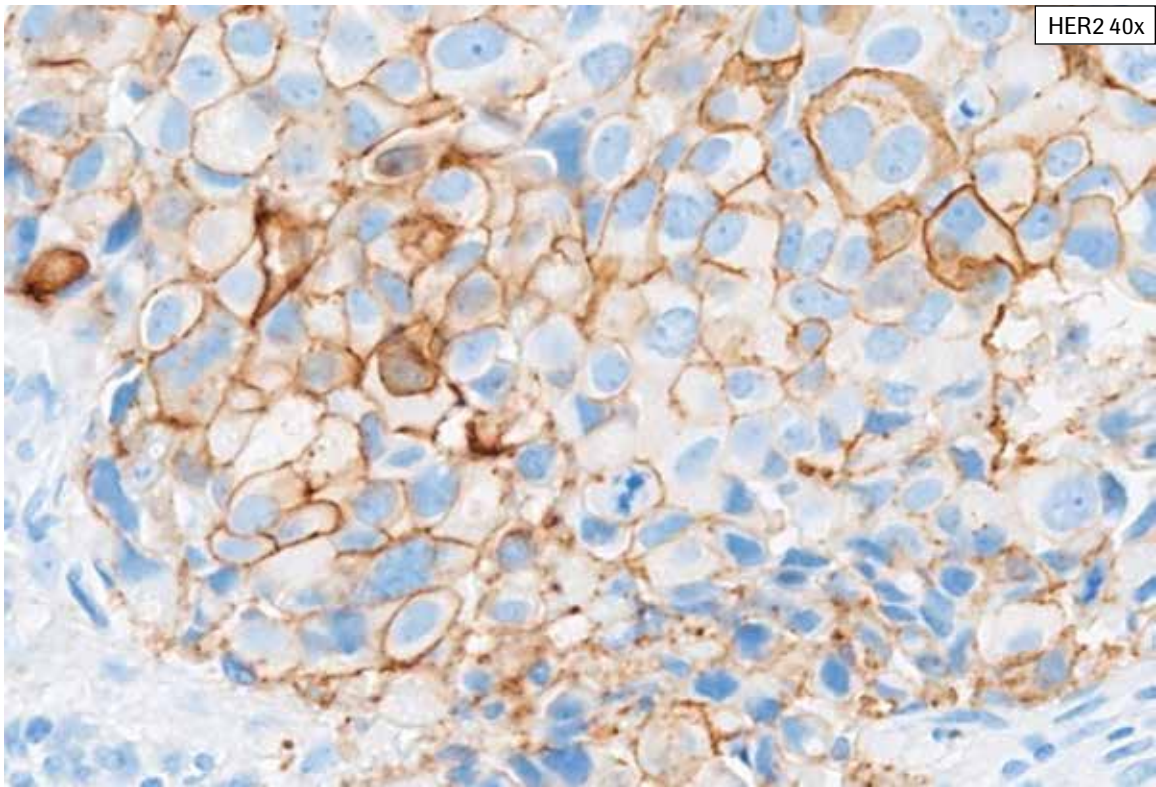
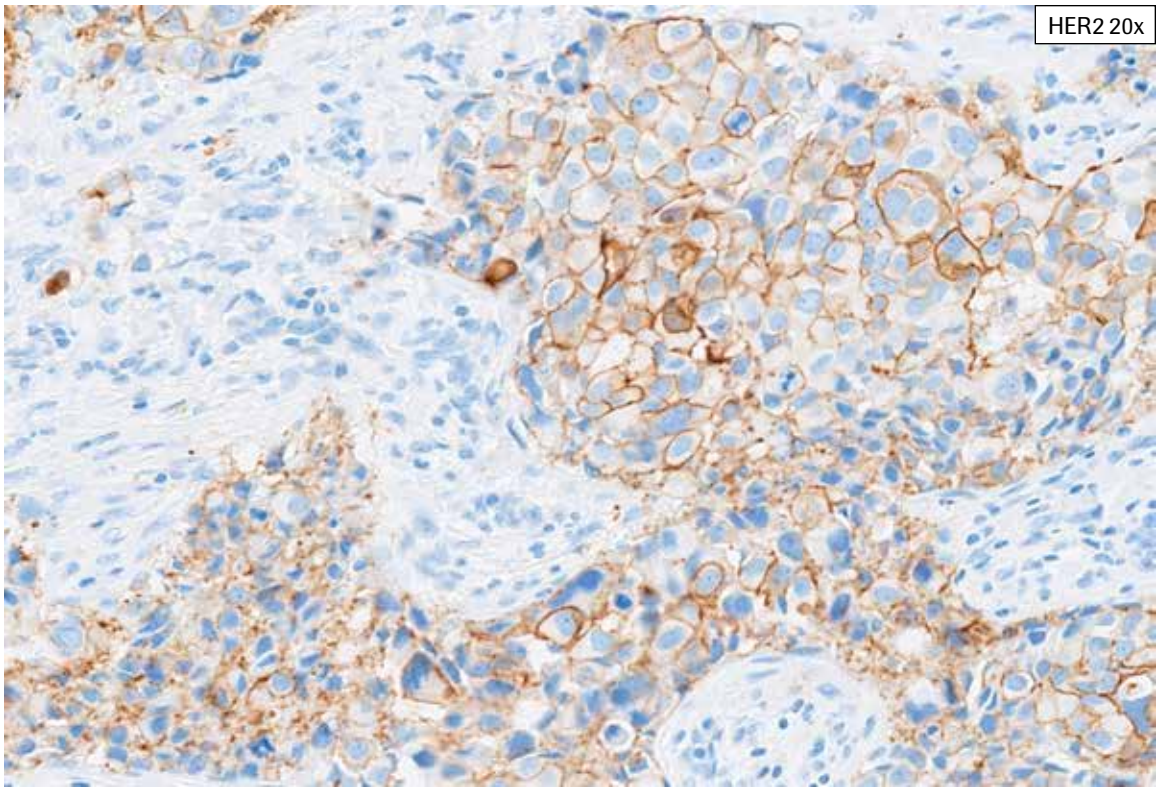




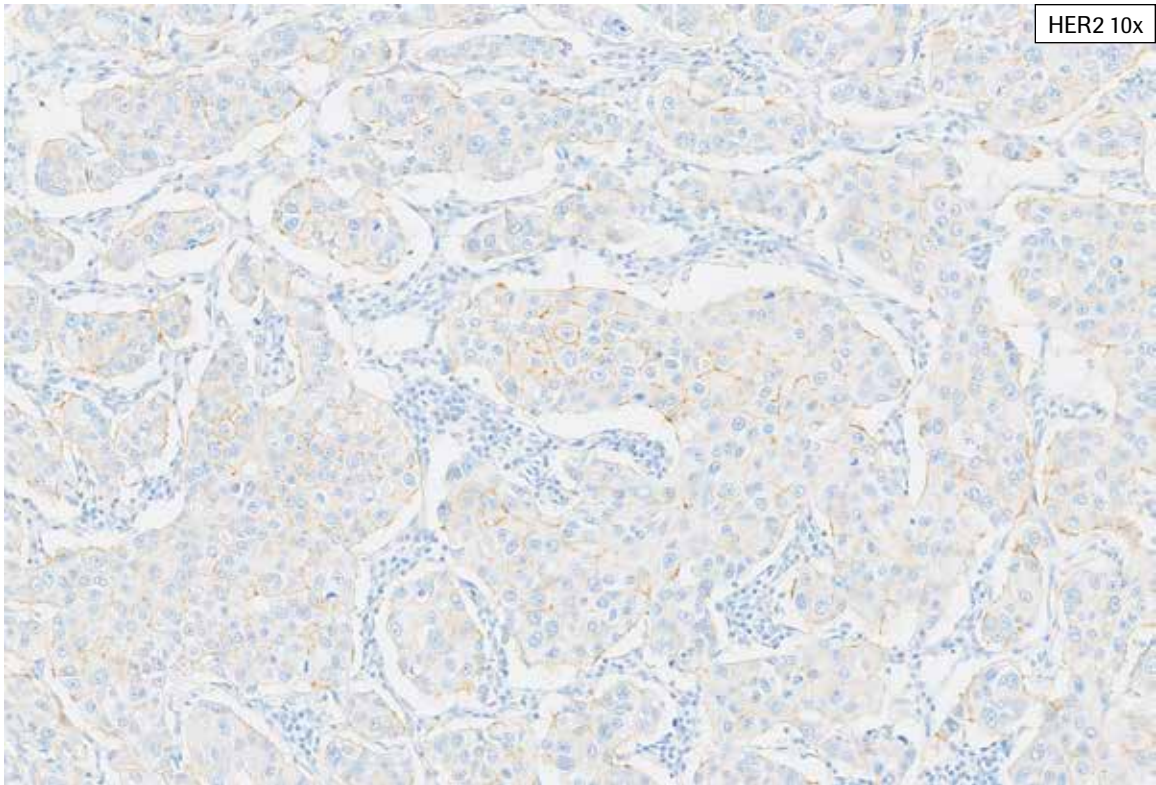
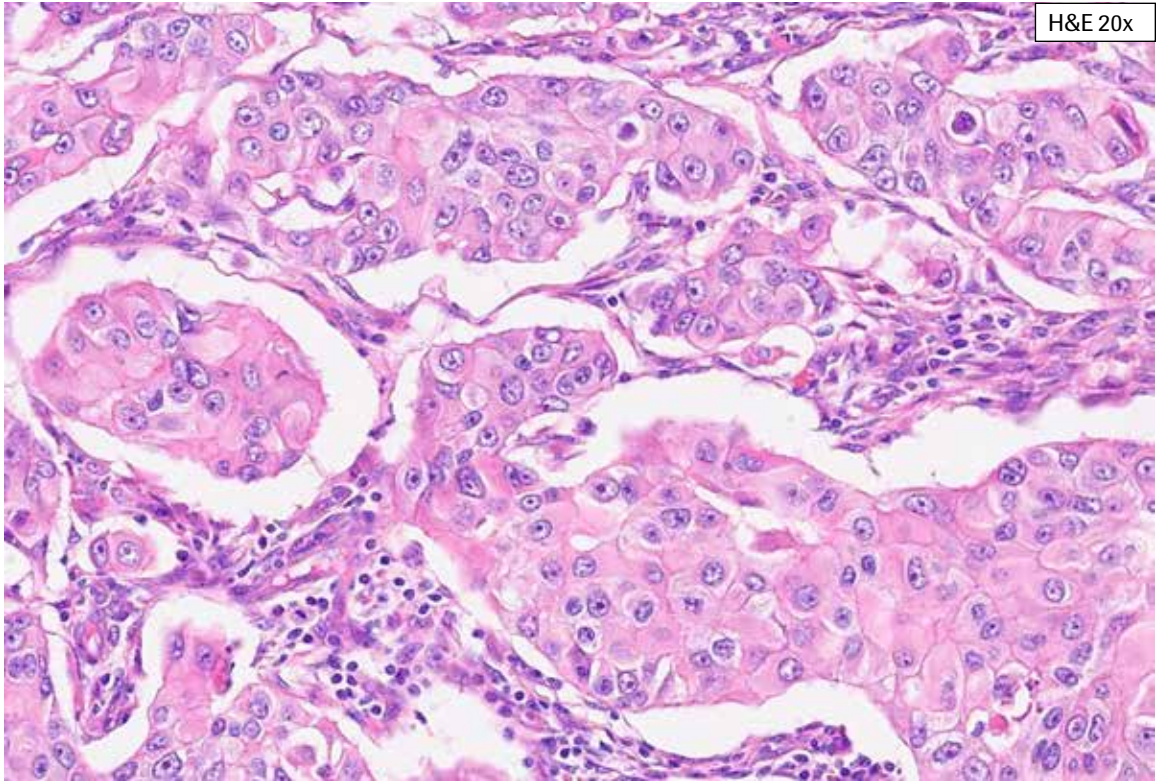
**Artifacts/Challenging Case 2:** This case exhibits more staining along one tissue edge. Preferential staining along tissue edge(s) may be artifactual and consideration should be given to repeat staining, particularly if the edge staining is associated with background staining. In this case, the staining along this tissue edge did not impact the overall tissue HER2 IHC Score of 2+.



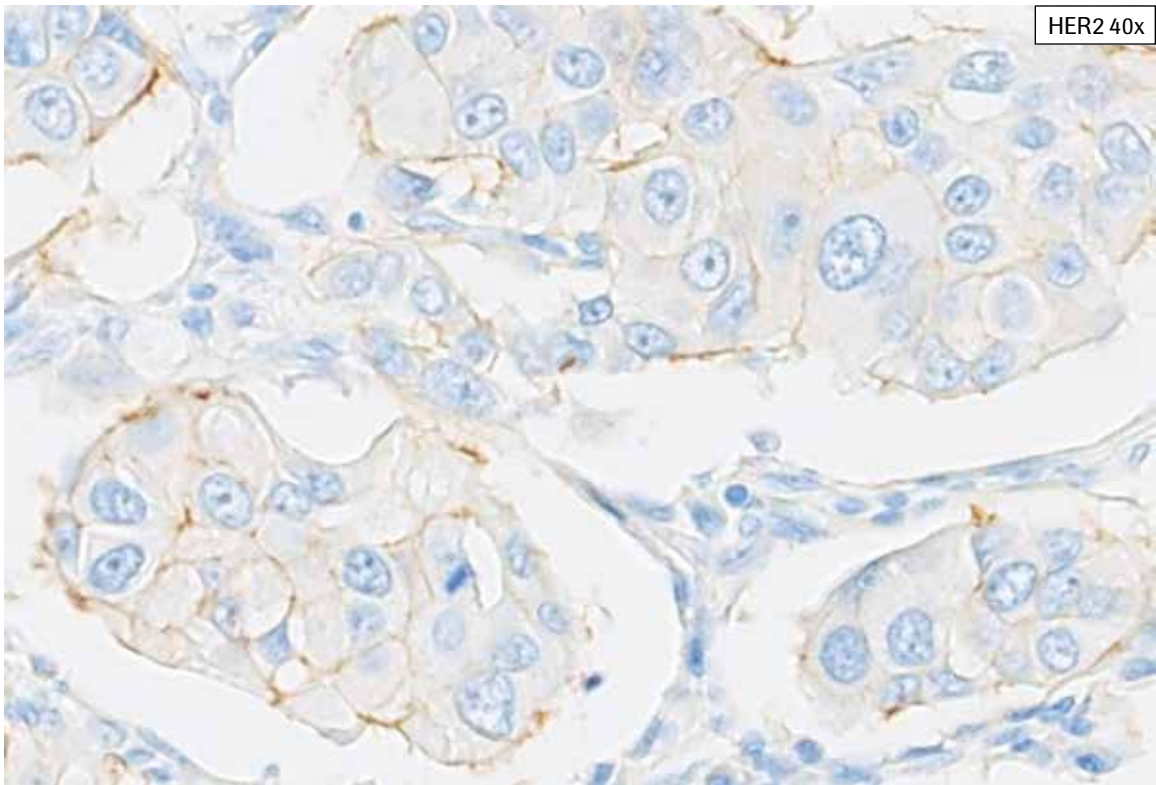
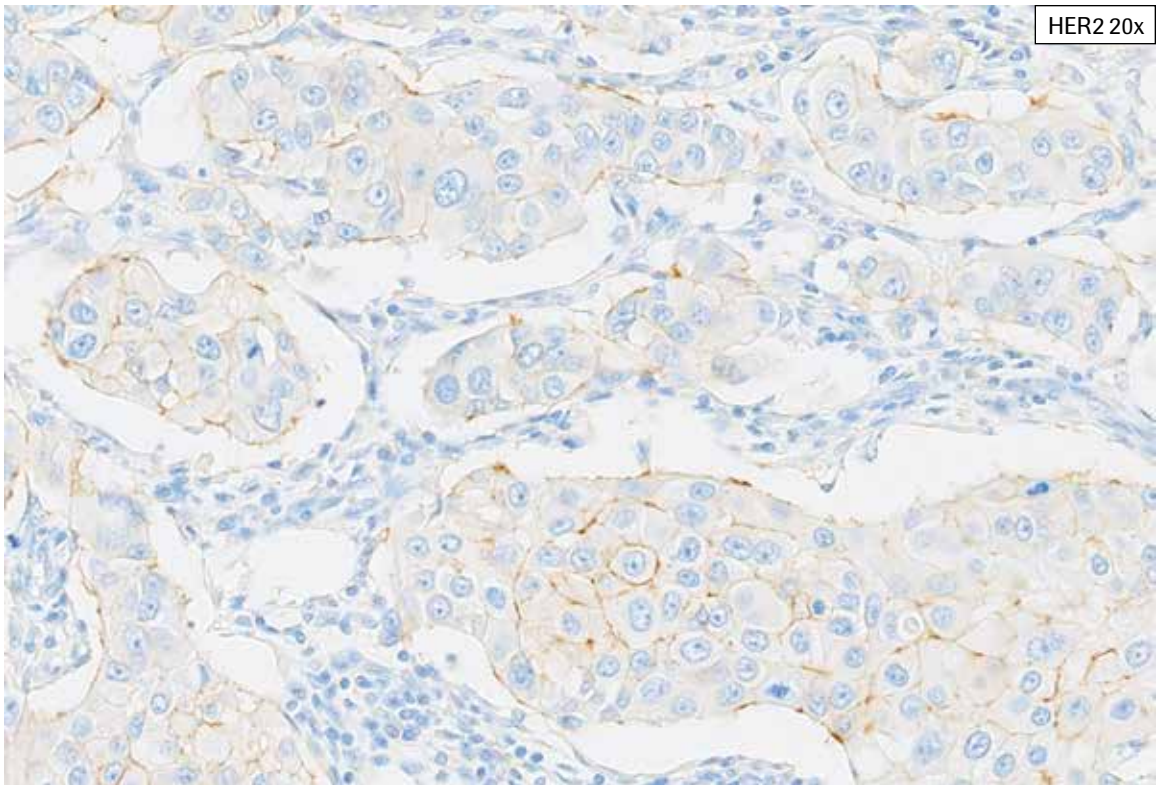
**Artifacts/Challenging Case 3:** This tissue exhibits complete, intense staining in more than 10% of the tumor cells (HER2 IHC Score 3+), but also has areas of granular staining in the cytoplasm and focally, in apparent association with tumor cell membranes. Granular membrane staining is excluded from HER2 scoring.



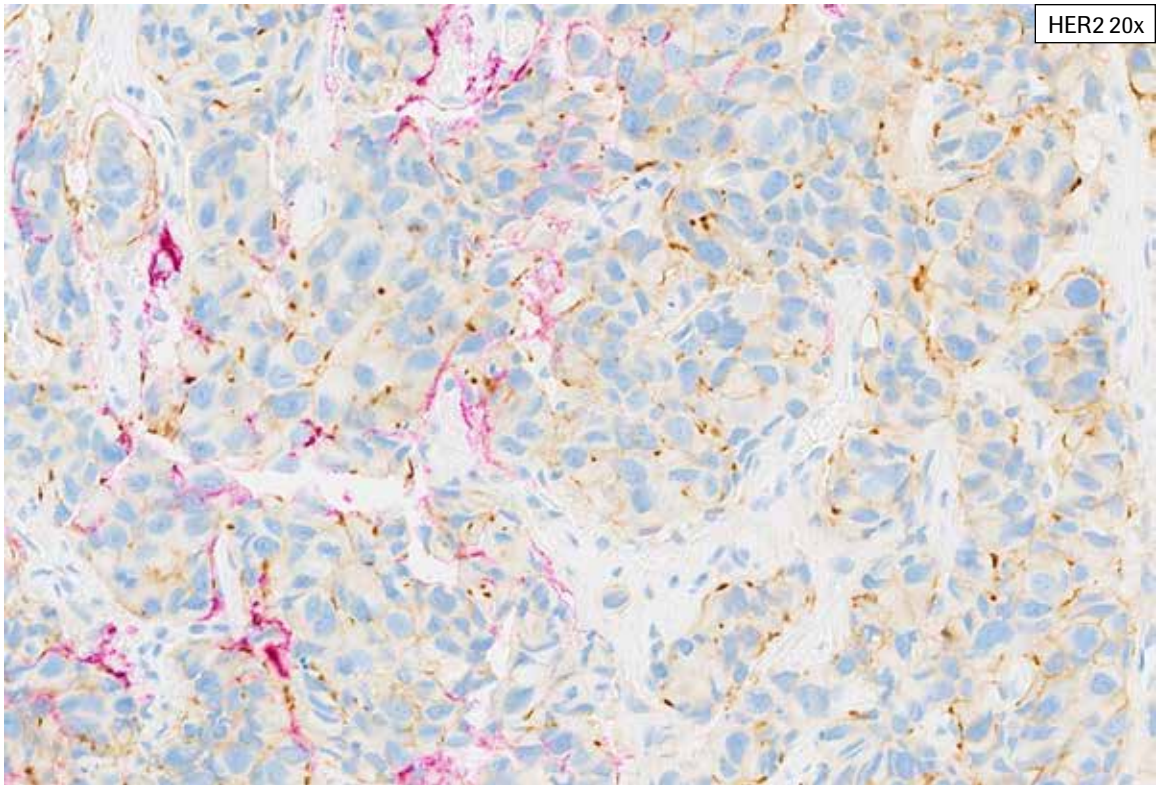
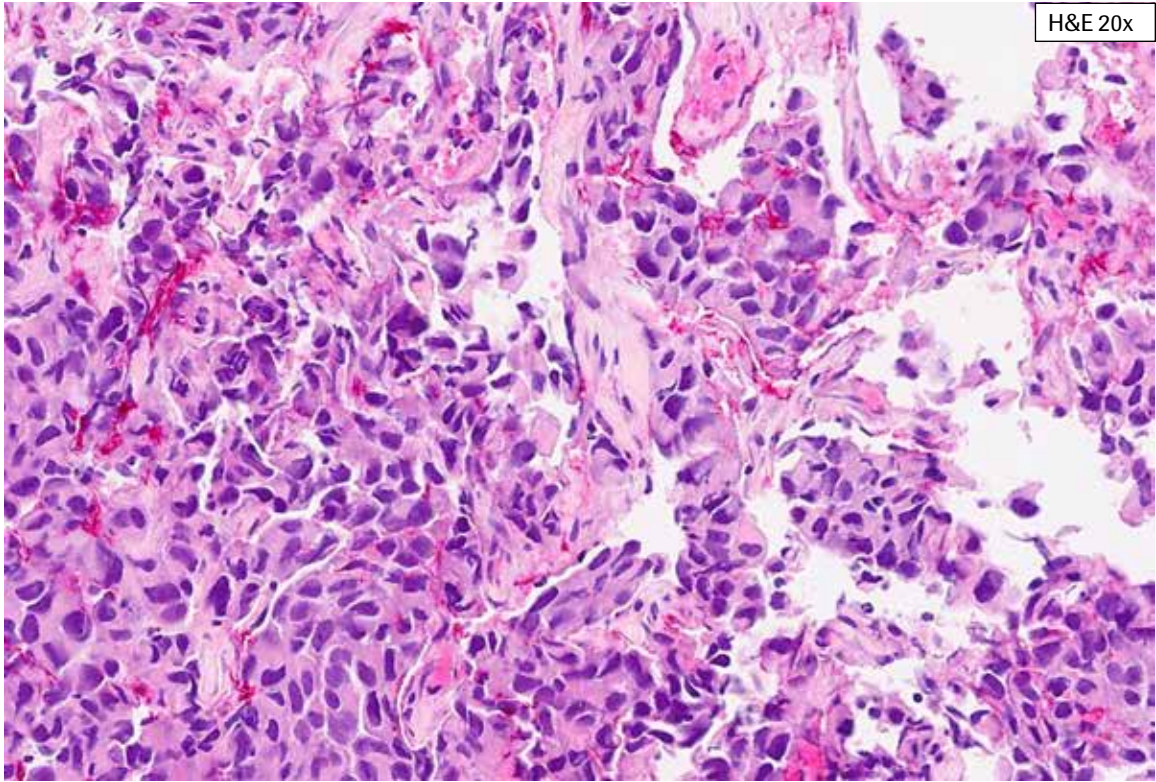
**Artifacts/Challenging Case 3:** This tissue exhibits complete, intense staining in more than 10% of the tumor cells (HER2 IHC Score 3+), but also has areas of granular staining in the cytoplasm and focally, in apparent association with tumor cell membranes. Granular membrane staining is excluded from HER2 scoring.



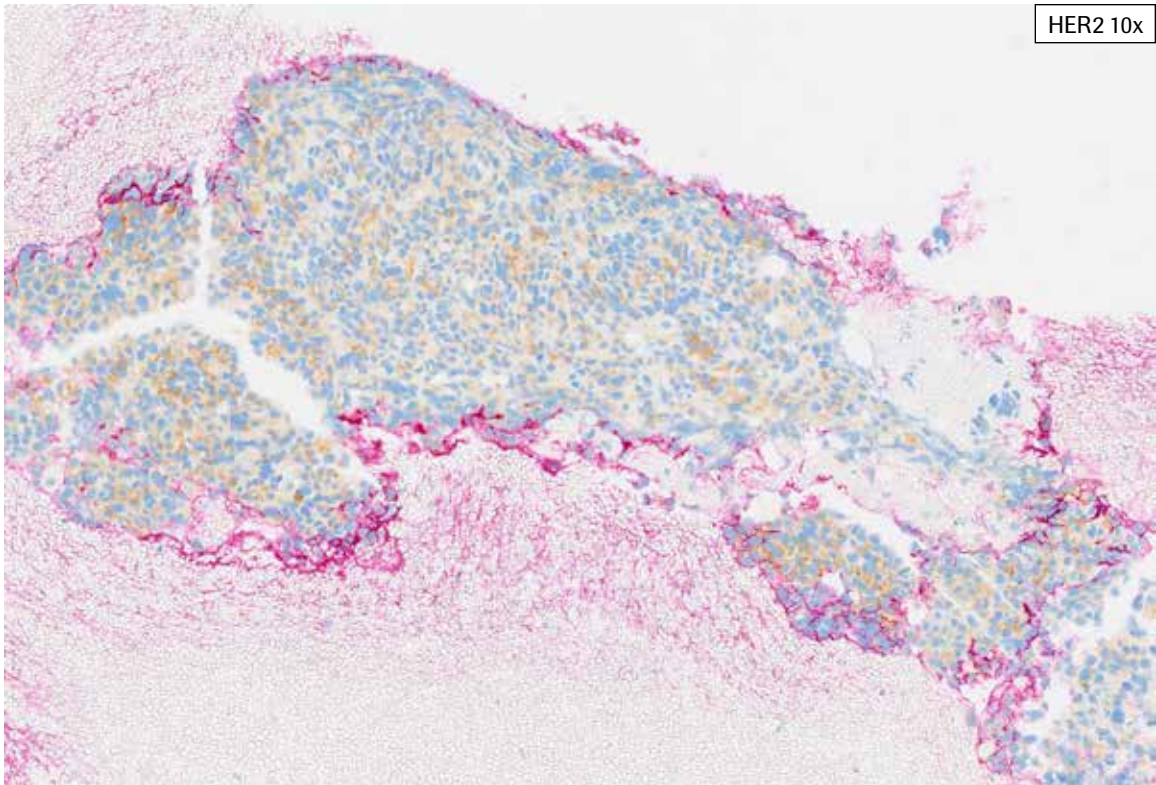
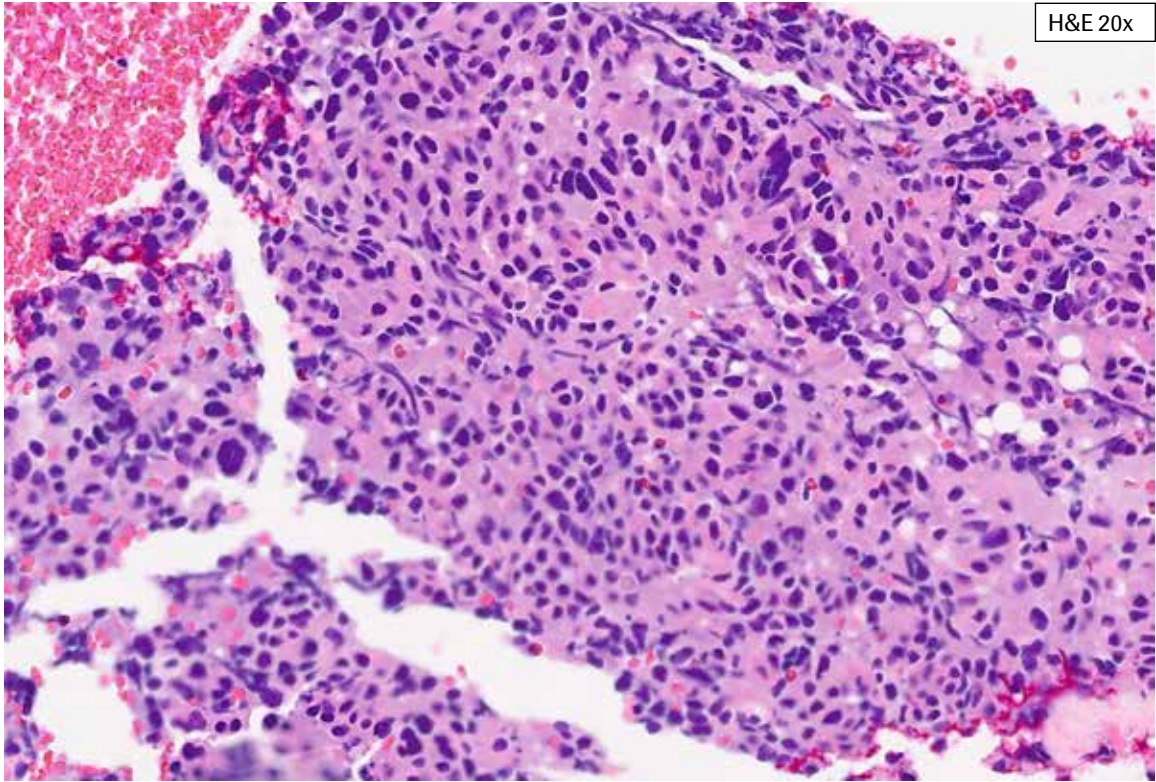
**Artifacts/Challenging Case 4:** This tissue exhibits abundant retraction artifact with HER2 staining of the retracted tissue edges. Any HER2 staining of tumor at retracted tissue edges, free tissue/tumor edges or open spaces (lumina or pseudolumina) is not included in HER2 scoring unless HER2 staining is also present extending along the lateral tumor cell membrane. This challenging case had an overall HER2 IHC Score of 2+, with 25% of viable tumor cells showing complete, weak to moderate membrane staining.



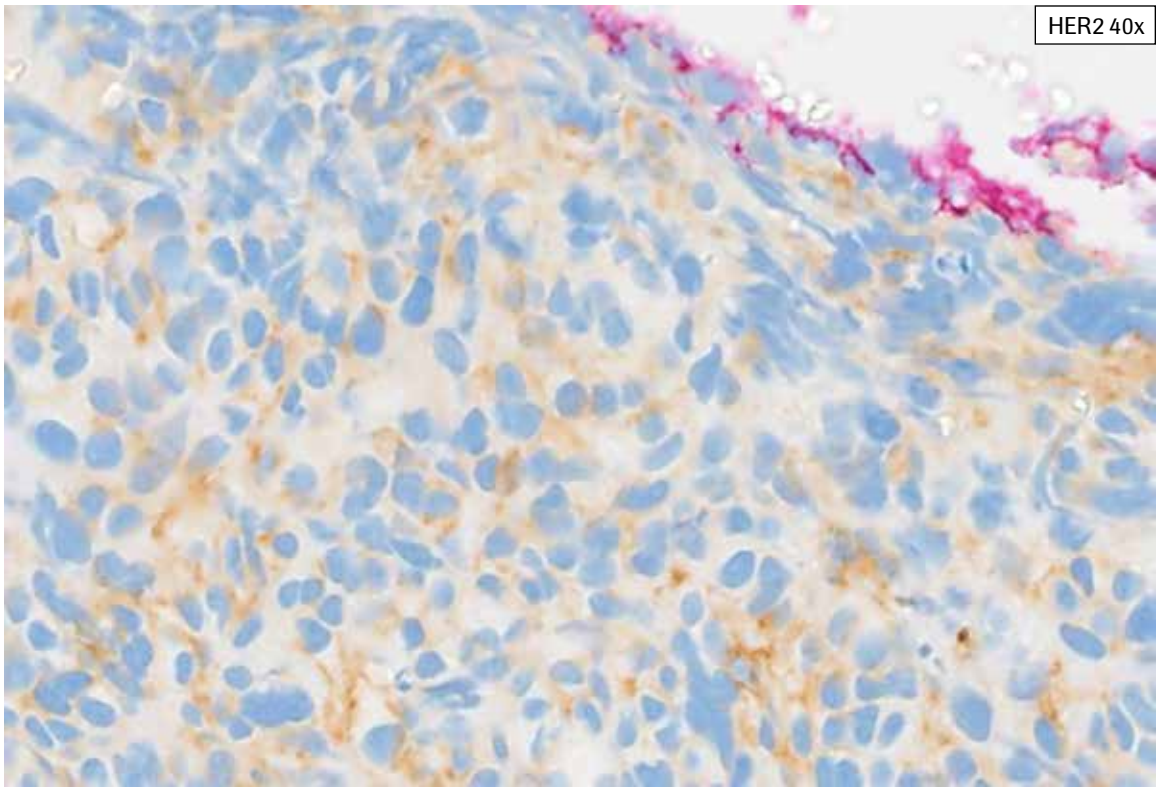
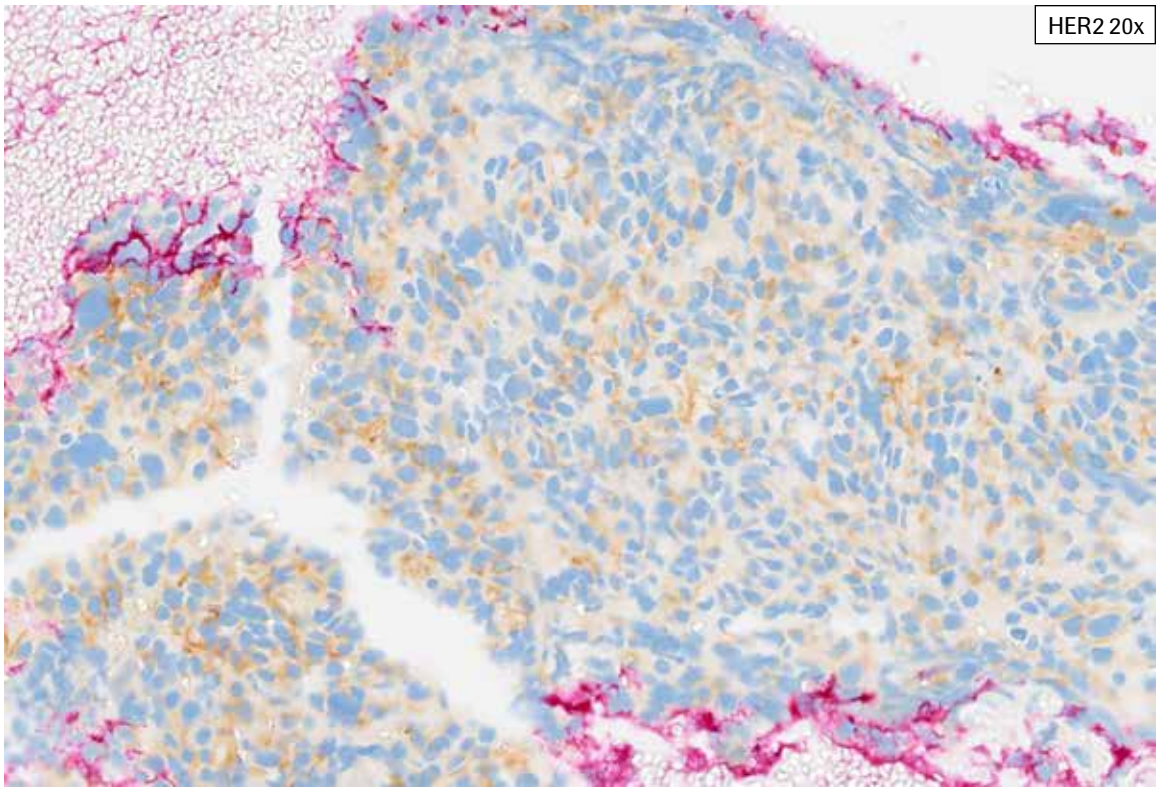
**Artifacts/Challenging Case 4:** This tissue exhibits abundant retraction artifact with HER2 staining of the retracted tissue edges. Any HER2 staining of tumor at retracted tissue edges, free tissue/tumor edges or open spaces (lumina or pseudolumina) is not included in HER2 scoring unless HER2 staining is also present extending along the lateral tumor cell membrane. This challenging case had an overall HER2 IHC Score of 2+, with 25% of viable tumor cells showing complete, weak to moderate membrane staining.



**Artifacts/Challenging Case 5:** This case presents more than a single challenge. Abundant HER2 DAB signal is seen along open spaces and within lumina, making the discernment of true faint to weak HER2 membrane staining difficult. Be aware that off target staining of apoptotic bodies, plasma cell cytoplasm and other cellular debris may be seen. While this case demonstrate both partial and complete membrane staining, the overall tissue was scored as HER2 IHC 2+ with 40% staining.

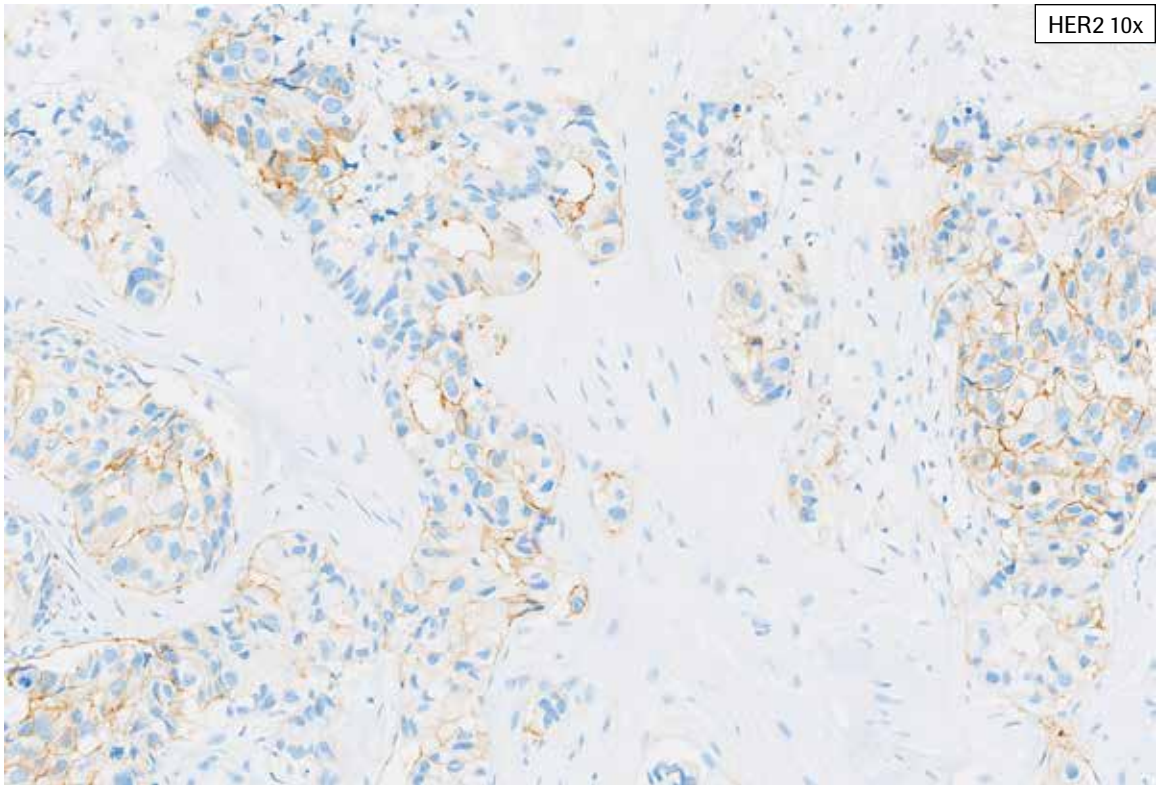
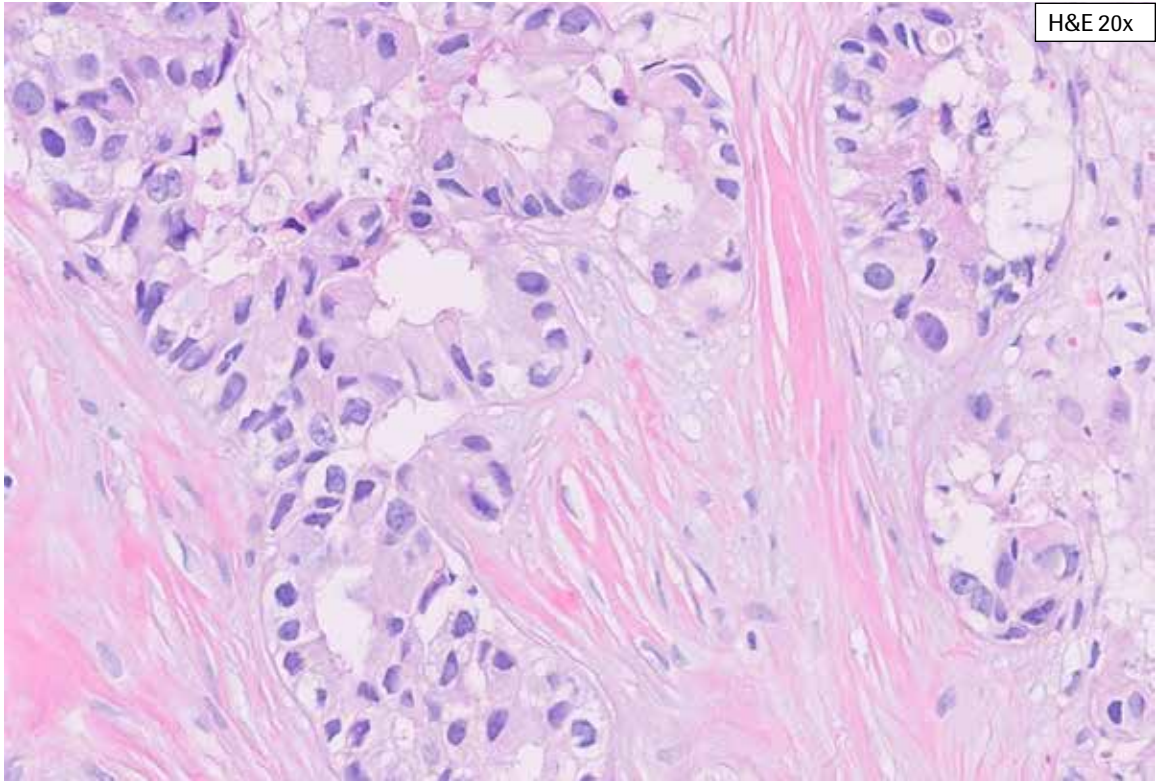


**Artifacts/Challenging Case 6:** The external surface of this biopsy case has been inked red. There are multiple, focal small areas of crush artifact. Tumor with crush artifact is not included as part of the viable tumor. Any membrane HER2 staining seen in tumor cells with crush artifact is excluded from HER2 scoring as these tumor cell membranes are damaged and may stain non-specifically. This tissue showed 40% partial staining overall (HER2 IHC Score 1+).

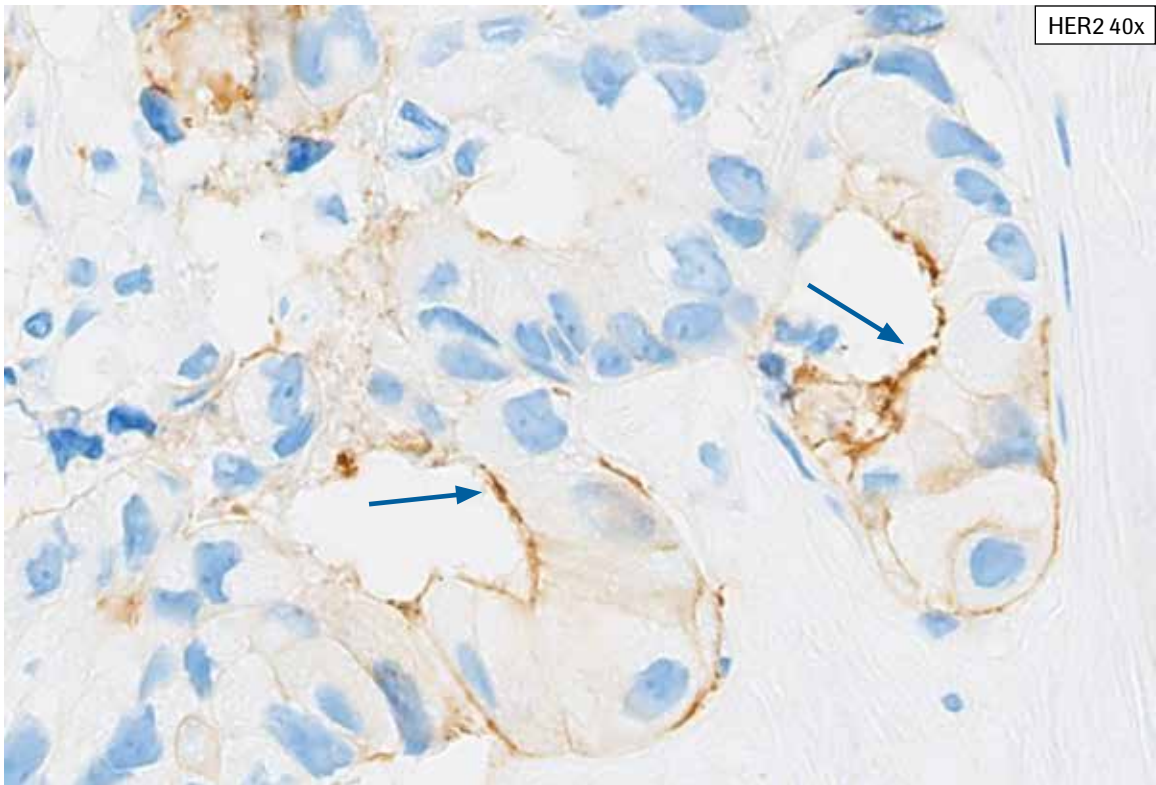
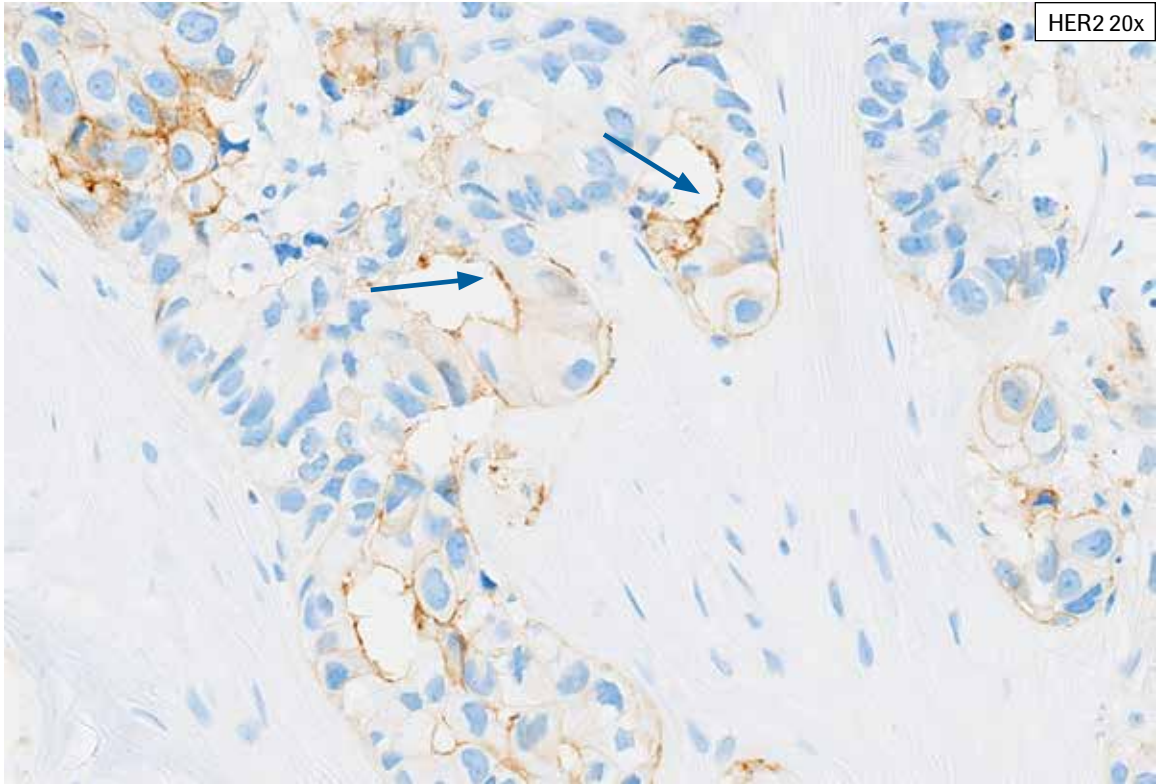


**Artifacts/Challenging Case 6:** The external surface of this biopsy case has been inked red. There are multiple, focal small areas of crush artifact. Tumor with crush artifact is not included as part of the viable tumor. Any membrane HER2 staining seen in tumor cells with crush artifact is excluded from HER2 scoring as these tumor cell membranes are damaged and may stain non-specifically. This tissue showed 40% partial staining overall (HER2 IHC Score 1+).

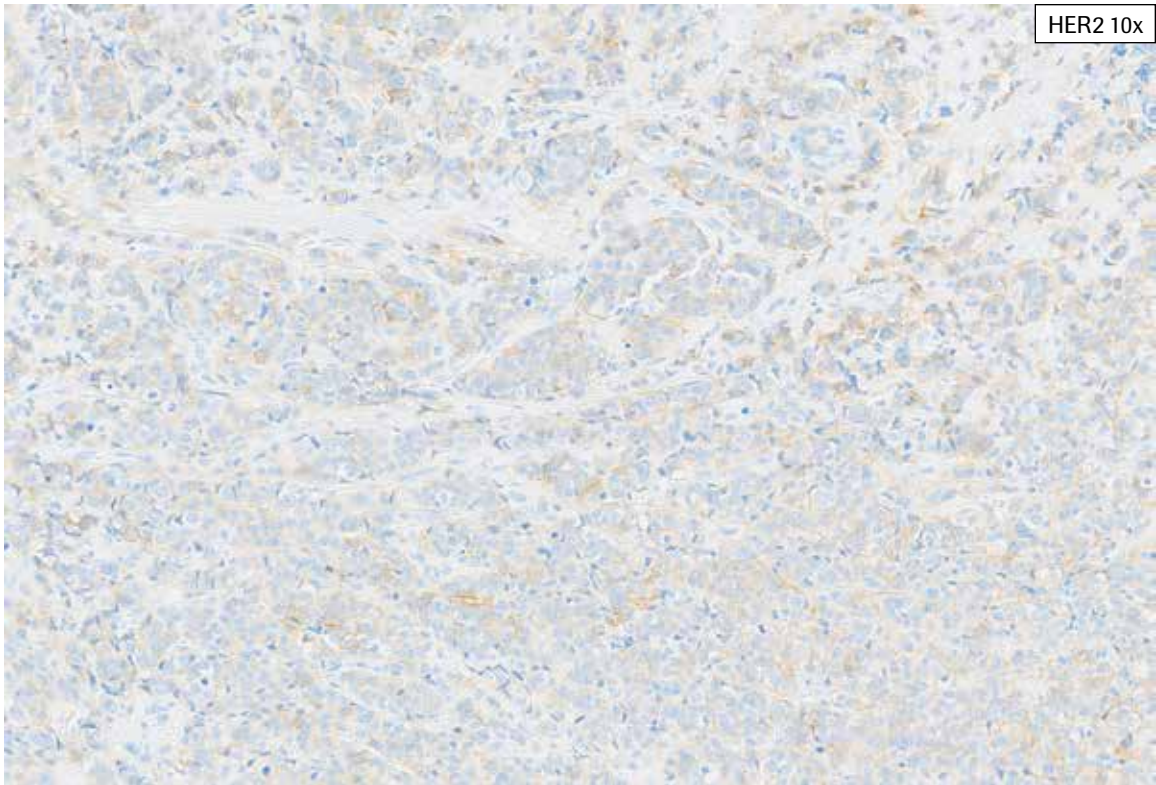
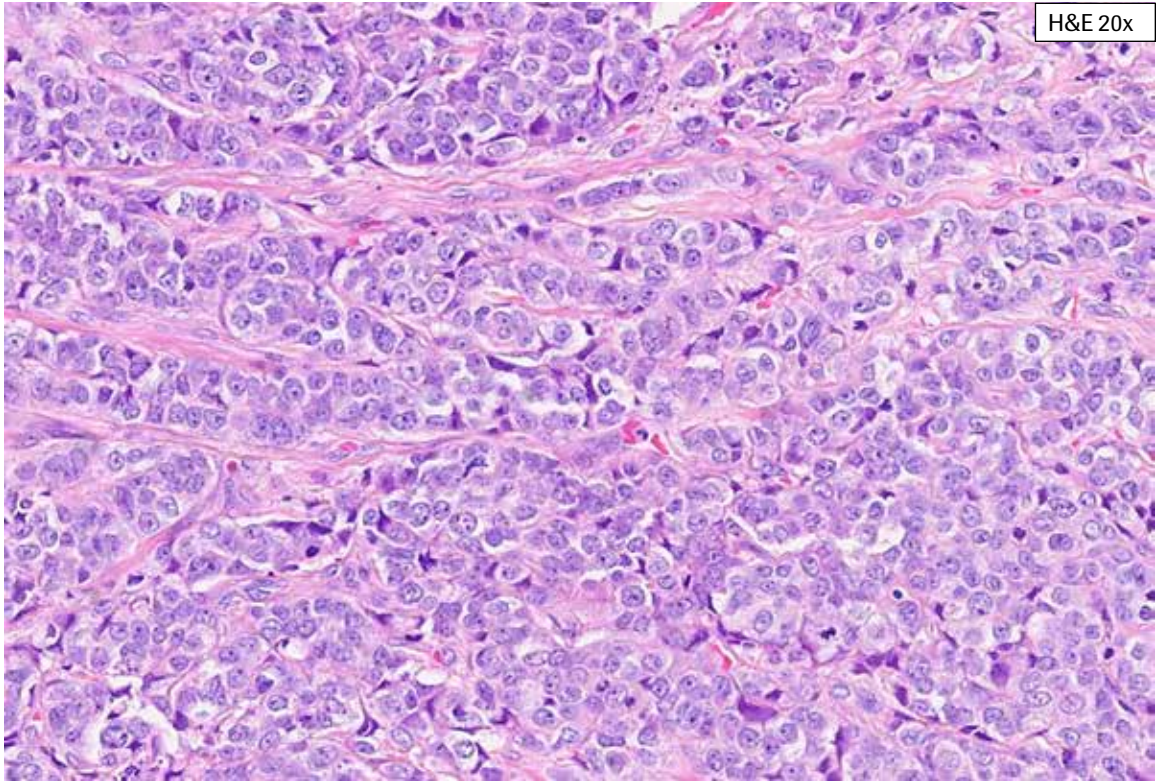




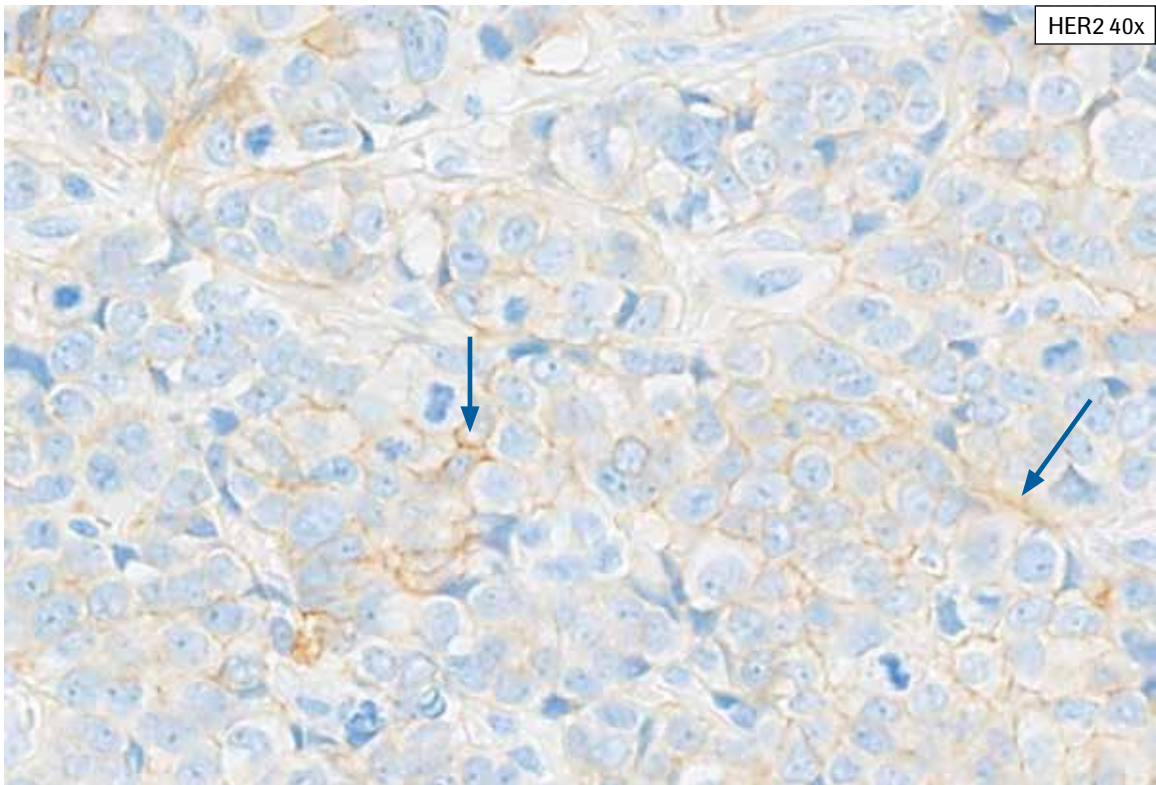
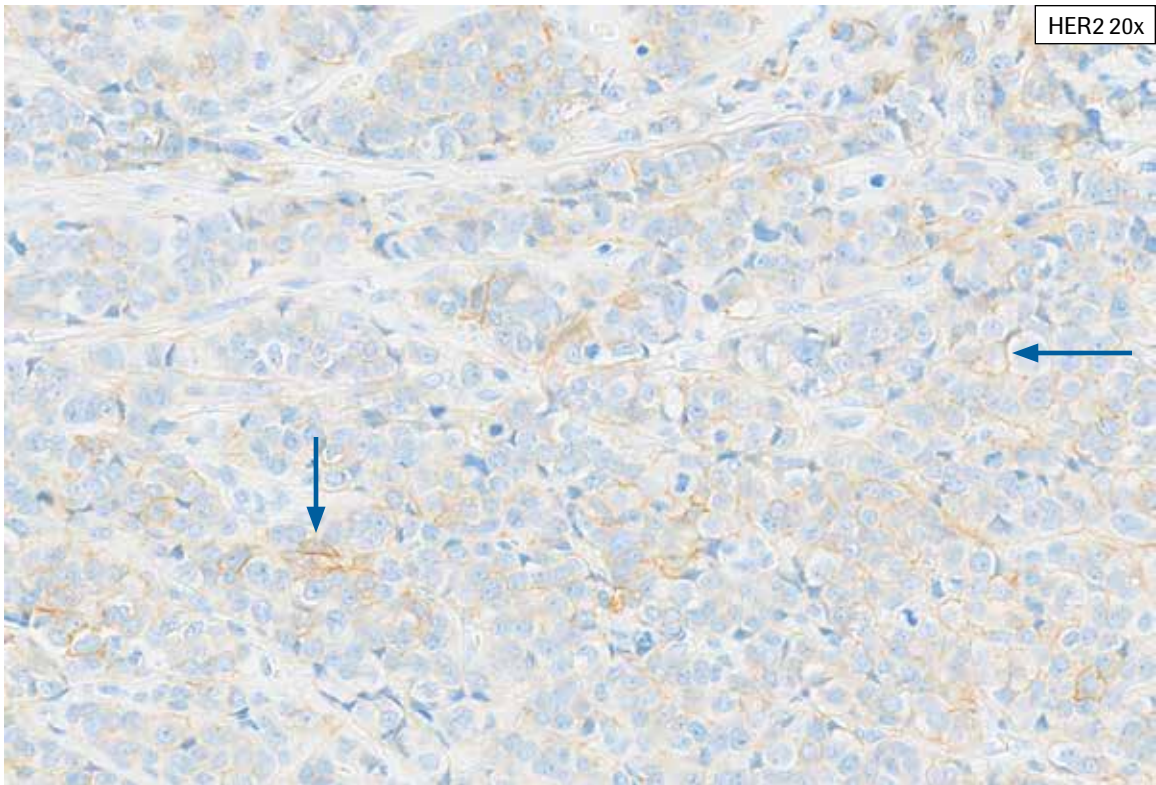
**Artifacts/Challenging Case 7:** This tissue shows abundant tumor with heterogeneity in HER2 staining. Retraction artifact is present. In addition, HER2 staining is seen along open spaces. HER2 staining of tumor cell membranes along open spaces (lumina or pseudolumina) is not included in HER2 scoring unless HER2 staining is also present extending along the lateral tumor cell membrane. This tissue was given an overall HER2 IHC Score of 1+ with 40% staining.



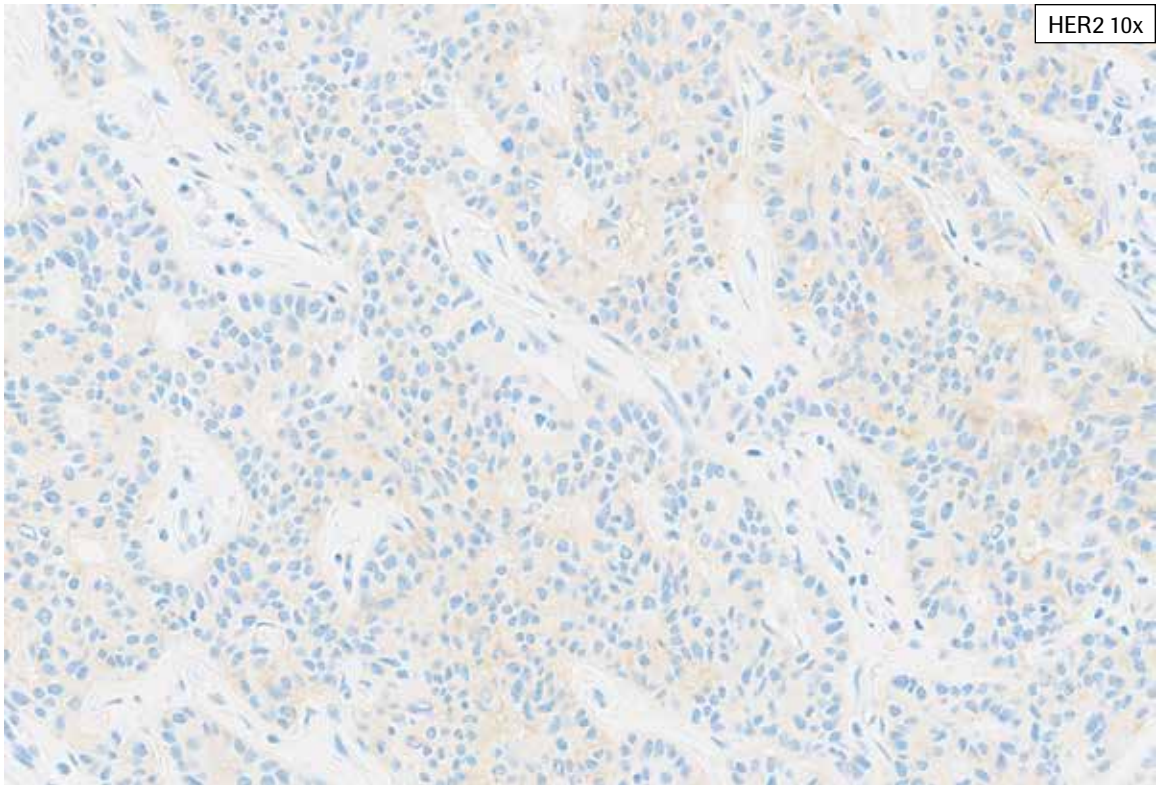
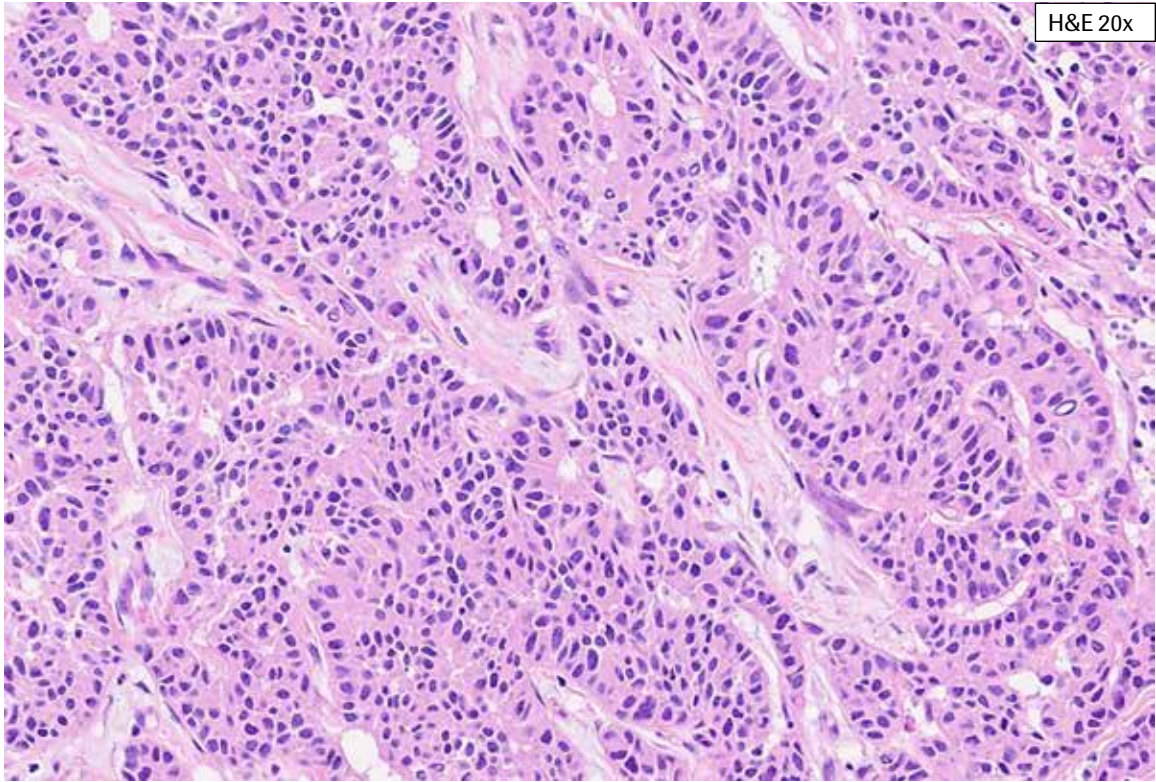
**Artifacts/Challenging Case 7:** This tissue shows abundant tumor with heterogeneity in HER2 staining. Retraction artifact is present. In addition, HER2 staining is seen along open spaces (arrows). HER2 staining of tumor cell membranes along open spaces (lumina or pseudolumina) is not included in HER2 scoring unless HER2 staining is also present extending along the lateral tumor cell membrane (arrowhead). This tissue was given an overall HER2 IHC Score of 1+ with 40% staining.



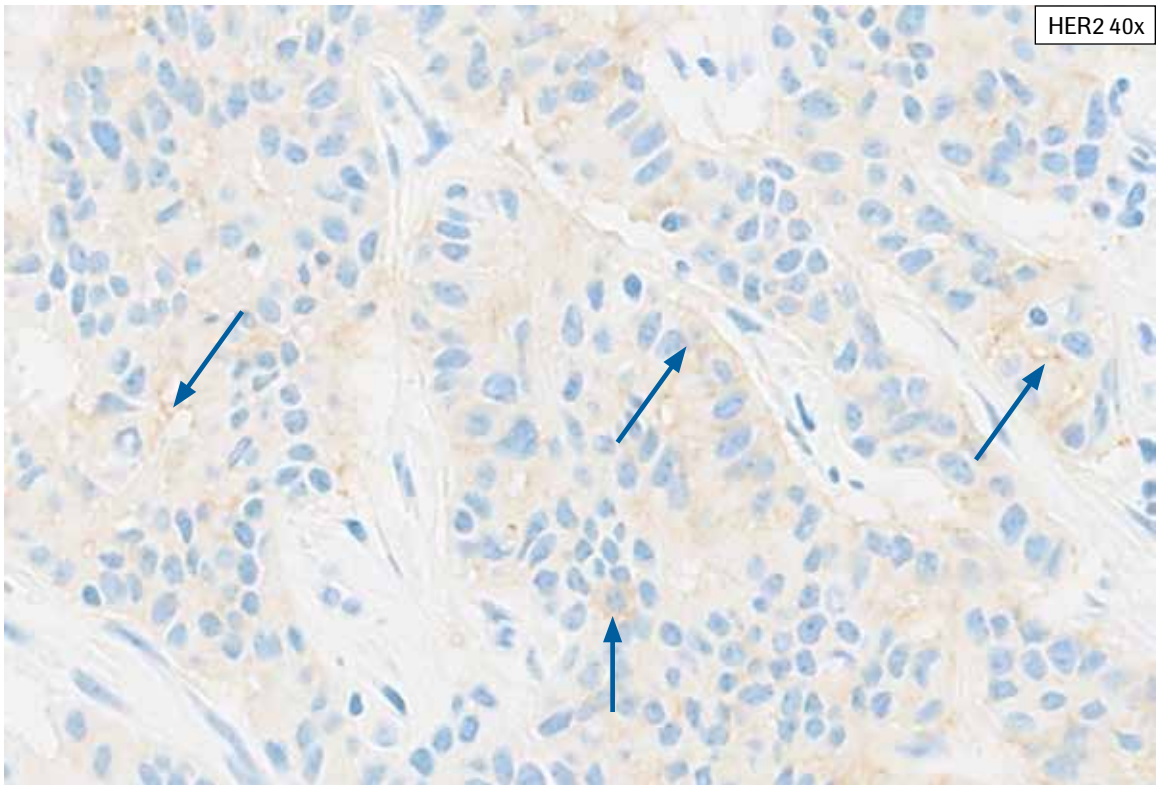
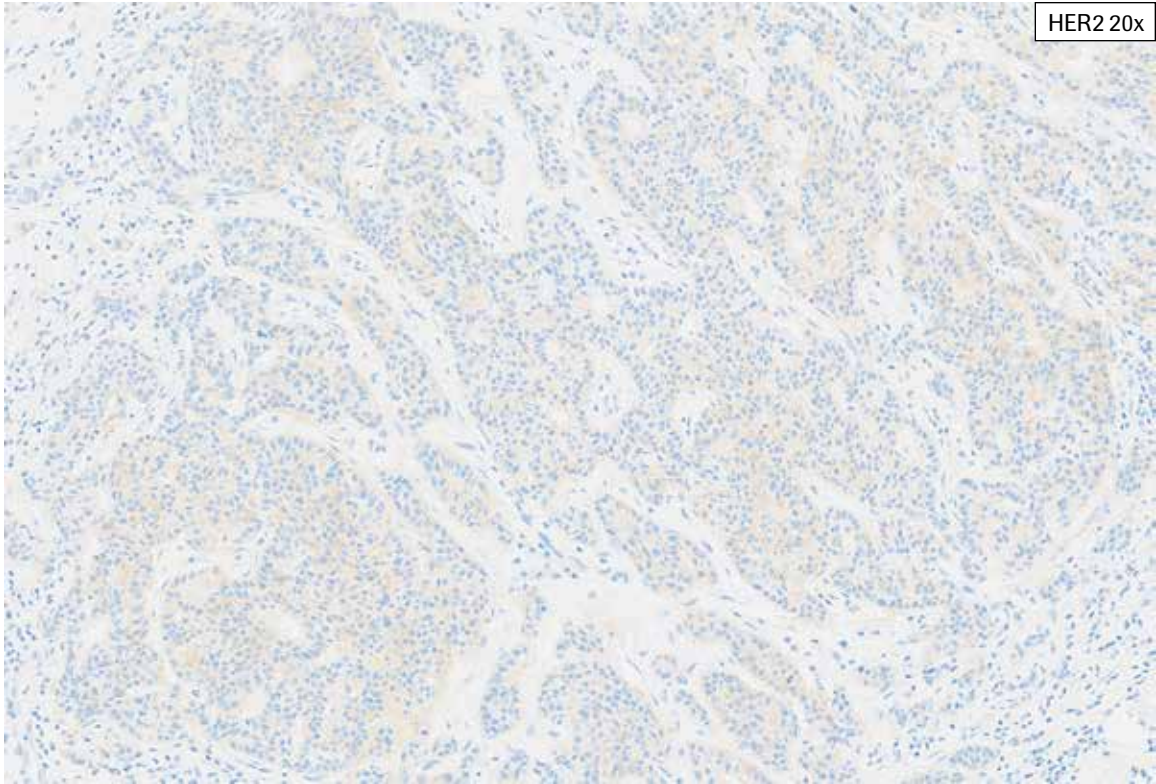
**Artifacts/Challenging Case 8:** This case shows abundant cytoplasmic bluish, making the discernment of faint to weak true HER2 membrane staining difficult. At progressively higher magnification, faint to weak membrane staining becomes apparent. If a case cannot be scored as a 2+ or 3+, time must be taken to carefully examine the entire viable tumor to assess all partial, faint to weak membrane staining. This case was scored as HER2 IHC 1+ with 30% partial staining.



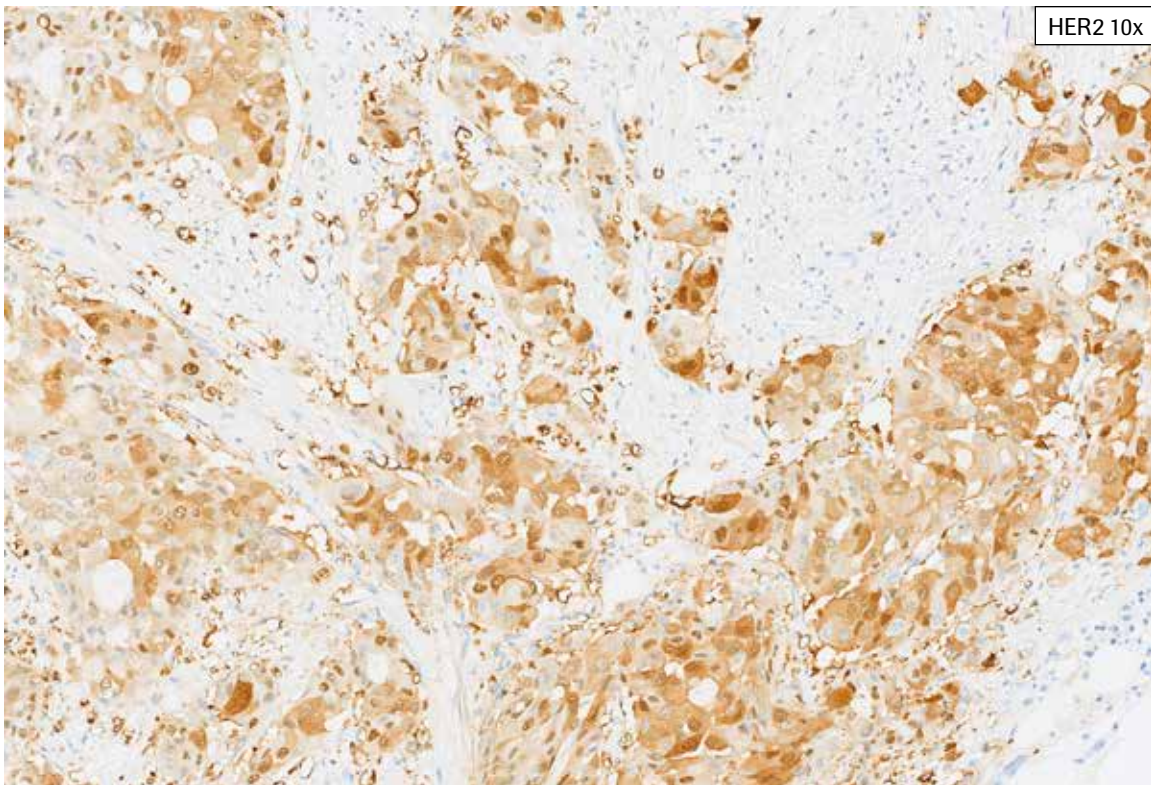
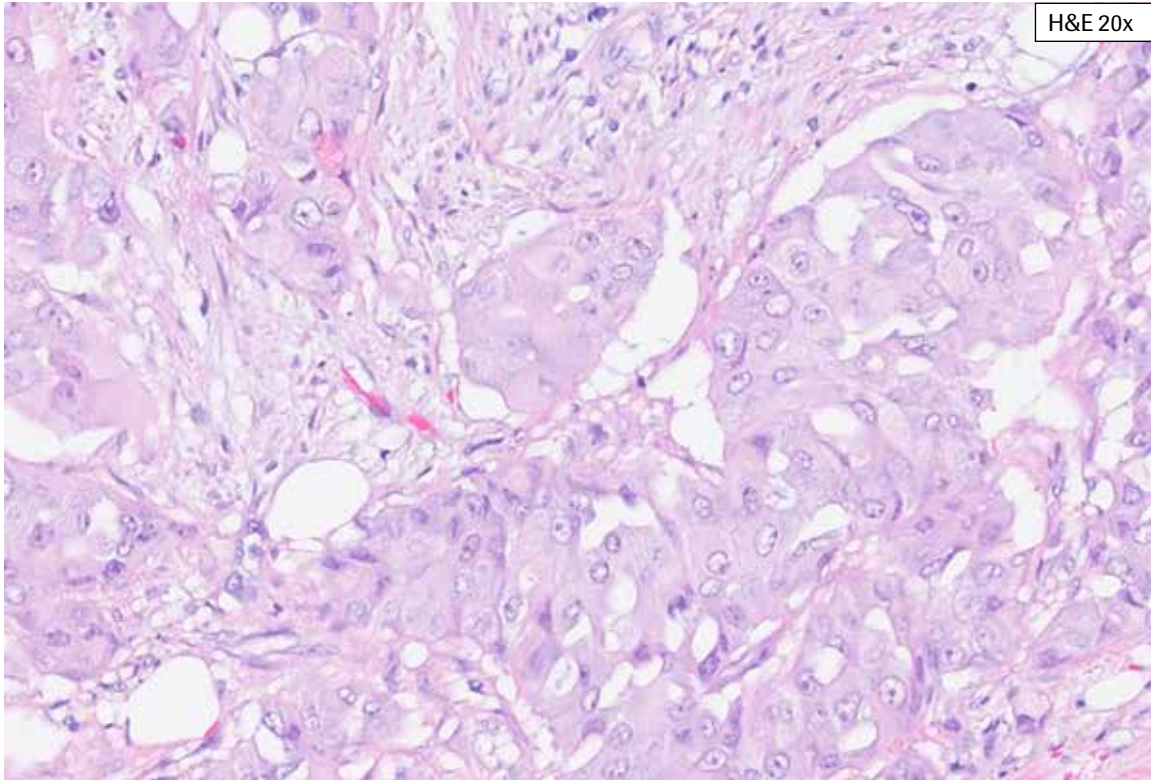
**Artifacts/Challenging Case 8:** This case shows abundant cytoplasmic bluish, making the discernment of faint to weak true HER2 membrane staining difficult. At progressively higher magnification, faint to weak membrane staining becomes apparent (arrows). If a case cannot be scored as a 2+ or 3+, time must be taken to carefully examine the entire viable tumor to assess all partial, faint to weak membrane staining. This case was scored as HER2 IHC 1+ with 30% partial staining.



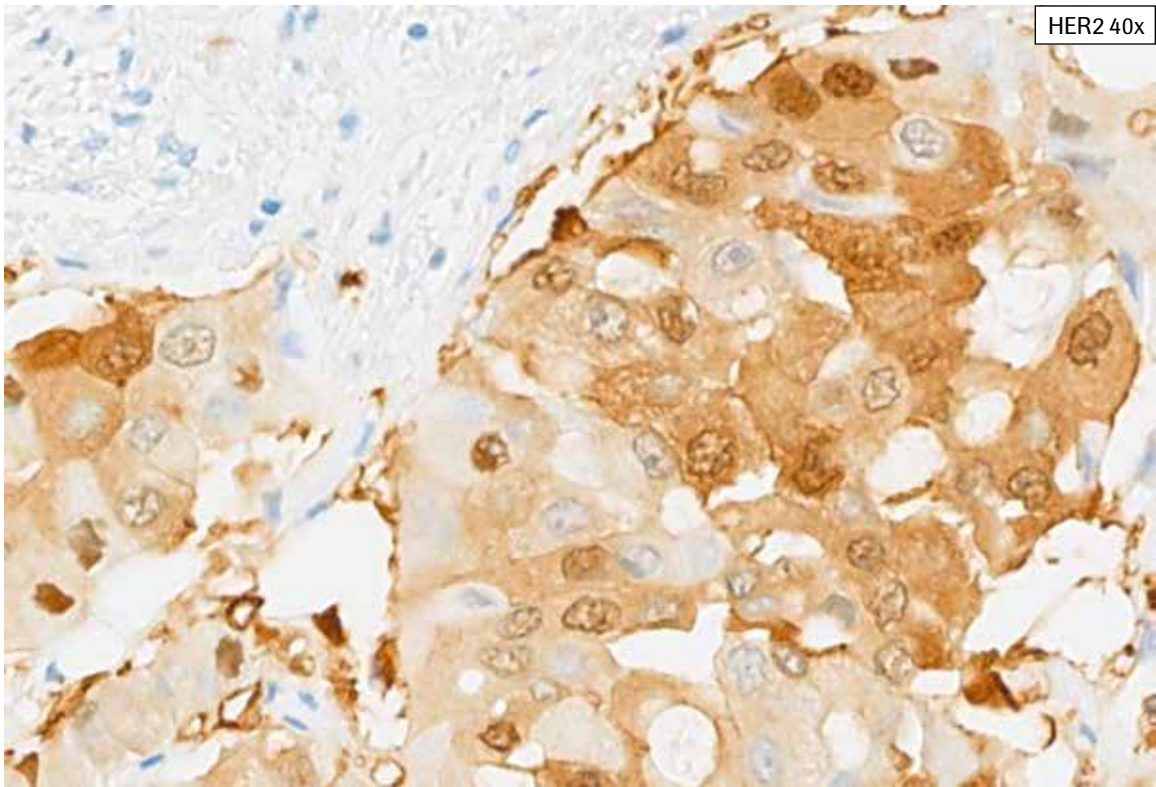
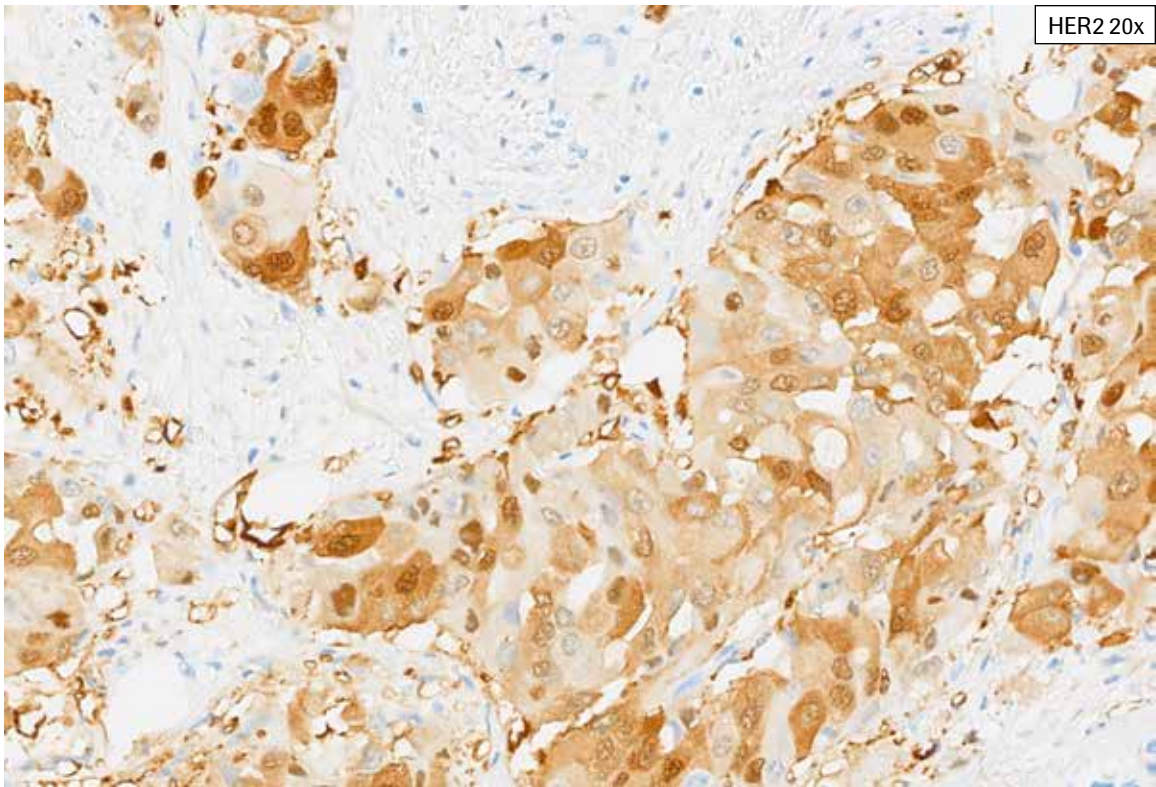
**Artifacts/Challenging Case 9:** This case is very challenging with abundant cytoplasmic bluish. Definitive HER2 membrane staining cannot be discerned at low to intermediate magnification. In a case like this, it is necessary to carefully examine the entire tissue at 40x to discern any partial, faint staining from cytoplasmic bluish. This case was given an overall tissue HER2 IHC Score of 0 with 8% staining.



**Artifacts/Challenging Case 9:** This case is very challenging with abundant cytoplasmic bluish. Definitive HER2 membrane staining cannot be discerned at low to intermediate magnification. In a case like this, it is necessary to carefully examine the entire tissue at 40x to discern any partial, faint staining from cytoplasmic bluish (arrows). This case was given an overall tissue HER2 IHC Score of 0 with 8% staining.

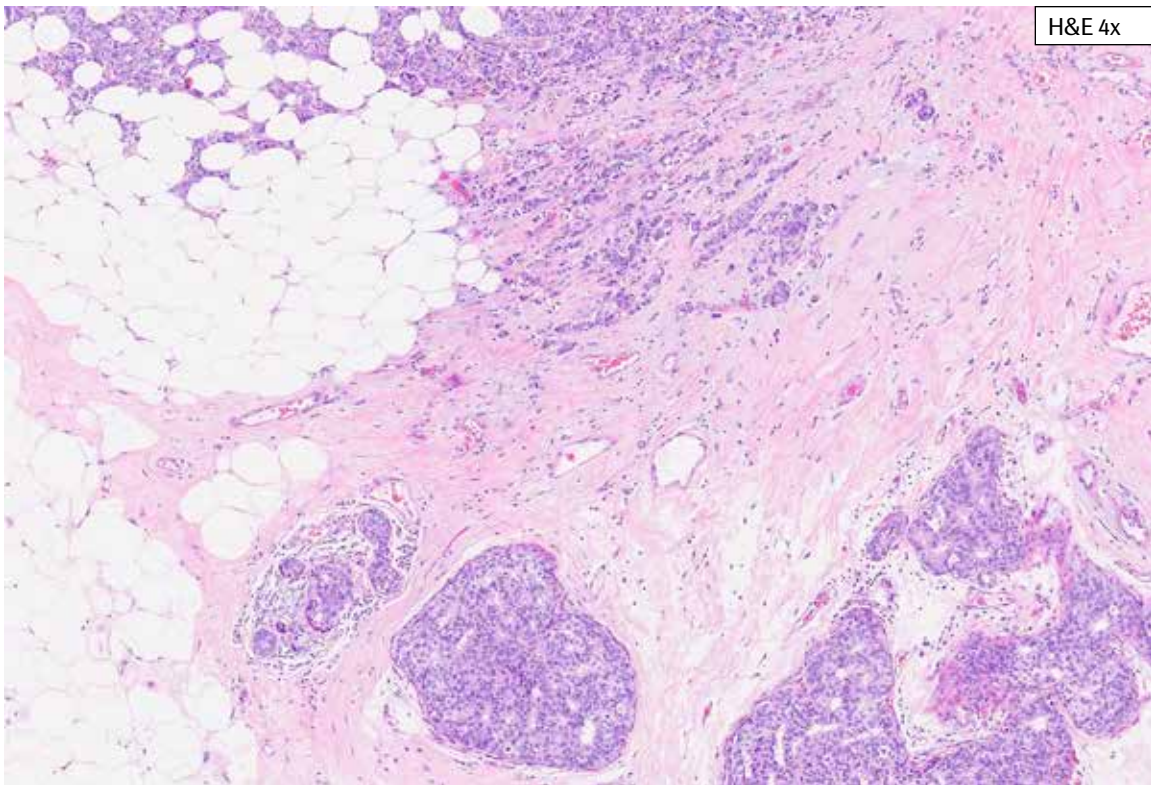
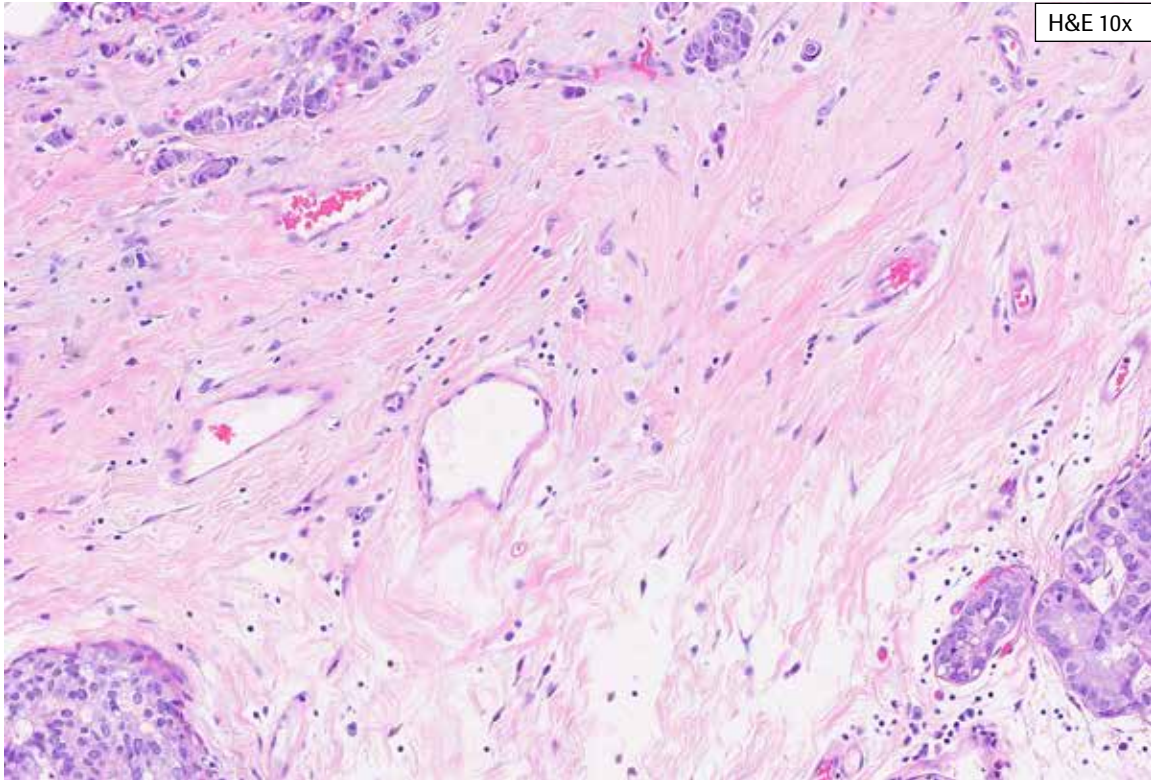


**Artifacts/Challenging Case 10:** This case shows tumor with marked cytoplasmic and nuclear HER2 staining. If the cytoplasmic and/or nuclear staining involves only a small focus of tumor or tissue, the remaining tumor may be scored. However, if a large portion of the viable tumor shows cytoplasmic and/or nuclear staining, the case should not be scored.

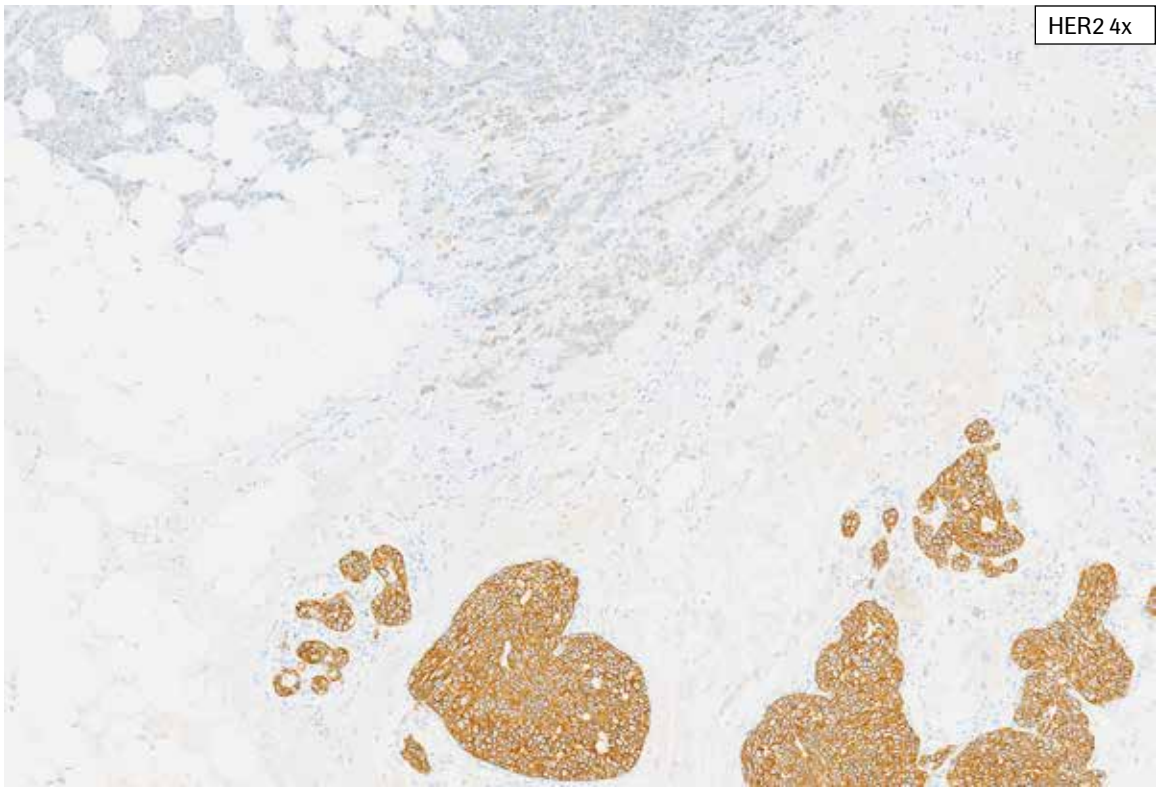
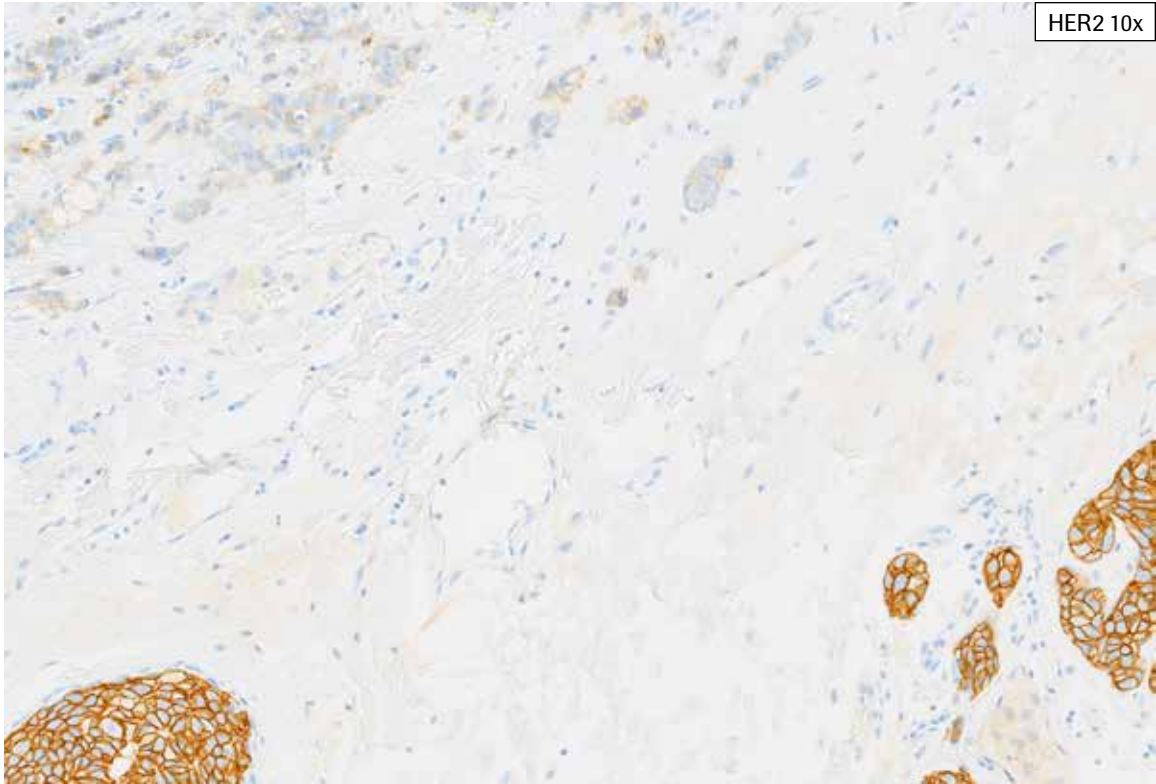


**Artifacts/Challenging Case 10:** This case shows tumor with marked cytoplasmic and nuclear HER2 staining. If the cytoplasmic and/or nuclear staining involves only a small focus of tumor or tissue, the remaining tumor may be scored. However, if a large portion of the viable tumor shows cytoplasmic and/or nuclear staining, the case should not be scored.





**Artifacts/Challenging Case 11:** In addition to invasive tumor, DCIS (ductal carcinoma *in situ*) is present in this tissue. The DCIS in this case shows complete, strong membrane staining while the invasive tumor shows partial, faint to weak staining. If DCIS is present in a tissue, it is excluded as viable tumor and excluded from HER2 scoring. DCIS may show HER2 staining that is similar to that seen in the invasive tumor, or completely different staining as that seen in the invasive tumor (as in this case).



**Artifacts/Challenging Case 11:** In addition to invasive tumor, DCIS (ductal carcinoma *in situ*) is present in this tissue. The DCIS in this case shows complete, strong membrane staining while the invasive tumor shows partial, faint to weak staining. If DCIS is present in a tissue, it is excluded as viable tumor and excluded from HER2 scoring. DCIS may show HER2 staining that is similar to that seen in the invasive tumor, or completely different staining as that seen in the invasive tumor (as in this case).

## Impact of Pre-analytical Conditions on PATHWAY anti-HER-2/*neu* (4B5) Antibody

---

### Acceptable Fixation Conditions for Optimal Staining Results

- Ventana requires fixation in 10% NBF for 6-72 hours.
- The amount of fixative used is 15 to 20 times the volume of tissue. No fixative will penetrate more than 2 to 3 mm of solid tissue or 5 mm of porous tissue in a 24-hour period. A 3 mm or smaller section of tissue should be fixed no less than 4 hours and no more than 8 hours. Fixation can be performed at room temperature (15-25°C).
- Fixed tissues should be embedded in new paraffin. Prolonged incubation in molten paraffin should be avoided, as high temperatures can degrade the epitope.
- Properly fixed and embedded tissues expressing the antigen will remain stable for at least 2 years if stored in a cool location (15-25°C).

### Tissue Thickness

Sections should be cut approximately 4-5  $\mu\text{m}$  thick and mounted on positively charged glass slides. Slides should be stained promptly, as antigenicity of cut tissue sections may diminish over time and may be compromised.

## References

---

1. Akiyama T, Sudo C, Ogawara H, et al. The product of the human c-erbB-2 gene: a 185-kilodalton glycoprotein with tyrosine kinase activity. *Science*. 1986;232(4758):1644-1646.
2. Press MF, Cordon-Cardo C, Slamon M. Expression of the HER2/neu proto-oncogene in normal human adult and fetal tissues. *Oncogene* 5; 953-962, 1990.
3. Taylor SL, Platt-Higgins A, Rudland PS, et al. Cytoplasmic staining of c-erbB-2 is not associated with the presence of detectable c-erbB-2 mRNA in breast cancer specimens. *Int J Cancer* 76: 459-463, 1998.

Ventana Medical Systems, Inc.  
1910 E. Innovation Park Drive  
Tucson, Arizona 85755  
USA  
+1 520 887 2155  
+1 800 227 2155 (USA)



© 2022 Ventana Medical Systems, Inc. and Roche Diagnostics International, Inc. All rights reserved.

VENTANA, BENCHMARK, CONFIRM, PATHWAY, *ultraView*, and the VENTANA logo are trademarks of Roche. All other trademarks are the property of their respective owners.

1449100 Rev L

2022-09-29

